

# THE UNITED STATES ARMY MEDICAL DEPARTMENT JOURNAL

## THE UNITED STATES ARMY DENTAL CORPS A CENTURY OF COMMITMENT, SERVICE, AND CARE

*January - March 2011*

<b>Perspectives</b>	1
MG David A. Rubenstein; COL Mustapha Debboun; Richard Burton	
<b>The US Army Dental Corps: 100 Years Old and Better Than Ever</b>	6
MG M. Ted Wong	
<b>Highlights in the History of Army Dentistry</b>	8
COL Samuel A. Passo; COL (Ret) John E. King	
<b>CAD/CAM Dentistry for Today's On-The-Go Military</b>	26
COL Jeffrey A. Hodd	
<b>Is the US Army Dental Corps Ready for the Digital Impression?</b>	38
COL Michael R. Craddock; COL Richard J. Windhorn	
<b>Ten-Month In Vitro Leakage Study of a Single-Cone Obturation System</b>	42
LTC A. John McKissock; COL Pete Mines; COL Mark B. Sweet; Col Steven L. Klyn, USAF	
<b>US Army Dental Command Information Management: Poised to Provide Quality Support for the Next 100 Years</b>	48
LTC Jeffrey S. Marks; MAJ Thomas E. Strohmeyer	
<b>Use of the Army Dental Command Corporate Dental Application as an Electronic Dental Record in the Iraq Theater of Operations</b>	51
COL Steven Eikenberg; MAJ Robert Keeler; SFC Thomas Green	
<b>Dental Readiness of Army Reserve Components: A Historical Review, Part Two</b>	58
COL Mark B. Bodenheim	
<b>The 2008 Army Recruit Oral Health Survey Results</b>	62
COL David L. Moss	
<b>The US Army Dental and Trauma Research Detachment: Now Part of the Army Institute of Surgical Research</b>	68
MAJ Davin E. Mellus; Jacqueline Amaya	
<b>Clinical and Electrodiagnostic Abnormalities of the Median Nerve in US Army Dental Assistants Before and After Training as Preventive Dental Specialists</b>	70
David G. Greathouse, PhD; et al	
<b>Palatal Fracture in a Child</b>	82
COL Karen M. Keith; CPT Tyler L. Clark	
<b>Pyogenic Granuloma Occurring in a Postmenopausal Woman on Hormone Replacement Therapy</b>	86
MAJ Thomas M. Johnson; et al	
<b>An Aggressive Benign Cementoblastoma</b>	91
COL (Ret) Richard E. Collins; Rafael Flores Asturias, MD	
<b>Dental Rehabilitation of a Patient with Dentinogenesis Imperfecta: A Clinical Report</b>	95
COL David A. Mott; COL Minaxi I. Patel; LTC Dong Soo Park	
<b>Solid Ameloblastoma, Resection to Reconstruction: A Case Report</b>	98
MAJ Michael J. Ryhn; COL Jeffrey S. Almony; COL Albert M. Manganaro	

THE UNITED STATES ARMY  
MEDICAL DEPARTMENT

A Professional Publication  
of the AMEDD Community

# JOURNAL

Online issues of the *AMEDD Journal* are available at <http://www.cs.amedd.army.mil/dasqaDocuments.aspx?type=1>

January – March 2011

The Army Medical Department Center & School

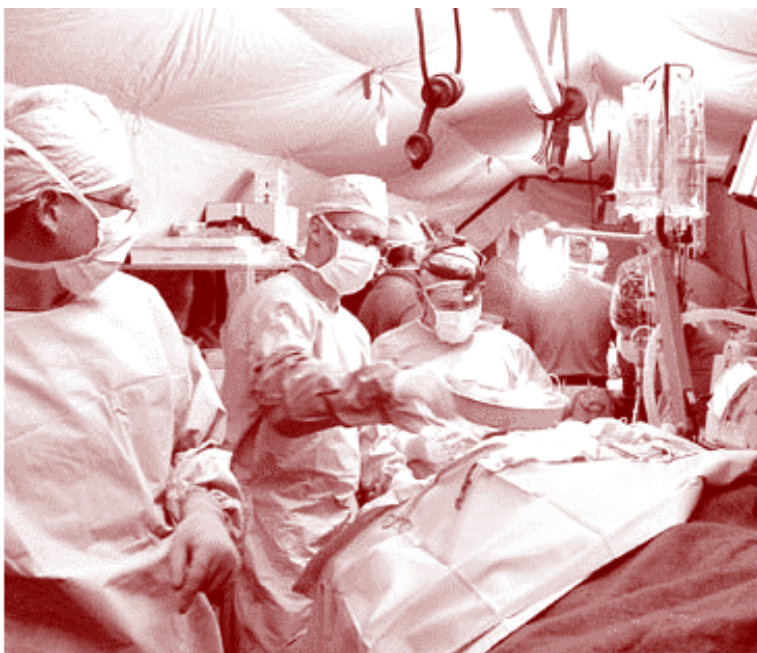PB 8-11-1/2/3

**LTG Eric B. Schoomaker**

*The Surgeon General  
Commander, US Army Medical Command*

**MG David A. Rubenstein**

*Commanding General  
US Army Medical Department Center and  
School*



*By Order of the Secretary of the Army:  
Official:*

*Joyce E. Morrow*

JOYCE E. MORROW  
*Administrative Assistant to the  
Secretary of the Army*

GEORGE W. CASEY, JR  
*General, United States Army  
Chief of Staff*

**DISTRIBUTION:** *Special*

1033603

*The Army Medical Department Journal* [ISSN 1524-0436] is published quarterly for The Surgeon General by the US Army Medical Department Center & School, ATTN MCCS-HT, 2419 Hood St STE C, Fort Sam Houston, TX 78234-7584.

Articles published in *The Army Medical Department Journal* are listed and indexed in MEDLINE, the National Library of Medicine's premier bibliographic database of life sciences and biomedical information. As such, the *Journal's* articles are readily accessible to researchers and scholars throughout the global scientific and academic communities.

**CORRESPONDENCE:** Manuscripts, photographs, official unit requests to receive copies, and unit address changes or deletions should be sent to the *Journal* at the above address. Telephone: (210) 221-6301, DSN 471-6301.

**DISCLAIMER:** The *AMEDD Journal* presents clinical and nonclinical professional information to expand knowledge of domestic & international military medical issues and technological advances; promote collaborative partnerships among Services,

components, Corps, and specialties; convey clinical and health service support information; and provide a peer-reviewed, high quality, print medium to encourage dialogue concerning healthcare initiatives.

Appearance or use of a commercial product name in an article published in the *AMEDD Journal* does not imply endorsement by the US Government.

Views expressed are those of the author(s) and do not necessarily reflect official US Army or US Army Medical Department positions, nor does the content change or supersede information in other Army Publications. The *AMEDD Journal* reserves the right to edit all material submitted for publication (see inside back cover).

**CONTENT:** Content of this publication is not copyright protected. Material may be reprinted if credit is given to the author(s).

**OFFICIAL DISTRIBUTION:** This publication is targeted to US Army Medical Department units and organizations, and other members of the medical community worldwide.

# Perspectives

## COMMANDER'S INTRODUCTION

MG David A. Rubenstein

This special issue of the AMEDD Journal celebrates an event that is truly significant, not only for the milestone itself, but also for what it represents for the Army Medical Department as an institution. On March 3, 1911, President Howard Taft signed legislation creating the United States Army Dental Corps as a permanent corps of the Army Medical Department, thus establishing the profession of dentistry as the third essential element, along with physicians and nurses, in maintaining a healthy, effective fighting force. Now, 100 years later, the Army Dental Corps has grown from a specified, limited niche in Army medicine to a corps of medical professionals, not only highly skilled in all aspects of oral healthcare, but also contributing as full partners in diverse responsibilities throughout the entire spectrum of today's Army Medical Department, including research, training, planning, and command. Army dental officers are also serving in a variety of assignments and positions across the Department of Defense, representing both their profession and Army medicine with pride and distinction.

I congratulate the Army Dental Corps for 100 years of devoted service to our Nation and am proud to have the opportunity to present this centennial tribute. This

issue of the AMEDD Journal was scheduled and created especially for this occasion, and I know you will find its contents both informative and truly impressive. It recognizes the splendid past of Army dental care, and provides examples of the current state of science practiced by today's Army Dental Corps. The breadth and scope of the capabilities of Army dental professionals, both past and present, are shown with clarity and detail. The reader will fully understand their indispensable role in accomplishing and maintaining the superior level of total healthcare provided to today's American Warrior, wherever he or she may serve.

I warmly welcome the Chief of the Army Dental Corps, MG Ted Wong, to this special publication. His opening article conveys the pride and dedication demonstrated daily by not only the men and women of the Dental Corps, but the other dental professionals working with them throughout the Army Dental Care System. I join MG Wong in calling for all military medical professionals to celebrate this milestone, not only for what it represents today, but also as the starting point for another century of continued growth and excellence dedicated to the overall health and well-being of our gallant Warfighters.

---

### EDITORS' PERSPECTIVE

As mentioned by MG Rubenstein above, this special issue of the *AMEDD Journal* opens with a commentary by MG Ted Wong, the Chief of the Army Dental Corps. He proudly introduces us to his Corps with an overview of the past and present, and insight to the broad range of skills and capabilities of the men and women dedicated to the dental health and readiness of today's Soldiers.

COL Samuel Passo and COL (Ret) John King have contributed an abridged, updated version of their Dental Corps pamphlet, *Highlights in the History of Army Dentistry*. This is an excellent, chronological collection of snapshots of the events and people involved in the evolution of dental services for military personnel. It is an informative, revealing look at not

only the advances in technology and education which drove the progress of dental science, but also how the influences of politics, economy, and social norms affected various aspects of the development of the dental care structure within the Army.

COL Jeffrey Hodd's article quickly brings us to the cutting edge of the practice of modern dentistry. He describes the adaptation of computer-aided design and computer-aided manufacturing technology into the process of tooth restoration. He focuses on the evolution and application of one of the currently available systems in use at some Army dental facilities. His clear, technically detailed article clearly describes the capabilities of the system and how it is used to create a finished restoration component, such as a crown, at the dental clinic during a single patient visit. This is in contrast to the normal process of the



use of a latex molding material to create an impression of the patient's teeth, from which a ceramic cast is created, which is then sent to a laboratory, usually geographically distant, where a crown or other restoration item is constructed and sent to the dental clinic. Of course, this process involves multiple steps, several days, and at least 2 patient visits over a period of time. The system described in COL Hodd's article eliminates all the interim steps. In the hands of a skilled dental staff, it generates a digital map of the teeth patient's, designs the crown for restoration, and constructs that crown, which the dentist then puts into place. The article contains 2 illustrated case studies which clearly demonstrate this advanced capability.

Another approach to the use of digital dental impressions is described by COL Michael Craddock and COL Richard Windhorn. In their article, they discuss another system which creates the digital map of the patient's teeth, which is then transmitted electronically to the Army Dental Laboratory at Fort Gordon, Georgia. Using that digital map, the Laboratory creates the cast model of the patient's teeth, and from that creates the restoration crown, which is sent to the dental clinic. As is the case described in the earlier article, this process eliminates all laboratory preparation work by the treating dentist, and markedly expedites the process of creating the restoration item, but a return visit by the patient is required for completion of the restoration. However, the tradeoff is a smaller, less expensive suite of equipment at the dental facility, which is an important factor for facilities in remote, undeveloped locations, or for units which may be called to deploy at any time.

One of the most critical considerations of the process of endodontic, or root canal, treatment is achieving a complete seal of the root canal space to prevent later bacterial contamination, and resulting infection. LTC John McKissock and his team conducted an extended (10-month) laboratory study of 2 common products used by endodontists to seal the canals to determine if either was superior in preventing leakage over time. This is an excellent example of a carefully designed and documented scientific study which established identical procedures and environment for each individual sample, included a representative control group, and followed precise, controlled evaluation methodology for the results. The article by LTC McKissock et al is yet another illustration of the extent of the knowledge, technical expertise, and initiative

that is characteristic of today's military dental professionals.

The benefits and uses of digital technology in healthcare seem to be limitless, not only in research and direct patient care, but also in areas of support, resulting in markedly enhanced productivity. LTC Jeffrey Marks and MAJ Thomas Strohmeier describe the evolution of one the most significant of such tools in military dental care, the Army Dental Command's Corporate Dental Application (CDA). Originally conceived and developed as a standard solution to replace an array of locally implemented scheduling and workload applications, the flexible, modular design of the CDA has allowed adaptation and growth into a tool that supports numerous functions at many levels of Army dental care. Their article is an excellent overview of a true success story—a "home grown" enterprise application developed, implemented, and maintained by the Dental Command's own Information Management and Technology Division. The CDA has been successfully extended far beyond its original concept, and continues to be adapted by innovative units to assist them in providing the best possible dental care, wherever they may be. One such significant initiative is the subject of the next article.

Accurate, current examination and treatment records are a necessity for all medical practitioners. The Department of Defense has pursued development of a standard electronic military medical record for a number of years, and a dental record module has been a part of that effort. However, to date no satisfactory, military-wide application has been fielded. Consequently, over time the Dental Command has increasingly turned to the existing CDA which, although not originally designed to capture treatment data, has been modified several times to accommodate such use. As described by COL Steven Eikenberg et al in their article, during 2 deployments to Iraq, the 502nd Dental Company Area Support developed methodologies and practical protocols to use the CDA as their electronic dental record in-theater, with excellent results. Their work led to further modification of the CDA to improve its utility, as well as the development of Army policies and guidelines to establish uniformity of the recorded data. This excellent article contains the impressive treatment encounter and diagnosis data collected by the 502nd during their latest deployment. The data clearly demonstrates the significant utility and value that this



adaptation represents, not only to healthcare in a deployed environment, but in potential garrison applications as well.

The extended combat operations since 2001 have involved extensive mobilization of Army Reserve and Army National Guard units. Similarly to previous major activations of Reserve Components, during the early years of these mobilizations, a large percentage of activated Soldiers were deemed not dentally ready for duty. COL Mark Bodenheimer addressed this situation in the January-March 2006 *AMEDD Journal*, where he described the aggressive actions taken by the US government to mitigate the problem. In this issue, he provides an update on the implementation of programs and electronic records and reporting systems which have dramatically improved the readiness of reporting Reserve Component Soldiers. His article is an eye-opening look at the extensive efforts that were involved in coordinating, synchronizing, and standardizing the dental reporting systems that existed across the 3 Army components. Also, he discusses steps taken to support dental care to Reserve Component Soldiers outside of alert and activation status, a critical element in reducing the extent of dental readiness problems upon mobilization. COL Bodenheimer's article provides valuable insight into the complexities and extent of coordinated work involved in contending with this serious aspect of national military readiness.

All military services face a situation similar to that described above with regard to their recruit training centers. Since new recruits are from the general population, their oral health conditions vary significantly, reflecting their pre-entry dental health care history which is dependent on financial factors, availability of care providers, and simple personal attention to oral hygiene. As with activated Reserve Soldiers, most new recruits require dental work to achieve operationally ready condition, and that work must be completed before the recruit reaches deployable status. Therefore, dental resources must be allocated to ensure those in the recruit pipeline receive the necessary care as they move through training. As part of the planning process, the Department of Defense periodically conducts a detailed survey of the oral health condition of arriving recruits. COL David Moss has provided the portion of that report presenting data on the Army's recruits in 2008. That data is compared to data from surveys in 1994 and 2000 to

illustrate trends (or the lack thereof) and spotlight the areas of dental care that commonly require the most attention. This article is informative and interesting, not only for its application to support of operational readiness, but also for its insight into oral health conditions among the demographic of the civilian population from which the military draws recruits.

For years the Army Dental and Trauma Research Detachment was located at Great Lakes, IL, where it performed its mission with great dedication and effectiveness, in spite of the seemingly relative isolation from other Army medical and dental resources. However, in the past year that situation has improved dramatically. In their informative article, MAJ Davin Mellus and Ms Jacqueline Amaya describe the recent relocation of the Detachment to the new Battlefield Health and Trauma (BHT) Research Institute on the grounds of the Brooke Army Medical Center in San Antonio. In conjunction with the relocation, the Detachment has also been aligned under the Army's Institute of Surgical Research (ISR), which is one of the keystones of the BHT Research Institute, along with Navy and Air Force research units. MAJ Mellus and Ms Amaya detail how the relocation and realignment represent a major milestone in both the mission and capabilities of the Detachment. The relocation into state-of-the-art facilities provides significant opportunities for extensive onsite collaboration among top notch researchers in related fields. The markedly improved availability of resources and the alignment with ISR has allowed the Detachment to redefine its mission into areas that until now were impractical, or in some cases impossible, for them to pursue. For many readers, this article may be an introduction to a vitally important component of Army healthcare. For others, it presents valuable information about the evolution of an invaluable resource for information and assistance in the areas of craniofacial trauma and infectious dental diseases.

In discussions of the practice of medicine, one often hears the question "who heals the healers?" In Army medicine, the answer is simple: we do! In this special issue of the *AMEDD Journal*, we are pleased to include an article detailing a research project directed specifically at the health and well-being of those in the oral health profession who provide patient care. Dr David Greathouse and his research team have contributed a report on their study evaluating upper-

extremity musculoskeletal disorders, including carpal tunnel syndrome, among experienced Army dental assistants as they underwent training to become preventive dental specialists. Their research sought to determine whether the 12 week intensive training course would instigate any physical problems, or exacerbate any such problems individuals may have had prior to entering the course. This study is one of several focused on dental caregivers which has been conducted within the Army-Baylor University Doctoral Program in Physical Therapy. The report is a very thorough, extensively researched and referenced, comprehensive presentation of the research team's study project, including detailed data of their results. Publication of this excellent report serves 2 important purposes; it highlights a potential area of concern for dental caregivers as they practice their specialties, and it demonstrates the level of professional expertise and capability within military medicine which is available to our personnel, including the best care for caregivers that can be provided.

This special tribute to the US Army Dental Corps closes with 5 clinical reports illustrating the broad range of skills and capabilities that is characteristic of Army dental professionals. Each of these articles presents a different facet of oral care, including fracture repair, total dental rehabilitation, and various types of tumor removals, all of which required significant reconstruction of bone structure and tooth replacement. These articles are but a few examples of the excellent work done every day by the dedicated members of the US Army Dental Corps and their associated dental support personnel in locations worldwide.

COL Karen Keith and CPT Tyler Clark present a somewhat unique case involving a penetrating wound to the roof of a child's mouth which included a palatal fracture and displacement of the bone up into the nasal vestibule. Their article carefully describes the unusual circumstances surrounding the injury and the method used to repair the damage. They also use the unique situation and characteristics of this injury to discuss the broader considerations that clinicians should understand when presented with an injury of this nature. Their detailed literature search produced a wealth of information about undiagnosed associated injuries, neurologic concerns, and the efficacy of various diagnostic techniques. All dental professionals should be familiar with the information presented in

this article because this type of injury is usually one of children, and therefore may not be seen by military clinicians very often.

MAJ Thomas Johnson and his coauthors describe a case that was diagnosed as a not uncommon benign tumor on the gingival tissue, but, on further examination, led to a more involved treatment protocol. In this interesting case, the tumor was associated with a dental implant which itself had been positioned incorrectly when inserted. Further, the tumor normally develops in women during puberty and pregnancy, but this female patient was postmenopausal and undergoing hormone replacement therapy. The treatment involved removal of the tumor, but also removal of the implant, and placement of a new implant requiring some restoration of bone tissue. The authors performed a literature search to investigate the possible relationship of the tumor to the hormone replacement therapy. Their findings indicate that no locatable research has been conducted on that relationship. This is a clearly presented, well-illustrated article that completely documents all aspects and considerations of this diagnosis and treatment. It should be of interest to all dental practitioners who encounter similar tumors among women in similar age and therapy circumstances.

The military healthcare professional rarely ceases to apply his or her skill, talents, and knowledge to contribute to the health and wellbeing of society after leaving active duty for the last time. Such is the case with retired COL Richard Collins, who teamed with Dr Rafael Flores Asturias to present a case they encountered at a volunteer dental clinic in Guatemala. They discovered and treated a rare tumor, called benign cementoblastoma. Their literature search revealed less than 100 reported cases of this particular type of tumor. Complicating the condition was a secondary, unusually rapid growing lesion. That rapid growth had been stimulated by a previous, fairly primitive treatment procedure. Correct treatment of this tumor ultimately involved significant surgical procedures, and resulted in removal of teeth, a nerve bundle, and portions of the jaw bone which required reconstruction. This article contributes a superbly presented, clearly documented and illustrated case study to the body of literature concerning this fairly rare condition. The careful diagnosis and extensive treatment performed under less than ideal clinical

circumstances is yet another testament to the skill, knowledge, and, above all, dedication of the dental and medical professionals that wear the uniforms of the US military.

Almost everyone knows someone who, for whatever reason, has lost all of their teeth as they aged, usually from a lifetime of neglect of their oral hygiene and dental care. However, we would consider it to be unusual (outside of trauma) for a young person, especially a teenager, to have an advanced dental condition that endangered virtually all of their teeth. COL David Mott, LTC(P) Minaxi Patel, and LTC Dong Soo Park have contributed a clinical report documenting such a situation. They describe a 19-year-old Soldier's presentation with a condition known as dentinogenesis imperfecta, a genetic disorder that affects the majority of the teeth, which, without treatment, ultimately results in serious deterioration and tooth loss. In the case of advanced deterioration such as they encountered here, the only effective treatment is total rehabilitation, which is a multidiscipline endeavor involving prosthodontics, periodontics, and dental implant surgeries. The article is an excellent case study of careful research, thorough planning, close coordination, and a complex course of treatment over a period of time, during which 8 teeth were extracted, 7 implants were placed, and 16 teeth received crowns. The treatment not only resolved the complaints of oral

pain and sensitivity, but also tenderness in the muscles of the jaw and the aesthetics of the appearance of the teeth. As depicted in the article's imagery, the process and results were indeed impressive, yet another example of the exceptional level of oral healthcare our Army Dental Corps professionals provide to Soldiers every day, wherever they may be.

This special issue of the AMEDD Journal closes with an excellent, clearly presented clinical report describing treatment of another type of oral tumor, an ameloblastoma. In their article, MAJ Michael Ryhn, COL Jeffrey Almony, and COL Albert Manganaro detail the potentially serious nature of this aggressive form of tumor, and present the concerns and complications of the corrective surgical procedures. As with some of the other procedures described in this issue, portions of the patient's jaw bone were removed, bone grafts inserted, and reconstruction with dental implants was performed to replace the lost teeth. This article portrays another team of skilled, dedicated military dental professionals who collaborate to create a total treatment plan, and then work over an extended period of time to restore the patient to full function and health. This informative article is well researched and illustrated, and provides further insight to the extent of the talents, skill, knowledge, and capabilities that are hallmarks of the members of the United States Army Dental Corps.



THE UNITED STATES ARMY  
MEDICAL DEPARTMENT



THE UNITED STATES ARMY  
MEDICAL DEPARTMENT  
CENTER AND SCHOOL





# The US Army Dental Corps: 100 Years Old and Better Than Ever

MG M. Ted Wong, DC, USA

---

MG Wong is Commanding General, William Beaumont Army Medical Center, Fort Bliss, Texas, and Deputy Commanding General for Readiness, Western Regional Medical Command, Fort Sam Houston, Texas. He is also the Chief of the US Army Dental Corps.

---

As the 26th Chief, US Army Dental Corps, I am excited to be a part of this Dental Corps Centennial issue of the *Army Medical Department Journal*. On March 3, 2011, the US Army Dental Corps will celebrate its 100th anniversary. This historic event marks a 100-year milestone for the Army Dental Care System (ADCS), and for all of Army medicine. I invite you to enjoy this special issue of the *AMEDD Journal*, dedicated as a centennial tribute to the Dental Corps and the men and women of the ADCS. In these pages you will learn more of the history of our proud Corps and become familiar with its founders and many of the key individuals and events from the past. Today, the ADCS enjoys the fruits of remarkable efforts and perseverance by the Corps' founders, members of American dental professional associations, and all our past Corps' leaders and members, whose collective accomplishments leave an outstanding legacy of selfless service, gallant leadership, and an unflagging organizational esprit de corps. The leaders and members of the ADCS of today are poised to leverage this winning legacy into our next 100 years of service.

In addition to the historical perspectives, you will discover among the articles in this issue the high levels of diverse skills and professional competencies that are involved in providing the superb dental healthcare that is the norm for modern Army dentistry. The subjects range from interesting case studies of procedures addressing some relatively uncommon conditions, to the application of the most current technologies in support of our delivery of dental care. There is also an article examining disorders of the muscles, tendons, and nerves in wrists and hands of Army dental assistants and specialists, another example of Army medicine's dedication to "heal the healers."

First, however, this issue is a celebration of our history. We note that from 1775 to 1901, at the

beginning of efforts to provide service to Soldiers, such care was provided by hospital stewards (enlisted medics), who, by their own special interest or training, chose to limit their medical activities to providing dental care with medical officers. In 1901, the Army authorized 30 contract dentists for an Army-wide program of dental care. Ten years later, these contract positions were converted to commissioned officer positions. Through the vision of, and persistent attempts by, civilian and Army dentists at the turn of the 20th century, Congress officially established the Army Dental Corps on March 3, 1911. Our 100 years of official existence is replete with inspiring examples and stories of men and women of the Army Dental Corps demonstrating dedicated service, valor, and commitment to taking care of Soldiers in all sorts of environments and all types of operations, across all theaters of operation.

We are currently in our 10th year of continuous support for overseas contingency operations, and the Army's operational tempo has been tremendous and unrelenting, demanding our unwavering attention to the dental healthcare services we provide to our Warriors. Our focus remains supporting a Nation and Army at war, ensuring the dental readiness of our deploying forces by providing high quality dental care that is a hallmark of the ADCS. Through the actions and accomplishments of Army dental personnel everywhere, we continue to demonstrate that dental healthcare is a vital component of overall Soldier health and Army readiness, and the ADCS is a key member of the Army Medical Department healthcare team.

The ADCS is an amalgamation of Active Component, Army National Guard, and Army Reserve personnel—officers and enlisted Soldiers, Department of the Army civilians, and contract service providers. Today, our

workforce consists of over 1,350 dentists (Active Duty, Reserve, Army National Guard, civilian government employees, and contractors), over 3,350 noncommissioned officers and enlisted Soldiers from all components, and over 3,000 civilian and contract service providers. We are a diverse organization of highly skilled professionals, all of whom serve America's Warriors in dental treatment facilities, in command and staff positions, and in deployed operations. The majority of our personnel assets are in the generating force organization, the Army Dental Command. In a typical day, the Dental Command sees about 9,000 patients, taking almost 5,000 radiographs, and producing nearly 27,000 dental procedures valued at close to \$3,000,000.

Army Dental Corps members are not limited to providing clinical care. They are a group of multitasked, well trained, and highly skilled leaders and healthcare professionals who function in a variety of positions and assignments across the Army and the Department of Defense. Dental officers of all specialties serve as mentors in our postgraduate dental education residency programs, which produce a wide variety of proficient specialists. Dental officers in the Army Medical Department Personnel (AMEDD) Proponent Directorate ensure the Army maintains the correct dental force structure. The staff in the AMEDD Center and School, Department of Dental Science provides professional leadership training for officers and noncommissioned officers, basic and advanced dental training for enlisted Soldiers, and business

management training. The US Army Dental and Trauma Research Detachment, newly relocated to Fort Sam Houston and aligned with the Army Institute of Surgical Research, enhances the recovery from wounds through cutting-edge, bioengineering research. New combat equipment emanates from the AMEDD Directorate of Combat and Doctrine Development to ensure that our materials and equipment provide only optimum support to Soldiers, whenever and wherever they are called to deploy. The staff at the Army Human Resources Command manages the worldwide distribution and assignment of dental personnel.

It is a distinct honor and privilege to be a member of and represent the premier dental healthcare organization in the world, where I serve with the finest healthcare professionals imaginable. Throughout my visits and interagency contacts, I hear from our patients and other Army leaders about the outstanding healthcare and readiness support we provide to Soldiers. It is a tribute to the committed dedication and selfless service to patients, and the continual personal commitment to the mission by the men and women of the Army Dental Corps and the ADCS. I am completely confident that the Army Dental Corps is fully prepared to provide another century of exemplary and compassionate dental healthcare services to our Warriors, in garrison or deployed anywhere in the world. Wherever you may be on March 3, 2011, please join me and all Army dental healthcare professionals in our celebration of the Army Dental Corps' 100th Anniversary!



THE UNITED STATES ARMY  
DENTAL CORPS

# Highlights in the History of Army Dentistry

COL Samuel A. Passo, DC, USA  
COL (Ret) John E. King, DC, USA

## INTRODUCTION

Experience is valuable to improving performance in every field. Many personal experiences do not offer themselves at a time or place which is safe, convenient, or accessible. History serves as the community record of experience, and within the military community it is valued as one of the instruments of situational analysis. A problem exists for the unique profession of military dentistry in that published records of military dental history are very few, and dentists frequently focus on dentistry's vast and growing scientific information pool, often to the neglect of military history. As this is written in 2011, there are only 3 books presenting aspects of the history of Army dentistry. One is limited to the period of World War II.<sup>1</sup> Another concerns dental care at the US Military Academy at West Point.<sup>2</sup> The most comprehensive and detailed history was only recently published and covered the period from the Revolutionary War until 1941.<sup>3</sup> Realizing the need and importance to capture more of the Army dental care experience, starting in 1974 staff members in the Office of the Chief of the US Army Dental Corps produced a pamphlet which chronicles major and significant events in the oral health care of Army beneficiaries. The name of this useful pamphlet is *Highlights in the History of Army Dentistry*.<sup>4</sup> Technology has presented the option to make it available on the internet rather than published in hard copy, a convenient and practical medium for an historical publication which is constantly evolving.

On the auspicious occasion of celebrating 100 years since the establishment of the US Army Dental Corps in 1911,

MG Ted Wong, current Chief of the US Army Dental Corps, has requested a historical update of *Highlights*. Another part of the celebration is a special Dental Corps centennial edition of the *AMEDD Journal*, and it was proposed that the 2011 update of *Highlights* be included in this issue of the *AMEDD Journal*. However, since the *Highlights* has, over the last 37 years, increased in content and length, inclusion of it in toto is not possible. Consequently, the following highlights were extracted and abridged to reduce the length. However, a complete, unabridged version of the updated *Highlights in the History of Army Dentistry* will be available (and maintained) on the internet.<sup>4</sup>

*Highlights* is best described as a chronology written to give succinct information about significant events that have changed Army dentistry. *Highlights* is absolutely not a definitive history. *Highlights in the History of Army Dentistry* is organized chronologically which provides valuable perspective as to how some events lead to others, how events and people are related in time. There are more lessons to learn if the reader discovers a topic of interest and looks for entries related to it. For example, a theme of developing the education and training schools unique to Army dentistry can be traced by linking entries for the dates March 1916, September 1916, November 15, 1917, March 15 1918, May 1921, January 6, 1922, and July 1, 1939, among others. By becoming familiar with *Highlights*, the user can find many such themes such as changes in administrative organization, dental lab support, research units, dental support to the major wars and conflicts, etc. Help with *Highlights* and other dental history issues is available from the Dental Corps Consultant for Dental History.

---

## HIGHLIGHTS

### REVOLUTIONARY WAR (1776 – 1781)

The Continental Army was established on 14 June 1775 without any idea of providing dental support to troops. The practice and later policy that soldiers were responsible for their own dental care continued until 1901, although there were several notable exceptions.

1776 – Paul Revere performed the first recorded case of military forensic identification on the remains of MG Joseph Warren at Bunker Hill about 10 months after Warren's death in that famous battle.

### THE EARLY REPUBLIC

During the War of 1812 with England, the Mexican War (1846 - 1848) and the westward settlement of America, Soldiers sought needed care from civilian dentists or itinerant tooth drawers. In remote locations where no civilian dental source was available Army physicians and hospital stewards (some with preceptor-type training in dentistry) were the only sources of emergency dental care. Accounts of the time indicate most physicians and stewards were ill-prepared to provide this service.



6 March 1840 – The Baltimore College of Dental Surgery was established as the first dental school. Although this was primarily a civilian event, it signaled the advancement that dentistry had achieved in technology, science, education, and professional organization. These advances legitimized the argument by many civilian dentists of the early 1800s that the US military should recognize dentistry as a specialized medical requirement. As dentistry began to promote itself as a profession many dentists also brought attention to government leaders that Soldiers and sailors suffered from lack of access to qualified dental care.

31 July 1860 – The American Dental Association (ADA) held its first convention in Washington DC. It adopted a resolution to support the appointment of dental officers for the Army and Navy. Organized dentistry continued to press the Army and Congress for military dentistry throughout the American Civil War. Note: The Southern Dental Association separated from the ADA with the division of the nation into the northern Union and southern Confederacy. Dental organization separation continued until 1897 when the 2 associations reunited under the name of the National Dental Association (NDA). In 1922 the NDA once again assumed the name American Dental Association.

### **CIVIL WAR (1861 – 1865)**

During the American Civil War, Union Soldiers continued to get dental care wherever they could, even though large numbers of potential recruits were turned away because they did not have 6 opposing upper and lower front teeth to bite off the end of the tough, paper powder cartridges used with muzzle-loaded weapons. Answering civilian criticism of poor access to dental care, a succession of Army leaders, resisting the idea of providing dentists to the Army, repeated the spurious argument that existing surgeons had the skill and knowledge to manage dental emergencies.

13 May 1861 – Confederate leadership was apparently more sympathetic to dental needs of Soldiers because as early as 13 May 1861 Dr J. B. Deadman, a North Carolina dentist who enlisted as a private in the Confederate Army, was appointed to be a post dentist. Throughout the war, dentists were being either detailed from their units or contracted as civilians to serve the Confederate military.

17 February 1864 – The Army of the Confederacy finally acknowledged that its Soldiers could not afford dental care when the Congress of the Confederate States of America (CSA) passed a law to conscript dentists. It became policy that all Soldiers with dental training who were already on duty were to be assigned to provide dental services, and they were to have “rank, pay and perquisites [privileges] which their position in the army entitles them; and in addition, such extra duty pay for extraordinary skill and industry, as the Surgeon General will allow.” Most CSA dentists were hospital stewards.

September 1864 – Dental Cosmos (a dental journal) reported many actions that had been taken by the ADA and its members to secure dental care for Union Soldiers, including a visit on behalf of the association by Dr S. S. White to President Abraham Lincoln. All efforts to secure such care failed during the Civil War.

4 April 1872 – William Saunders, a hospital steward at West Point became the first Soldier to be recognized as a US military dentist. He was directed by Special Orders to provide dental service for cadets and staff of the US Military Academy at West Point. Saunders had provided dental care as part of his duties since 1858.

Late 1800s – In the late 1800s the American Dental Association and individual dentists continued to lobby Congress for a military dental corps, but legislation introduced on this matter failed to pass.

### **SPANISH-AMERICAN WAR (APRIL 1898 – DECEMBER 1898)**

#### **PHILIPPINE INSURRECTION (FEBRUARY 1899 – JULY 1902)**

For the first time US forces were deployed to foreign soil in Cuba, Puerto Rico, and the Philippines, far from any acceptable source of civilian dental care. Army physicians were forced to confront the reality that their medical training was deficient in care of oral conditions. A significant number of trained dentists served in the capacities of hospital stewards and some were appointed by local command authorities to focus their service on dentistry. Dr W. H. Ware was appointed to practice dentistry and upon deployment in August 1898 established the first Army field dental clinic in Manila, Philippines; and on 30 September 1898, Dr J. W. Horner was designated “Corps Dentist for the Seventh Army Corps” and provided a dental clinic in Jacksonville, Florida. Both were enlisted dentists whose assignments had been as hospital stewards. This recognition of need and demonstration of value of dentists contributed significantly to justifying Army wide use of contract dentists and eventually commissioned status for dental surgeons.

February 1899 – Seven black (African American) regiments were deployed to Cuba during the Spanish-American War. Although it is unclear exactly when CPT William Thomas Jefferson, a dentist in civilian life, deployed it was recorded that

## Highlights in the History of Army Dentistry

he served with his regiment in Cuba and was stationed at San Luis De Cuba in February 1899. In addition to his command responsibilities as a line officer, he also found time to provide dental care for his regiment. Possibly, Dr Jefferson was the first African American dentist to perform dentistry in the US military. He was likely the first African American commissioned officer to provide dental care in the Army although it was as a line officer, not a dental officer.

**2 February 1901** – Still dealing with support of deployed troops at war against the Philippines, Congress passed legislation directing the Army Surgeon General to employ 30 civilian contract dentists to provide dental care for officers and enlisted men of the Regular and Volunteer Army. They would be attached to the Medical Department, not assigned to it. Candidates for the positions had to be graduates of a medical or dental school and to pass a qualifying dental examination. Dental school graduates who were already in the Army Hospital Corps were excused from the exam. These dental surgeons held no rank but wore the same uniform as medical officers, except for silver “DS” insignia on the shoulder boards. Initially they were assigned to posts in continental United States (CONUS), Cuba, Puerto Rico, and the Philippines.

**11 February 1901** – Dr John Sayre Marshall, MD, father of the Army Dental Corps, was appointed to be the first contract dentist, senior supervising contract dental surgeon, and president of the first Army Board of Dental Examiners. Appointed at age 55, his career had already included private practice (1876 – 1901), book publications, specializing and lecturing in oral surgery at several universities, and establishing the Dental Department at Northwestern University (1886). He lobbied for an Army dental service, and for 10 years following his appointment as a contract dental surgeon he provided masterful leadership toward establishing a commissioned Dental Corps. On 13 April 1911, he became the Army’s first commissioned dental officer. He retired on 17 June 1911 as Captain, US Army Dental Corps, at age 65.

**25 February 1901** – The first Army Board of Dental Examiners met in Washington, DC, to begin examinations of 8 candidates. Dr Robert T. Oliver, DDS, of Indiana and Dr Robert W. Morgan, DDS, of Virginia were the second and third contract dentists appointed and joined Board President Marshall to complete the 3-member board. By 21 December 1901, seventy-one dentists had been examined and 28 of the 30 positions had been filled.

**11 November 1901** – African American hospital steward William A. Birch sent an application for appointment to an Army contract dental surgeon position. Documentation showed that he was a 1900 graduate of Indiana Dental College and had been providing dental services to US Soldiers in the Philippines. Dr Birch is probably the first African American to serve as an Army dentist (although officially as an enlisted corpsman). To date, historians have been unable to determine who was the first African American dentist to be commissioned in the US Army Dental Corps.

**20 April 1906** – Dr Leonie von Meusebach-Zasch became the first woman dentist to work for the Army (probably the first woman dentist employed by the US government) when she was hired to support Army emergency relief for victims of the San Francisco earthquake.

**3 March 1911** – The US Army Dental Corps (DC) of commissioned officers was established with the passing of H R 31237, Amendment 49 and President Taft’s signing it into Public Law No. 453, 36 Stat. 1054. This event followed many years of National Dental Association discourse, congressional hearings, and the failure of previous bills. The law provided that dental officers could be of no higher rank than first lieutenant. Contract officers with 3 years’ experience were commissioned first lieutenant. New candidates who were board examined and accepted were appointed Acting Dental Surgeons for a period of 3 years before commissioning. Acting dental surgeons had the same status as contract dentists, received less pay than lieutenants, and could not be ordered to war. Civilian dentists immediately started lobby efforts to upgrade the rank and pay to be more comparable with military physicians. The Act of 3 March 1911 had a major impact on the civilian status of dentistry as a profession. Before the enactment of the military dental corps authorization, the words “dentistry,” “dental profession,” and “dental surgeon” had no significance or recognition under the law. The United States government set precedent for the “official recognition” of dentistry as a profession.

### **WORLD WAR I (6 APRIL 1917 – 11 NOVEMBER 1918)**

**Summer 1914** – The World War began in Europe. Although the US would not declare war until April 1917, concern for readiness to enter the war had a significant affect on changes in US Army and US Army dentistry.

**March 1916** – The Preparedness League of American Dentists, 1,700 civilian dentists, organized to provide free dental service for men wishing to enlist. The League also established a standard course for military training of dentists and provided study clubs for dentists who expected to enter the reserves. Dental schools cooperated by using the League course standards and by making League courses available. Between 4,000 and 5,000 dentists were estimated to have completed the training. By 1918 Preparedness League dentists had provided approximately a million pro bono dental procedures to men selected for military service.

**3 June 1916** – Congress passed the National Defense Act of 1916 that included reorganization of the Army Dental Corps. Under this act, the probationary contract system was abolished, permitting immediate commissioning of dental officers as first lieutenants with advancement to captain after 8 years and to major after 24 years of active service. The act also authorized the Army Dental Reserve Corps.

**September 1916** – The first Army dental training school was established at Fort Bliss, El Paso District, Texas, by CPT Robert T. Oliver. Tensions along the US/Mexican border in 1916, including raids by Pancho Villa, resulted in a dramatic deployment along the border and significant influx of both active and National Guard dental officers. This created awareness that dentists with good civilian education and experience still lacked operational field skills, military administrative knowledge, and trauma related training that are unique to military service. The Fort Bliss dental school served as a model for similar schools needed soon in World War I. (See a more complete description of Army dental education and training in May 1921 entry.)

**6 April 1917** – The United States declared war on Germany and entered World War I with a Dental Corps of 86 Regular officers. By 30 November 1918, the number of active duty dental officers peaked at 4,620 from the Regular Army, Army Reserve, and National Guard, with 1,864 stationed in Europe. Note: In September 1917, 891 dentists who were in the Medical Enlisted Reserve Corps were called to active duty as privates, although 1,079 other reservists were allowed to wait commissioning as Dental Corps officers.

**9 August 1917** – MAJ William H. G. Logan, MD, DDS, a Medical Corps Reserve officer, was appointed to be the chief of the newly established Dental Section, Personnel Division, of the Office of the Surgeon General, and first Chief, Army Dental Corps. As a civilian Dr Logan had been a leader in establishing the Dental Reserve Corps in 1916. As DC Chief he significantly increased the number of Dental Reserve officers, organized maxillofacial surgical teams, and initiated dental officer basic training and an enlisted dental assistant training program at Fort Oglethorpe, Georgia. He was the president of the National Dental Association (1917-1918) and after his discharge on 12 February 1919 became dean of Chicago College of Dental Surgery (1920-1923) and then of Loyola University College of Dentistry (1923-1943).

**20 August 1917** – The first dental unit of the American Expeditionary Forces (AEF) landed in France with CPT Robert T. Oliver in charge. Oliver had been designated on 25 June 1917 to be Chief Dental Surgeon, AEF, by General John J. Pershing. Oliver had developed a good working relationship with Pershing in the Philippines that continued when supporting him in the Mexican border operation. CPT Oliver assumed the dental surgeon duties on 1 September 1917.

**6 October 1917** – A law was passed authorizing Army Dental Corps officers the same rank, pay, promotion, and retirement rights as officers of the Medical Corps. This law also directed that all dental and medical students be permitted to complete their dental or medical education before being called to active duty.

**15 November 1917** – Basic training and combat casualty care courses were established for dental officers at the new Dental Section, Sanitary School, Langres, France. (See a more complete description of Army dental education and training in May 1921 entry.)

**15 March 1918** – Basic and technical training for dental officers and enlisted dental assistants was initiated at Camp Greenleaf, Fort Oglethorpe, Georgia. (See a more complete description of Army dental education and training in May 1921 entry.)

**World War I Statistics** – From July 1917 to May 1919, 1,396,957 Soldiers of the American Expeditionary Forces were treated for many different dental conditions. Dental officers provided 1,505,424 restorations, 384,427 extractions, 60,387 crowns, and 13,140 dentures. Seven dental officers and 7 enlisted dental assistants were killed in action. Eight dental officers died of disease, and 36 dental officers and enlisted dental assistants were wounded in combat.

By 1920 Dental Corps officers were located in England, France, Belgium, Germany, Russia, and Poland.

**12 February 1919** – At COL Logan's discharge, LTC Frank Laflamme was named Chief, Dental Section, Personnel Division, Office of the Surgeon General (OTSG), and became the second Chief, Army Dental Corps. He served as interim chief until August 1919.

**21 August 1919** – COL Robert T. Oliver, now the Dental Corps' ranking officer, returned from his AEF position and was named Chief, Dental Section, Personnel Division, OTSG. He became the third Chief, Army Dental Corps. Before his entry into Army service, Oliver had a successful civilian career that was interrupted by his voluntary enlisted time during the Spanish-American War. His wartime experience influenced him to become an activist in organized dentistry for an Army dental corps. Oliver was one of the original 3 members of the Army Dental Examining Board. COL Oliver was later elected



## Highlights in the History of Army Dentistry

president of the American Dental Association (1930-1931) and while on active duty served as professor for the dental Reserve Officers' Training Corps (ROTC) at the University of Pennsylvania.

**May 1921** – The Medical Field Services School (MFSS) was established at Carlisle Barracks, Pennsylvania. The training in military medical support for dental officers and enlisted dental personnel that had been conducted at the Fort Bliss dental school before the World War, the Sanitary School in Langres, France, and Fort Oglethorpe, Georgia during the War, was centralized at the new MFSS. In January 1922 dentistry specific subjects that had been taught at these schools were transferred to the Army Dental School at the Army Medical Center in Washington, DC. The MFSS continued to teach the medical support and military subjects to dental personnel and remained at Carlisle Barracks until it moved to Fort Sam Houston, San Antonio, Texas, in 1946. In December 1972, as it was occupying new facilities at Fort Sam Houston, the MFSS was redesignated the US Army Academy of Health Sciences (AHS), and in July 1994 the AHS became an element of the Army Medical Department (AMEDD) Center and School instead of a separate command. Enlisted dental training, dental NCO and dental officer military training continued to be conducted by the AHS Dental Science Division. Graduate Dental Education for officers has been delivered under other programs.

**6 January 1922** – The War Department established an Army Dental School at the Army Medical Center in Washington, DC. The faculty included 11 Dental Corps and 18 Medical Corps officers. The school was opened to give postgraduate courses in advanced military dental surgery, provide an organization for research of dental problems, and train enlisted personnel to meet the requirements of dental service. COL Siebert D. Boak was the first commandant. This school was the predecessor of the US Army Institute of Dental Research.

### POST WORLD WAR I DEMOBILIZATION

**30 June 1922** – Congress passed the National Defense Act of 1922, reducing the size of the Army from 300,000 to 150,000 Soldiers and the size of the Regular Army Dental Corps from 298 to 158 officers. DC downsizing was accomplished by retirement, resignation, and the involuntary separation of 77 dental officers.

**1924** – The Army adopted the practice of “expedient dentistry” consisting primarily of emergency care, extractions, and dentures.

**July 1924** – COL Rex H. Rhoades was named Director, Dental Division, OTSG, and the fourth Chief, Army Dental Corps.

**1927** – Three Central Dental Laboratories were established to produce dental appliances and prosthesis. Each laboratory served one or more corps areas. They were established at the Army Medical Center, Washington, DC (later named Walter Reed Army Medical Center); Fort Sam Houston, Texas; and Letterman General Hospital, San Francisco, California. The name was changed to the Regional Dental Activity in 1962 and to Area Dental Laboratory in 1981.

**15 June 1928** – COL Julien R. Bernheim was named Director, Dental Division, OTSG, and fifth Chief, Army Dental Corps.

**1931** – The first dental officer was sent for specialty training in oral surgery.

**15 June 1932** – COL Rex H. Rhoades repeated as Director of Dental Division (now part of Professional Division), OTSG, and became the sixth Chief, Army Dental Corps. The size of the active Dental Corps remained at 158 officers.

**20 September 1934** – COL Frank P. Stone was named Chief, Dental Division, Professional Service, OTSG, and seventh Chief, Army Dental Corps.

### RAMPING UP – ANTICIPATING A NEW WAR

**30 June 1937** – The first increase in the size of the Dental Corps since 1922 occurred. The number of Regular Army dental officers increased by 25 to 183 Dental Corps officers. This began a series of increases leading up to the massive mobilization of World War II.

**29 January 1938** – The rank of brigadier general was authorized by the 75th Congress (Public Law 423) for the director of the Dental Division, OTSG. This law also directed an increase in the Regular Army Dental Corps to 258 officers. In April 1938 the authorized DC strength was again increased to 316 officers. In this time frame the Dental Reserve Corps reached 5,199 officers, exceeding the projected wartime requirement of 5,000 officers. All reserve Dental Corps recruitment was directed to cease, and the size of the Dental Reserve Corps rapidly dropped below 5,000.

## THE ARMY MEDICAL DEPARTMENT JOURNAL

14 March 1938 – Leigh C. Fairbank was promoted to Brigadier General becoming the first Dental Corps officer to achieve general officer rank. He was named Chief of the Dental Division, OTSG, and eighth Chief, Army Dental Corps. General Fairbank served until 16 March 1942. (See also 18 December 1959 entry.)

1 July 1939 – The Army Dental Internship Program (one year) opened with 8 civilian dentists. Upon successful completion of the program, the dentists would be eligible for commissioning as first lieutenants.

### **WORLD WAR II (8 DECEMBER 1941 – 2 SEPTEMBER 1945)**

Aggressive acts by Germany in Europe and by Japan against China in 1937 and 1938 resulted in American apprehension about the potential for involvement in hostilities. The 1 September 1939 German invasion of Poland precipitated the declaration of war on Germany by France and Great Britain. Again military expansion in preparation for war became a factor molding the Army dental service.

October 1941 – The War Manpower Commission established the Procurement and Assignment Service that selected, inducted, and assigned dentists into the military services. As a result of the 1938 suspension of recruitment, the Dental Reserve Corps had dropped to 4,428 by June 1941. Meanwhile the active force was rapidly expanding, activating over 2,000 reserve dental officers during 1941.

8 December 1941 – The day following the bombing of Pearl Harbor by the Japanese, the United States entered World War II with an active duty Dental Corps of 316 Regular Army and 2,589 reserve Dental Corps officers (2,905 total).

28 January 1942 – An Army dental officer, LTC George R. Kennebeck, was named the first chief of the new Dental Section, Office of the Army Air Forces Surgeon General. (See also 12 May 1949 entry concerning establishing USAF.)

17 March 1942 – BG Robert H. Mills was appointed Director, Dental Division, OTSG, Assistant Surgeon General, and ninth Chief, Army Dental Corps (now numbering 3,446 officers). Mills was promoted 7 October 1943 to the temporary rank of major general, becoming the first dental officer to hold this rank. He retired on 17 March 1946.

9 April 1942 – MAJ Roy L. Bodine, Jr became a prisoner of war of the Japanese when Bataan in the Philippines fell. He spent 3 and a half years as a POW in the Philippines, Japan and Korea before being liberated on 7 September 1945. His acts of caring for and leadership of fellow POWs were inspiring and representative of other US Army dental POWs. His leadership to the Dental Corps continued until his retirement at the rank of Colonel in 1961.

1943 – The Army was faced with a shortage of glass artificial eyes. Research-minded Army dental officers in 3 widely separated locations experimented with clear synthetic resin and fashioned a plastic eye which was adopted for routine use by the Army. Army dental personnel were also important in the development of improved custom hearing-aid adapters and fabrication techniques of tantalum plates for repair of skull defects.

Dental services in Replacement Centers operated on 8-hour shifts around the clock because of a shortage of dental equipment and facilities. Later this would be cut to two 8-hour shifts as newly constructed dental clinics were completed to provide dental care for the Soldiers during their 15-day stay at the centers.

7 July 1944 – Ben Louis Salomon, Captain, US Army Dental Corps (later to posthumously be awarded the Medal of Honor) was killed in action on the Pacific island of Saipan while valiantly defending severely wounded Soldiers and covering the evacuation of ambulatory wounded. CPT Salomon, a graduate of the Dental College of the University of Southern California in 1937, was acting battalion surgeon for the 2d Battalion, 105th Infantry Regiment, 27th Infantry Division, when a massive banzai suicide attack of 3,000-5,000 Japanese Soldiers struck the 1st and 2d Battalions outside of Tanapag village early on the morning of 7 July 1944. Japanese Soldiers quickly penetrated the American lines and advanced into the battalion's rear areas where they began attacking the patients at Salomon's battalion aid station. In hand-to-hand combat, Salomon fought off the attackers and then took over a machine gun whose crew had been killed so that his medics and the walking wounded would have time to get back to the regimental aid station. When US forces reoccupied the area on 8 July, CPT Salomon was found dead at the machine gun with 98 Japanese Soldiers piled in front of his position. Although recommended for the Medal of Honor in July 1945, the recommendation was not sent forward for approval because of a misinterpretation at Division level of the Geneva Convention concerning medics' use of weapons. The Army Dental Corps honored CPT Salomon by memorialization of a Dental Clinic at Fort Benning, GA in his name. It would be over 56 years before Salomon's heroism was finally recognized with presentation of the Medal of Honor. (See entry for 1 May 2002) CPT Salomon is the only Army Dental Corps officer to receive a Medal of Honor.

For a more detailed account of CPT Ben L. Salomon and the long quest to obtain a Medal of Honor in recognition of his selfless actions, go to: <http://history.amedd.army.mil/moh/Salomon.html>

## Highlights in the History of Army Dentistry

1 November 1944 – The Dental Corps active duty strength reached its highest level with 15,292 officers. By 31 May, 1945, 7,103 of these officers would be overseas. The concept of operations throughout this war was unit dental support, as opposed to area support, with each Army division typically having more than 30 dental officers.

World War II Statistics – During the period 1 January 1942, – 31 August 1945, the Army Dental Corps completed the following procedures: 16,231,264 extractions, 69,546,560 restorations, 579,473 full dentures, and 2,032,684 partial dentures. Twenty dental officers were killed by enemy action. In addition to these 20, 5 later succumbed to their wounds, 10 died in captivity, and 81 lost their lives to disease and nonbattle injury. Over 18,000 dentists served during World War II.

1946 – The Medical Field Service School (MFSS), including the Dental Section, moved to Fort Sam Houston, Texas, after 26 years at Carlisle Barracks, Pennsylvania. In December 1972, as it was occupying new facilities at Fort Sam Houston, the MFSS was redesignated the US Army Academy of Health Sciences (AHS), and in July 1994 the AHS became a subordinate element of the Army Medical Department Center and School instead of a separate command. (See also May 1921 entry for more on organizational lineage.)

17 March 1946 – BG Thomas L. Smith was named Director, Dental Division, OTSG, Assistant Surgeon General, and tenth Chief, Army Dental Corps (now reduced to 5,011 officers). As a result of a law passed 7 August 1947 to grant the permanent rank of major general to the chief of the Army Dental Corps, General Smith was promoted to major general on 24 January 1948. General Smith served as chief until 20 April 1950.

12 May 1949 – The US Air Force Dental Service was established. MG George R. Kennebeck moved from Chief of the Army Air Corps Dental Service to be Chief of the US Air Force Dental Corps.

20 June 1950 – MG Walter D. Love was sworn in as Chief, Dental Division, OTSG, and eleventh Chief, Army Dental Corps. He retired on 30 April 1954.

### KOREAN WAR (25 JUNE 1950 – 27 JULY 1953)

25 June 1950 – North Korea invaded South Korea. By the next day, President Harry S. Truman had authorized use of US forces in the conflict.

21 March 1951 – Dr Helen E. Myers was commissioned into the Army Dental Corps, becoming the first woman to serve as an Army dental officer. Entering with the rank of captain, she reported for duty at Fort Lee, Virginia.

1952 – The concept of area dental support, as opposed to unit dental support, was introduced during the Korean War. This would evolve into the KJ Detachment of the Vietnam War era, redesignated the HA Detachment in the early 1970s, and subsequently the Dental Company of the post-1991 Gulf War era. The idea of a dental command and control unit (AI Detachment) was also conceived for the Korean operation but not implemented until Vietnam. Note: Units were given random letter designations unrelated to titles or functions. The AI Detachment evolved into the Dental Battalion after the 1991 Persian Gulf War. (See entries 23 December 1965, 6 April 1992, 30 June 1993, and 30 March 2003 for later evolution of dental command and control.)

27 June 1952 – COL (later brigadier general) Pearson W. Brown was the first dental officer to graduate from the resident course, US Army Command and General Staff College, Fort Leavenworth, Kansas. On 20 June 1957, COL Brown also became the first dental officer to graduate from the resident course, US Army War College, Carlisle Barracks. BG Brown had been one of the original 8 Army dental interns in 1939.

Korean War Statistics – Peak strength of the Dental Corps during this conflict was 2,641 officers with 370 serving in Korea. Two Army dental officers were killed and one declared dead while missing in action.

12 April 1954 – BG Oscar P. Snyder was promoted to major general and sworn in as Chief, Dental Division, OTSG, and twelfth Chief, Army Dental Corps. General Snyder retired in November 1956.

1956 – Army dentistry's first involvement in the Vietnam War was by LTC (later BG) Jack P. Pollock, during a 120-day temporary duty assignment to the US Military Assistance Advisory Group, Vietnam. He served as the Medical Advisory Team chief and the dental adviser for the team. Later (1967-1968) COL Pollock served as commander of the 932d Medical Detachment (AI) in Vietnam, and in 1970 he was the first armed forces dental officer to be appointed as the Special Assistant for Dental Affairs, Office of the Assistant Secretary of Defense for Health Affairs. He was promoted to brigadier general in April 1972 and was the first Deputy Commander, Health Services Command (1973-1977).

1 December 1956 – BG James M. Epperly was promoted to major general, and sworn in as Chief, Dental Division, OTSG, and 13th Chief, Army Dental Corps. He retired in September 1960.



1957 – A course of instruction was established at the Medical Field Service School, Fort Sam Houston, to train enlisted military dental hygienists.

10 August 1957 – The first modern, air-conditioned dental clinic built exclusively for dentistry to replace the World War II “temporary” structures was opened and memorialized in the name of CPT John S. Marshall at Fort Dix, New Jersey. That clinic was closed in the early 1990s. On March 31, 2009, the CPT John Sayre Marshall Dental Clinic was dedicated in memory of CPT Marshall at Fort Drum, New York.

18 December 1959 – BG (Ret) Leigh C. Fairbank personally presented the first award of the Fairbank Medal to MAJ Kenneth W. Thomasson. The award, endowed by General Fairbank, honors the dental officer with the highest scholastic standing in the AMEDD Officer’s Advanced Course of the Medical Field Service School.

1 August 1960 – COL Joseph L. Bernier was promoted to major general and sworn in as Chief, Dental Division, OTSG, Assistant Surgeon General for Dental Services, and fourteenth Chief, Army Dental Corps (now numbering 1,747 officers). General Bernier is well known for initiating an aggressive Army-wide preventive dentistry program in November 1960. He used the Army preventive program as a model for promoting the prevention movement in civilian practice. Among specialists in oral pathology, Dr Bernier is given credit for leadership in organizing oral pathology as a specialty and specifically for establishing the American Academy of Oral Pathology.

1 July 1961 – The first 2-year Army General Dentistry Residency Program was established at Fort Hood, Texas.

1 January 1962 – The US Army Institute of Dental Research was activated at Walter Reed Army Medical Center, replacing the Army Dental School and the Dental Division, Walter Reed Army Institute of Research. Its mission continued to include both research and postgraduate dental training.

1 March 1962 – Central Dental Laboratories in CONUS were redesignated US Army Regional Dental Activities. The name was changed again in 1981 to the US Army Area Dental Laboratory; then in 1998, laboratory consolidation resulted in only one remaining laboratory at Fort Gordon, being redesignated The Army Dental Laboratory.

#### **VIETNAM WAR (1950 – 1973)**

Although establishing dates for the beginning and ending of US Army involvement in the Vietnam War is debatable, the US established a US Military Assistance Advisory Group (MAAG) as early as 3 August 1950 and the last US combat troops left Vietnam 29 March 1973. There was relatively continuous involvement of US forces between those dates. As for US Army Dental Corps participation, it began in 1956 with LTC (later brigadier general) Jack P. Pollock’s MAAG assignment (see 1956 entry) and ended 1 April 1973 with the departure of the single remaining Dental Corps officer, MAJ Alfred F. Tortorelli. (see 1 April 1973 entry).

18 April 1962 – The 36th Medical Detachment (Dental Service) under the command of LTC John W. Rudisill arrived at Nha Trang, Vietnam. This was the first dental unit to deploy and was of the KJ Detachment type (area support) originally fielded at the end of the Korean War. Initially dental units deployed with equipment sets that resembled those used during World War II and Korea. The electric motor, belt-driven handpieces and old fixed-position tubular canvas chairs were relics of previous wars. After the first few years of supplementing the outdated equipment with stateside-type fixed equipment, a compressed-air, rotor handpiece system (the Encore unit), developed specifically for field military use, was delivered, giving a modern, mobile capability required for operational support.

23 December 1965 – Operational dental command and control was realized for the first time with the deployment to Vietnam of the 932d Medical Detachment. This AI Detachment (command and control) was assigned to the 44th Medical Brigade, and by August 1968 controlled 13 subordinate KJ Detachments (area support). Dramatic improvement in dental operation proved the value of dental command over dental assets.

14 July 1967 – Army Regulation (AR) 40-4, Army Medical Service Facilities, organized installation dental service in CONUS to be within the Medical Support Activity (MEDSAC) for administrative purposes. About a year later the MEDSAC was converted to an Army Medical Department Activity (MEDDAC) with the post hospital commander having command authority over dental services. In Vietnam the value of dental command and control was being proven while conversely, under this CONUS organization, making dentistry subordinate to hospital command was shown to be inefficient. In addition to problems with securing appropriate resources and low morale of dental personnel, large numbers of Soldiers were being deployed without meeting the dental fitness standards enforced in previous wars.

15 November 1967 – BG Robert B. Shira was promoted to major general and sworn in as Assistant Surgeon General for Dental Services, OTSG, and 15th Chief, Army Dental Corps (then 2,656 officers strong). After General Shira’s retirement in 1971 he became dean of Tufts University School of Dental Medicine and was elected president of the ADA (1975-1976).

## Highlights in the History of Army Dentistry

1968 – Major improvements in Vietnam mission support occurred after General Shira visited Vietnam in the spring of 1968. Tactical commanders in the field complained bitterly to him about Soldiers lost from their duties because of dental emergencies. Improvement measures included: a 20% increase in dental officer strength in Vietnam by June, increased availability of field dental equipment, implementation of the Dental Combat Effectiveness Program (DCEP) to eliminate potential dental emergency conditions in Soldiers with combat military occupation specialties, use of an improved intermediate restorative material (IRM) to avoid unnecessary extractions, field screening and sustaining care at theater in-processing and at forward troop sites in Vietnam, and mass application of self-applied 9% fluoride paste.

6 December 1968 – The Army Oral Health Maintenance Program (AOHMP) was implemented targeting active duty Soldiers age 25 years and younger. Caries control was the clinical goal. The program required Soldiers in this target group to have an annual dental exam during their month of birth and offered appointments to eliminate adverse dental conditions. Oral hygiene instruction and professionally applied topical fluorides were emphasized.

January 1970 – The Army General Dentistry Board provided to Army graduates of the 2-year in General Dentistry Residency the first professional certification examination for a “specialty” of General Dentistry. On 15 May 1978, the board offered the certification examination to qualified candidates from the Navy and Air Force. On 29 July 1980, the name was changed to the Federal Services Board of General Dentistry and offered the certifying exam to all of the US federal services. In August 2003 the Dental Corps Chiefs of the Army, Air Force, Navy, Public Health Service and Veterans Administration gave final approval for the merger with the civilian American Board of General Dentistry, with the ABGD taking over completely over a period extending to 2008.

September 1970 – Mutual support programs between reserve component dental units and active dental services began during weekend training at Fort Devens, Massachusetts. These units treated family members and retired Soldiers who otherwise would not have received dental care. The Mutual Support Program, expanded on 16 May 1974, assigned dental reserve personnel from 9 readiness regions to installation dental activities.

11 January 1971 – Phase II of the Army Oral Health Maintenance Program (AOHMP) was implemented, calling for the birth-month dental examination and preventively oriented care for Soldiers over 25. The emphasis in this age group was prevention of periodontal disease. In October 1974 the 2 phases of the AOHMP were combined into a single program with no age-specific distinction in treatment goals.

1 December 1971 – COL Edwin H. Smith, Jr., was promoted to major general and sworn in as Assistant Surgeon General for Dental Services, OTSG. He was the 16th Chief, Army Dental Corps.

27 March 1972 – The Dental Therapy Assistant (DTA) concept was approved by Department of the Army for immediate implementation. DTAs were expanded duty auxiliaries who could work under the supervision of dental officers to provide certain reversible dental procedures such as placing rubber dam and placing and carving amalgam. Under this concept dental officers increased their productivity by working with a team of regular assistants and one or 2 DTAs. Training of civilian assistants to be DTAs began in the fall of 1972 at 22 CONUS installations, with a curriculum designed and supported by the Dental Science Division at the Medical Field Service School (later called the Academy of Health Sciences). Also in the fall of 1972 a new dental clinic design was approved that better supported the team concept and made more efficient use of multiple operatories. Due in large part to perceptions in the civilian sector that substituting dental auxiliary labor for dentist labor was not necessary to meet public demand for dental services, the Army’s DTA training was discontinued. The existing DTAs continued to function until normal attrition of promotion and leaving Army employment eliminated them. (See also the March 2002 entry concerning EFDA, a later program to establish a dental personnel type with expanded function.)

1 April 1973 – The end of Army dental service in Vietnam was marked by the departure of the single remaining Dental Corps officer, MAJ Alfred F. Tortorelli. Withdrawal of dental units had begun in July 1969; by 30 April 1972, the command and control unit (932d Medical Detachment) had been inactivated; and on 12 February 1973, the last dental unit (38th Medical Detachment (HA)) was inactivated.

Vietnam War Statistics – The greatest number of dental officers on active duty during the conflict was 2,817 with a maximum of 290 being stationed in Vietnam at any one time. The concept of support was a combination of unit support (approximately one dentist per brigade), hospital support (usually an oral surgeon per hospital), and area support (14 dental service units and one dental command and control unit). Four Army dental officers and 4 dental enlisted Soldiers were killed in Vietnam.

1 April 1973 – The US Army Health Services Command (HSC) was activated at Fort Sam Houston, Texas, to provide command and control over all active duty medical assets in CONUS except field units (TOE). Previously, many technical functions had been controlled by the Office of the Surgeon General, and command was provided by commanders at local installations. Dental staff guidance for HSC was provided by the Director of Dental Services, initially COL Richard Howard. BG Jack Pollock, DC, was assigned as the first Deputy Commander, HSC.

1974 – The Department of Defense (DoD) directed all 3 services to adopt a standard productivity reporting method. The Army had previously used a similar Army wide dental reporting system until 1967. This allowed the Army Dental Corps to compare current productivity with that achieved before MEDDAC assumed command over dental services. The analysis showed productivity had fallen 17%. Other statistics showed the Dental Corps to have the lowest retention rate of all Army officer corps. As a result, The Surgeon General appointed ad hoc committee of general officers to review dental services. The committee verified many inefficiencies of the MEDDAC organization as it related to dental services.

1 July 1974 – The one-year General Practice Residency Program replaced the one-year Dental Intern Program. This residency was an effective recruiting tool and provided a reservoir of better trained young officers for many remote assignments.

2 May 1975 – A job description for civilian Community Health Dental Hygienists (CHDH) was approved by Headquarters, Department of the Army. This action acknowledged that in addition to clinical preventive dentistry there are many community based measures that contribute significantly to Soldier and family member oral health. However over the next decade, the need to use hygienists in their clinical rolls diverted their concentration on community efforts and the use of CHDH and these positions vanished from the Army.

29 August 1975 – COL George Kuttas was promoted to brigadier general and assumed the position of Deputy Commander, 7th Medical Command, Europe. He was the first Dental Corps general officer to serve in this position.

1 September 1975 – BG Surindar N. Bhaskar was promoted to major general and sworn in as Assistant Surgeon General for Dental Services, OTSG, and as 17th Chief, Army Dental Corps, with 1,856 officers. Armed with the recommendations of the Army Surgeon General's ad hoc committee on dental services, General Bhaskar set about planning and implementing the Installation Dental Service Management Program.

18 February 1976 – The Installation Dental Service Management Program was initiated by the Surgeon General as a trial. The program consisted of organizational changes to give to Dental Corps officers authority over, and accountability for, dental functions. Also, a large number of measures were directed at increasing dental officer time for patient care, reducing administrative overhead, and basing dental leadership appointments on merit. The trial was successful. See entries about regulatory changes in December 1977 and legislative changes in October 1978.

27 May 1976 – The Mobilization Designee (MOBDES) Program for reserve Dental Corps officers was implemented. Reserve dental officers assigned to the MOBDES Program trained to play a specific wartime role in the event of a reserve mobilization and to serve as the adviser for all reserve activities related to their unit.

29 November 1976 – The Dental Corps was the first AMEDD corps to hold a command selection board and develop a command selection list from which dental commanders and other key dental staff positions would be filled. The philosophy was that selection of commanders should be based on merit rather than on date of rank.

16 May 1977 – Staffing of dental commands was revised to make the executive officer a Medical Service Corps (MSC) position. With this change, trained health care administrators relieved dental officers of administrative tasks so they could spend more time on activities for which their dental training was required.

7 December 1977 – Changes to AR 40-1, Composition, Mission, and Functions of the Army Medical Department, and AR 40-4, Army Medical Department Facilities/Activities, directed worldwide adoption of the major elements of the Installation Dental Service Management Program initiated in February 1976. This followed health care studies that indicated a more than 65% increase in productivity and dramatic improvements in dental officer retention rates under the program. The regulation established the Dental Activity (DENTAC) concept: all dental units were to be commanded by a dental officer, funds for dental operations would be "fenced," and enlisted personnel in these units would be under the control of dental officers. The installation dental commander would be responsible directly to the post commander rather than through the post medical commander.

21 September 1978 – The Dental Specialist (Military Occupational Specialty [MOS] 91E) course structure was revised to create a 44-week Dental Hygienist training course. The course would be accredited by the ADA and produce graduates who were eligible for state dental hygiene board examinations.



## Highlights in the History of Army Dentistry

20 October 1978 – US Public Law 95-485, 10 USC 3081, was passed by Congress, enacting the principles of the Installation Dental Service Management Program. The law specified that the Assistant Surgeon General/Chief of the Dental Corps was responsible to the Surgeon General and through the Surgeon General to the Chief of Staff of the Army, for all matters concerning dentistry and dental health of the Army. It also stipulated that dental personnel would be organized into dental units commanded by a Dental Corps officer and that the dental commander was directly responsible to the commander of the installation served. Under this DENTAC concept, management indicators continued to demonstrate the value of dental command and control.

17 February 1979 – BG George Kuttas was promoted to major general and sworn in as Assistant Surgeon General for Dental Services and 18th Chief, Army Dental Corps, with 1,764 officers.

26 October 1981 – The 4 Regional Dental Activities that provided dental laboratory support to the Army were redesignated US Army Area Dental Laboratories (ADL). They were located at Alameda, California; Fort Gordon, Georgia; Fort Sam Houston, Texas; and Walter Reed Army Medical Center, Washington, DC

8 July 1982 – The DoD Dental Chiefs Council was officially established as a subordinate element of the DoD Health Council by DoD Directive 5136.8. The primary members of this Council were the Chiefs of the Dental Corps for the Army, Navy and Air Force. The Chief Dental Officer of the Public Health Insurance was also invited to participate.

1 December 1982 – BG H. Thomas Chandler was promoted to major general and sworn in as Assistant Surgeon General for Dental Services and 19th Chief, Army Dental Corps (1,810 officers).

25 October 1983 – Operation Urgent Fury. In the wake of a violent overthrow of the Caribbean island government of Grenada, the United States combined with 6 Caribbean states in a joint operation to restore peace and public order. Dental personnel were organic to the deploying units. After-action reports indicated that dental officers were heavily involved in alternate wartime roles (eg, combat casualty care) during the combat phase of the operation; provided sustaining dental care to Soldiers during the occupation phase; and delivered humanitarian support at the request of Grenadian civilian authorities since the operation severely disrupted the civilian dental infrastructure.

8 November 1983 – The Surgeon General directed that combat casualty and surgical training be provided to dental officers to prepare them for alternate medical roles during wartime. Since dental officers are used to augment AMEDD casualty care capability, during periods of overwhelming casualties, they should receive appropriate training.

12 December 1985 – An airplane carrying 248 Soldiers of the 101st Airborne Division crashed in Gander, Newfoundland, killing all aboard. Contrary to administrative policy of that time, their dental records were on board and lost in the resulting fire. This created difficulties in identifying remains. In order to avoid future mass casualty identification problems, personnel regulations were modified to make adequate dental identification records a requirement for operational troop movement. By January 1986 a program was established to store backup (duplicate) panographic radiographs at the Central Panograph Storage Facility (CPSF) in Monterey, California. During the early 1990s the use of antemortem/postmortem DNA sample comparison, and the capability to take, store and retrieve digital panographic images negated the need for physical, central storage and the CPSF was closed.

1 December 1986 – BG Bill B. Lefler was promoted to major general and sworn in as Assistant Surgeon General for Dental Services and 20th Chief, Army Dental Corps, with 1,715 officers.

1 March 1987 – In an update of AR 40-35, Preventive Dentistry, the Oral Health Fitness Program replaced the Army Oral Health Maintenance Program as the method for improving Soldier readiness. The principal feature of the program was the Dental Fitness Classification System to identify and target Soldiers at highest risk of being casualties from preventable dental conditions.

1 August 1987 – The Dependents Dental Plan (DDP) was first implemented (authorized on 8 November 1985 by PL 99-145 and funded in December 1986 by PL 99-500, the FY 1987 Defense Appropriations Bill). This was voluntary dental insurance for family members of active duty military personnel. The cost of the premium was shared by the government and the Soldier. The plan paid 100% of diagnosis and preventive services and 80% of most restorative procedures.

1 October 1987 – Eighty-one contract civilian dentists were hired for CONUS dental clinics. This action was required due to a loss of military Dental Corps positions, reducing the authorized strength to 1,679. (Actual assigned strength at that time was 1,648 officers.)

1 June 1989 – Fixed prosthodontics (Area of Concentration [AOC] 63F) and removable prosthodontics (AOC 63G) specialties were combined into the personnel management code for prosthodontics (AOC 63F); training was combined into a single residency training program of prosthodontics.

20 December 1989 – Operation Just Cause. US troops forcefully took control of Panama, partly because of physical harassment by Panamanian Defense Forces of US personnel stationed in that country, and largely to remove dictator Manuel Noriega because of his corrupt military oppression and his support of illegal drug trafficking. The dental support for maneuvering troops came predominately from the Panama DENTAC, with the addition of unit dental support that deployed with CONUS-based units. The operation was completed by January 1990.

12 January 1990 – AR 600-8-101, Personnel Processing (In-and-Out and Mobilization Processing), implemented dental readiness standards for all military personnel movement as a means of enforcing the Oral Health Fitness Program described in AR 40-35, Preventive Dentistry. Both regulations require as a condition for deployment, that Soldiers attain oral health level (as indexed by the dental fitness class) that lowers the risk of dental emergency for at least a year.

#### **PERSIAN GULF WAR (1990 – 1991)**

2 August 1990 – Iraq invaded Kuwait threatening the stability of the region. A coalition force of approximately 20 nations lead by the US was immediately organized to liberate Kuwait.

8 August 1990 – The first US troop units arrived in Saudi Arabia along with their organic unit dental support. (Army dental support continued for a year past the end of the conflict, until February 1992.)

13 August 1990 – The advance party of the 257th Medical Detachment (Dental Service) arrived in the Kuwait Theater of Operations (KTO). The main body followed within the next few weeks.

23 August 1990 – The activation for the impending operation of reserve component units began. Dental Activities expanded for dental processing during mobilization and deployment. Reserve and National Guard personnel were found to have a much greater requirement for dental readiness procedures than active duty Soldiers.

18 September 1990 – The Dental Consultant, US Army Central Command, arrived in Riyadh, Saudi Arabia, to provide dental staff support to this major Army command headquarters.

1 December 1990 – BG Thomas R. Tempel was promoted to major general, and on 3 December became the Assistant Surgeon General for Dental Services and the 21st Chief, Army Dental Corps. The active duty Dental Corps numbered 1,619 officers.

8 December 1990 – Dental units from Europe began to arrive in the KTO. They included the 2d Medical Detachment (AI) for command and control and the 87th, 122d, and 123d Medical Detachments (HA) for area support dental services. Before the combat phase started the units were task organized so that the 2d Med Det, 122d Med Det, and 123d Med Det supported echelons above corps; the 87th Med Det supported the VII Corps; and the 257th Med Det supported the XVIII Airborne Corps. Oral and maxillofacial surgeons accompanied Army hospitals, and maneuver units had their organic unit dental support. Until actual combat started, the massive military buildup was intended to deter Iraq from further aggression and was called Operation DESERT SHIELD. During this phase, dental support provided care to sustain the oral health of the force.

17 January 1991 – The air war started. The combat phase of the war was called Operation DESERT STORM. Army dental elements moved with troops to treat dental emergencies and provide dental sustaining care to Soldiers while waiting for the ground war to start.

24 February 1991 – The ground war began. Dental care was provided to treat dental emergencies, treat oral and maxillofacial combat casualties, and perform alternate wartime roles. Emergency dental care was also provided to civilian refugees and enemy prisoners of war.

27 February 1991 – The combat ended and dental units resumed sustaining dental care for the US military force. During the phased withdrawal of supported units dental units were also redeployed. The last dental unit to withdraw was the 122d Med Det, remaining until February 1992 to support residual security and redeployment personnel.

Persian Gulf War Statistics – Mobilization and deployment dental processing was provided to 243,829 DoD personnel between 2 August 1990 and the end of the war. Five reserve dental units and a number of Individual Mobilization Augmentees (IMA) were activated to help with the massive dental workload brought on by reserve force mobilization. This period also saw the stateside dental capability depleted by deployment of active duty dental personnel. There were 550 dental reservists activated: 223 DC officers, 5 MSC officers, and 322 enlisted. In the KTO, by the time of peak US Army activity in February 1991, 300,000 Soldiers were being supported by 25 oral and maxillofacial surgeons, 96 other dental officers, and dental enlisted personnel.

## Highlights in the History of Army Dentistry

### END OF COLD WAR

Events in 1989 and 1990 in Eastern Europe led to the dissolution of the Soviet Union and dramatic movement toward democracy of former Communist-bloc countries. US military planners quickly began actions to draw down the size of the force in Europe, as well as to downsize the US military forces worldwide. Downsizing and restructuring the dental organization became the main trends of the early 1990s. Downsizing required that some dental officers who were eligible for retirement be mandated to do so by Selective Early Retirement Boards (SERBs). Other officers were offered severance bonuses and partial retirement benefits for early separation or retirement. Fortunately, involuntary reduction in force (RIF) measures were not needed.

1991 – The Area Dental Laboratories (ADL) at Alameda, CA and at Walter Reed were closed, leaving ADL at Fort Gordon and Fort Sam Houston to provide dental laboratory services to Army dental activities.

16 October 1991 – Strategic plan “Medical Force 2000” began its restructuring of dental units in Europe by reflagging the 87th and 561st Medical Detachments (HA) to be Medical Companies (Dental Service). Other HA detachments converted to the new force structure over the next several years.

6 April 1992 – The 163rd Medical Battalion (Dental Service) was activated in Korea, becoming the first dental TOE command and control unit (formerly a Medical Detachment, AI) to function under the Medical Force 2000 structure. Subordinate units included the newly reflagged 655th and 618th Medical Companies (DS) and the 56th Medical Detachment (DS).

27 August 1992 – Operation Andrew. Immediately following the devastating impact of Hurricane Andrew on 24-26 August, the 257th Medical Detachment (DS), and dental elements of the 82d Airborne and 10th Mountain Divisions carried out a textbook example of effective domestic support activities to help the civilian dental community reestablish dental services to the affected area.

9 December 1992 – Operation Restore Hope (December 1992-March 1994). US troops were deployed to the east African country of Somalia to provide security for international humanitarian famine relief organizations against conditions of anarchy and armed gangs. Marines and 10th Mountain Division members made up a force of about 21,000. Army dental support was provided by 11 dental officers and the supporting dental assistants. These personnel were split between 2 periods of rotation.

31 December 1992 – Mandatory reductions under the Conventional Forces Europe (CFE) Treaty included reduced dental assets. Prior to CFE there were 11 Dental Activities (DENTAC) in Europe with 62 Dental Treatment Facilities (DTF). By 1995 there were 3 remaining DENTAC at Landstuhl, Heidelberg, and Wuerzburg, Germany, with 7 Dental Clinic Commands subordinate to them. Collocated with the TDA dental units in 1995 were also 6 TOE dental units under the 93d Medical Battalion (dental command and control unit). ( See also 30 June 1993 entry.) Most of the positions in the TOE were filled by personnel from the TDA units through the Professional Filler System (PROFIS) and memorandums of agreement.

January 1993 – AMEDD reorganization included assigning MG Thomas R. Tempel to the position of Deputy Surgeon General. The reorganization also established the US Army Medical Command (MEDCOM), with worldwide command and control over all Army TDA medical assets. The headquarters was established in San Antonio, Texas, replacing the Headquarters, Health Services Command. The Surgeon General then assumed 2 “hats”: as Surgeon General he continued as the senior medical staff officer to the Army Chief of Staff, and he also became the commander of the MEDCOM. After MG Tempel left the position of Assistant Surgeon General and Chief, Army Dental Corps, in December 1994 he continued in the position of Deputy Surgeon General.

30 June 1993 – Headquarters, 93d Medical Battalion (Dental Service), was activated. Through the Medical Force 2000 restructuring initiative, the 93d replaced the 2d Medical Detachment (AI) as the dental command and control headquarters for designated dental companies in Europe.

1 October 1993 – The US Army Institute of Dental Research was reorganized as the US Army Dental Research Detachment, subordinate to the Walter Reed Army Institute of Research, Walter Reed Army Medical Center, Washington, DC.

1 November 1993 – The US Army Dental Command (DENCOM) was provisionally activated in San Antonio, Texas, as a major subordinate element of the US Army Medical Command. COL (later major general) Patrick D. Sculley, previously the Director of Dental Service, HSC, became the DENCOM’s first commander. (On 2 October 1994, provisional status was removed.) This action established Army dental service delivery under a dental command with worldwide authority over all TDA dental units. Subordinate to the DENCOM were 8 Dental Service Support Areas (DSSA). Subordinate to the DSSA



## THE ARMY MEDICAL DEPARTMENT JOURNAL

were a total of 31 DENTAC and 20 Dental Clinic Commands and the Area Dental Laboratories. This organization was transitional to one officially adopted on 1 June 1998. (See entry for 1 June 1998.)

13 July 1994 – BG(P) John J. Cuddy, a Dental Corps officer, assumed command of the US Army Medical Department Center and School at Fort Sam Houston, Texas. On 18 July BG Cuddy was frocked with rank of major general.

14 July 1994 – BG Robert E. Brady assumed command of the 30th Medical Brigade, US Army, Europe. The 30th Medical Brigade replaced the 7th Medical Command for medical command and control of all field medical units (TOE) in Europe. Having a dental officer command a major medical TOE unit was part of the Surgeon General's (LTG Alcide M. LaNoue's) policy to make assignment of general officer positions in the AMEDD without regard to Corps. Appointment of MG Tempel as Deputy Surgeon General and MG Cuddy as commander of the AMEDD Center and School were also seen as a result of this policy.

1 October 1994 – The senior dental NCO position at the Medical Battalion (Dental Service) was converted from staff sergeant major, who was specified to be an MOS 91E, to command sergeant major, MOS immaterial from within the Career Management Field (CMF) 91. Soldiers who had been assigned the Military Occupational Specialty (MOS) of 42D, Dental Laboratory Specialist, were reclassified to be a subspecialty of Dental Specialist (MOS 91E) and identified with an Additional Skill Identifier (ASI) of "N5," ie, MOS 91EN5.

1 December 1994 – MG John J. Cuddy officially became the 22nd Chief, US Army Dental Corps. Actual DC strength was 1,244 officers. For the first time in Dental Corps history the Office of the Chief was not physically in the Washington, DC, area, but moved to San Antonio, where MG Cuddy also commanded the AMEDD Center and School. The Senior Dental Corps Staff Officer, however, remained at the Falls Church, Virginia, office to coordinate operations in the Washington area. From October 1995 to 25 February 1996 MG Cuddy was also Installation Commander for Fort Sam Houston, TX.

16 January 1995 – BG Patrick D. Sculley assumed command of the US Army Center for Health Promotion and Preventive Medicine, the first time that this major AMEDD TDA subordinate command of the Medical Command was commanded by a Dental Corps Officer.

January 1996 – December 2005 Balkan operations – SFOR. The demise of the Soviet Union in 1991 had reawakened centuries old ethnic feuds between myriad Balkan factions of Eastern Europe. In early 1998, war broke out between Serbs and ethnic Albanians living in the Serbian province of Kosovo. The US provided troops to NATO peacekeeping forces for a series of 6 month rotations of a Stabilization Force (SFOR) in Bosnia and Herzegovina. Dental support for US Forces was provided by a combination of dental personnel organic to deploying units and personnel requested by FORSCOM, and tasked from DENCOM to support during these rotations.

13 March 1996 – Upon the retirement of MG Tempel, MG Cuddy relocated to Falls Church and assumed the responsibilities of Army Deputy Surgeon General while retaining his position as Chief of the Dental Corps.

1 October 1997 – The Area Dental Laboratory at Fort Sam Houston was closed leaving the Fort Gordon ADL as the only remaining laboratory for dental support. The creation of one Center of Excellence for dental laboratory services allowed consolidation of the dental laboratory mission at Fort Gordon. This business decision was driven by post-cold war downsizing, better capability to manage case transportation and communications, and improved efficiency through technology at Fort Gordon. On 1 July 1998 the name was changed from Area Dental Laboratory to The Army Dental Laboratory.

1 October 1997 – As a result of Interservice Training Review Organization (ITRO) recommendations the Army's Dental Assistant and Dental Laboratory Technician training program was consolidated with that of the Air Force and Navy at Sheppard Air Force Base, Texas. The Department of Dental Science, Fort Sam Houston graduated the last Dental Laboratory Specialist Course (91EN5) on 17 October 1997 and the last Dental Specialist Course (91E) on 31 October 1997. After trial period, the Army felt the consolidated program at Sheppard AFB was not meeting the Army's needs for dental assistants and in October 1999 Army enlisted Dental Specialist (91E) training was returned to the Academy of Health Sciences, Department of Dental Science. Training for 91EN5 remained at Sheppard AFB.

1 June 1998 – The DENCOM's subordinate Dental Service Support Areas (DSSA) were renamed Regional Dental Commands (RDC) and the number of RDC reduced to 6: Great Plains, North Atlantic, Southeast, Western, Pacific, and European Regional Dental Commands. Subordinate to RDA were 28 Dental Activities (DENTAC) and 24 Dental Clinic Commands (DCC).

2 December 1998 – Upon the retirement of MG Cuddy, BG Patrick D. Sculley moved to Falls Church to serve as the Special Assistant to the Surgeon General.

## Highlights in the History of Army Dentistry

1 June 1999 – Upon promotion to major general, Patrick D. Sculley officially became the 23rd Chief, US Army Dental Corps, the Army Deputy Surgeon General, and the Chief of Staff, US Army Medical Command. Actual DC strength was 984. MG Patrick D. Sculley retired 31 May 2002

1 June 1999 – Joseph G. Webb, Jr., then DENCOM Commander, was promoted to Brigadier General, and assumed duties as the Assistant Surgeon General and Deputy Chief of Staff for Force Sustainment, US Army Medical Command, with his office remaining in San Antonio. BG Webb was the first dental officer selected by “corps immaterial” general officer AMEDD board selection. Prior to this Dental Corps officers only competed with other dental officers for star positions.

1 October 1999 – Medical Force 2000 (MF2K), the TOE force structuring concept from 1993, was replaced in 1999 with AMEDD’s Medical Reengineering Initiative (MRI). The first operational organization of the MRI force came on line as the 618th Medical Company (Dental Service) converted to the 618th Dental Company Area Support (MRI) in Seoul, Korea.

The MRI Dental Company replaced a MF2K dental structure that had included a Dental Battalion and 2 Dental Companies, each roughly half the size of the MRI Company. The MF2K Dental Company that was deactivated in this conversion, the 665th Med Co (DS), was the last continuously operating dental unit remaining in the Republic of Korea since the Korean War.

1 October 1999 – As part of a DA pilot program of multicomponent units (MCU) the 673rd Medical Company (DS) at Fort Lewis included 6 reserve dental officers and 8 reserve enlisted Soldiers on the TOE of 59 personnel. (See entry for 20 March 2004 concerning deployment to OIF.)

1 July 2001 – DENCOM underwent reorganization so that under 6 Regional Dental Commands there was 29 Dental Activities and 16 Dental Clinic Commands. The changes included: Ft. Meade Dental Clinic Command was redesignated as a Dental Activity (DENTAC) under the North Atlantic Regional Dental Command; 5 Dental Clinic Commands were redesignated to be Clinics under DENTACs (White Sands, Ft. Monmouth, Redstone Arsenal, Hunter Army Airfield, and Baumholder).

### **HOMELAND SECURITY AND WAR IN AFGHANISTAN(2001 – PRESENT)**

#### **OPERATION NOBLE EAGLE AND OPERATION ENDURING FREEDOM.**

11 September 2001 – Four commercial jetliners, hijacked by terrorists, crashed into the west side of the Pentagon, 2 of the World Trade Center towers in New York City, and into a nonpopulated area of Pennsylvania. Army dental personnel from the Pentagon dental clinic assisted in evacuation, triage and emergency care of over 90 Pentagon wounded. Dental personnel from the Walter Reed dental clinic were also involved in the triage and treatment of wounded evacuated to Walter Reed Army Medical Center.

25 September 2001 – Secretary of Defense Donald H. Rumsfeld announced that the war against terrorism outside the United States would be known as Operation Enduring Freedom, and Operation Noble Eagle would designate US military operations in homeland defense and civil support to US federal, state and local agencies.

September 2001 – Dental forensic operations. As part of the immediate military response for homeland security, designated as Operation Noble Eagle, Army Dental Corps Oral Pathologists and support personnel from the Armed Forces Institute of Pathology (AFIP) were sent to Dover Air Force Base to participate in the identification of remains. Identification was accomplished through various means including matching antemortem dental records, fingerprints, bone analysis and DNA comparisons. Despite the closure of the Central Panograph Storage Facility in Monterey, California, panographs of many military victims were still on file at the facility. With commercial planes grounded, the Department of Defense dispatched these dental records cross-country by military aircraft. Panographs again proved to be a valuable comparison tool for making positive victim identification. Three weeks into the mission, dental identifications were performed in over 63% of the cases, and in 30% of the cases dental evidence served as the sole method of identification.

7 October 2001 – Operation Enduring Freedom, Afghanistan. The initial US military response to the 11 September 2001 terrorist attacks on the United States was assigned the name Operation Enduring Freedom (OEF). Having identified the Al Qaida terrorist organization as responsible for the September 11 attack, the US launched an offensive against this group and the extremist Taliban government of Afghanistan that harbored them. Dental support to OEF further taxed Army dental resources already spread thin by other worldwide requirements.

March 2002 – DENCOM began training of Expanded Function Dental Assistants (EFDA). In the post Sept 11, 2001 terrorist attack milieu of ramping up for increased military conflict while at the same time guided by Secretary of Defense Donald Rumsfeld’s DoD reorganization initiatives the Army Dental Care System (ADCS) was faced with the difficulty of preparing larger numbers of Soldiers for deployment with a shrinking pool of general dentists. Building on its previous

reengineering experience (the Dental Care Reengineering Initiative (DCRI)) the ADCS pursued a program to optimize dental care delivery and improve clinical efficiencies. Dental Care Optimization (DCO) is the name used for the updated reengineering efforts. After careful study of efficient delivery systems, DCO adopted, along with other best clinical practices, the use of multichair, multiancillary primary care teams led by general (AOC 63A) and/or comprehensive dentists (AOC 63B) and enhanced with dental assistants with advanced training. These Expanded Function Dental Assistants (EFDA) were selected from currently employed civilian dental assistants and provided advanced training, allowing them to perform reversible dental restorative and dental hygiene procedures. (See also 27 March 1972 entry concerning DTA, an earlier program to establish a dental personnel type with expanded function.)

1 May 2002 – President George W. Bush presented the Medal of Honor posthumously to CPT Ben L. Salomon, Dental Corps, for his “extraordinary heroism and devotion to duty” on 7 July 1944 during the campaign to capture the island of Saipan in the Mariana Islands. In the absence of living family members President Bush presented the award to representatives of the Army Dental Corps and the University of Southern California, Salomon’s dental school. Salomon is the only US Army Dental Corps Officer to be awarded the Medal of Honor. (See entry for 7 July 1944 and OTSG website <http://history.amedd.army.mil/moh/Salomon.html> for more details.)

1 August 2002 – Upon promotion to major general, Joseph G. Webb, Jr. officially became the 24th Chief, US Army Dental Corps. He also assumed the duties of Commanding General, Pacific Regional Medical Command, and Tripler Army Medical Center, TRICARE Pacific Lead Agent, and Commander (PROFIS) of the 18th MEDCOM. This marked the first time a dental officer was placed in command of an Army Medical Center (MEDCEN). Actual DC strength was 1001, with budgeted end strength of 1138. In June 2004 MG Webb became the US Army Deputy Surgeon General and was reassigned to the Surgeon General’s Office in Falls Church, VA.

#### **OPERATION IRAQI FREEDOM (2003 – 2010)**

Threatened by indications that Iraq had supported terrorism against the US and that Iraqi President Saddam Hussein possessed weapons of mass destruction which he would use against US interests, President George W. Bush first supported diplomacy through the United Nations, and also prepared for military operations in Iraq. The operations were referred to as Operation Iraqi Freedom (OIF), See 31 August 2010 for President Barack Obama’s declaration of the end of OIF.

#### **RAMPING UP TO WAR**

January 2003 – OIF dental support was initiated by processing (classification and treatment) of troops at 16 different active duty installations. In all, over 120,000 active and reserve Army forces were screened and treated for duty in Iraq and Kuwait.

17 January 2003 – The first Reserve Component, Installation Medical Support Units (IMSU) that provided dental support arrived at 15 different power projection platforms (PPPs) across the US. IMSU dentists augmented the capabilities DENTAC responsible for mobilizing US Army Reserve (USAR) and Army National Guard (ARNG) Soldiers for active service. In all, 75 dentists and 179 dental assistants from 21 IMSUs and one US Army Hospital (USAH) were activated. Dental officers were activated for 90-day rotations, with 30 eventually extending beyond their initial 90-day call-up.

February 2003 – The Reserve Component (RC), Individual Mobilization Augmentee (IMA) for the DENCOM Commander was placed on active duty to direct the use of RC dental assets within Continental US (CONUS).

March 2003 – Reserve Component (RC), Individual Mobilization Augmentee (IMA) dentists arrived at various Active Duty units to backfill for 55 deploying active duty DENCOM dentists. The active duty dentists were reassigned from their normal duty location by the Professional Filler System (PROFIS) Program to fill deploying units. In all, 17 IMAs activated for 90-day rotations, with 2 extending voluntarily beyond the initial 90 days. In mid-March an additional Six RC dentists activated from Installation Medical Support Units (IMSU).

20 March 2003, Invasion of Iraq – President George W. Bush gave the order to liberate Iraq from its corrupt dictator, Saddam Hussein, and his oppressive regime. Over 233,000 US Army Soldiers were deployed in support of Operation Iraqi Freedom (OIF).

In addition to dental support from dental personnel organic to deployed tactical units, Medical Companies (area support dental services) were also deployed. The 93rd Medical Battalion (Dental Service) from Heidelberg, Germany, commanded by COL (later major general) Russell J. Czerw, provided dental command and control to most of the dental companies in theater. In the early stages of OIF, elements of the 93rd supported V Corps and theater missions in Kuwait and Iraq.



## Highlights in the History of Army Dentistry

It is interesting to observe that the 93rd Med Bn served as a transition between earlier Medical Detachment AI dental command and control units (that existed from Vietnam War until the end of the Gulf War) to the multifunctional medical battalion concept implemented in 2007 as part of the Secretary of Defense's Transformation Planning Guidance. Although it was designated as a medical battalion (dental service), like the AI detachment was in earlier operations, the 93rd was task organized to also provide command and control to subordinate units with functions other than dental.

1 May 2003 – “Major military operations” of OIF ended, but operations to stabilize Iraq continued. Two AC units, 502nd and the 561st Medical Companies (Dental Service) remained in theater to provide area dental support after the redeployment of the 2 units with RC personnel, the 673rd and the 965th. Later other Med Co (DS) rotated into and out of Iraq to provide dental support to the stabilization phase of the Iraq war. One example is the 380th Med Co (DS) a Reserve Component unit from Millington, TN.

June – July 2003 – A second rotation of RC dentists were activated: 27 IMSU dentists to support mobilization platforms, 2 IMSU dentists and 2 US Army hospital dentists to support CONUS Replacement Center (CRC) missions, and 5 IMA dentists were activated to support continuing OIF mobilizations and demobilizations

July 2003 – First Term Dental Readiness (FTDR). Because of high operational tempo, first term Soldiers frequently deployed to areas of military operations soon after arrival at their first permanent duty station, leaving very little time for predeployment medical/dental processing. The US Army Medical Command and the US Army Training and Doctrine Command signed a memorandum of understanding in July 2003 to implement a First Term Dental Readiness pilot program at Army Advanced Individual Training (AIT) and one-station unit training (OSUT) sites. The pilot program began 1 October 2003 at Fort Sill, Oklahoma, and 1 November 2003 at Fort Knox, Kentucky. The goal of FTDR program is to have 95% of AIT graduates dentally ready to deploy when they arrive at their first permanent duty station.

October 2003 – Health Professions Loan Repayment Program (HPLRP). Dental officer recruitment and retention rates were severely and negatively affected by the overwhelming burden of dental school educational debt. With the intent to relieve this situation, the DENCOM initiated the Active Duty Health Professions Loan Repayment Program (HPLRP). The program provided payment of educational loans tied to securing a dental degree. Officers eligible for participation in this program must have between 18 months and 14 years of service as of 31 January 2004. Direct accessions and those with less than a 4-year Health Professions Scholarship Program (HPSP) scholarship were eligible for the HPLRP. There were no new starts in the HPLRP program in 2007, but the Dental Corps was included in the AMEDD Corporate HPLRP program, with emphasis on recruitment. Effective 1 April 2007, uncommitted HPLRP recruitment funds were reallocated as a retention tool.

10 July 2006 – COL Russell J. Czerw was promoted to major general and became the 25th Chief of the US Army Dental Corps. On 11 July he assumed the position of Commander, US Army Medical Department Center and School and Post Commander of Fort Sam Houston, Texas. When MG Czerw assumed the duties as Dental Corps Chief, budgeted Corps strength was 1,104, but the actual strength had declined into the lower 900s throughout FY06. As Corps Chief, MG Czerw made officer recruitment and retention his number one priority. He assigned a Dental Corps junior officer to the US Army Recruiting Command (USAREC) as assistant to the USAREC Dental Corps Program Manager, and to act as the command's personal subject matter expert regarding potential DC Corps accessions, and serve as liaison to dental schools and national/state/local dental entities. By FY10, Dental Corps recruiting missions were met and/or exceeded for Health Professions Scholarship students and Active Duty and Reserve Component Direct Accessions. In his role as Commander of Ft Sam Houston and the AMEDDC&S, MG Czerw was instrumental in coordinating actions dictated by the Base Closure and Realignment Committee. The major tasks in that responsibility were the creation of the Joint Medical Training Campus for all US military services' enlisted medical training, establishment of Joint Base San Antonio, and oversight of Ft Sam Houston installation infrastructure enhancements totaling more than \$2 billion.

26 August 2006 – 15 August 2007 US Army Reserve MG Ronald D. Silverman became the first dentist to command medical operations in a theater of combat operations. MG Silverman commanded 3rd Medical Command and Task Force 3 in Operation Iraqi Freedom. Task Force 3 was a multiservice medical force of more than 3,000 Soldiers assigned to 30+ medical units.

1 October 2006 – the Military Occupation Specialty (MOS) field 91E was recoded to be MOS 68E for all Dental Specialists. This new code includes 68E for Dental Specialist, 68EN5 for Dental Laboratory Specialist and 68EX2 for Preventive Dentistry Specialist.

15 March 2007 – The Chief, US Army Dental Corps approved the appointment of COL Priscilla Hamilton as the Deputy Chief of the US Army Dental Corps. COL Hamilton, who had been serving in the Corps Chief's office as the senior DC

Staff Officer, was the first person to occupy this new position. She later became the first woman to command the US Army Dental Command in August, 2010.

24 March 2010 – The US Army Dental and Trauma Research Detachment, US Navy Institute of Dental and Biomedical Research, and the US Air Force, Dental Evaluation and Consultation Service Detachment relocated from Great Lakes Naval Center near Chicago, IL to Fort Sam Houston, TX. The 3 military dental research units are collocated in a new 25,000 square foot facility, the Battlefield Health and Trauma Research Institute.

7 May 2010 – COL M. Ted Wong became the 26th Chief of the US Army Dental Corps. Promoted directly to major general, he was selected to serve as the Deputy Commanding General for Readiness, Western Regional Medical Command and the Commanding General for William Beaumont Army Medical Center at FT. Bliss, Texas. The actual Dental Corps strength when MG Wong became Chief of the Corps was 975 dental officers.

31 August 2010 – President Barack Obama announced the end of America's "combat role" in the 7½ year war in Iraq by withdrawing 90,000 troops. A transitional force of 50,000 troops remained, down from the peak of 170,000 in 2007. This new military phase in the Iraqi conflict is called "Operation New Dawn." Dental operations in Iraq were reduced proportionately to the reduction of force.

---

## REFERENCES


1. Jeffcott GF. *United States Army Dental Service in World War II*. Washington, DC: Office of The Surgeon General, US Dept of the Army; 1955.
2. Hyson JM. *The United States Military Academy Dental Service: A History 1825 – 1920*. West Point, New York: United States Military Academy; 1989.
3. Hyson JM Jr, Whitehorne J, Greenwood JT. *A History of Dentistry in the United States Army to World War II*. Washington, DC: Borden Institute, Office of the Surgeon General, US Dept of the Army; 2008.
4. King JE, Hynson RG. *Highlights in the History of US Army Dentistry, Year 2007*. Fort Sam Houston, TX: Office of Medical History, US Army Medical Dept; 2007. Available at: <http://history.amedd.army.mil/corps/dental/general/highlights/highlights.html>. Accessed October 15, 2010.

---

## AUTHORS

COL Passo is currently assigned to the Fort Knox Dental Activity as a Periodontist. He is also Consultant for Dental History to the Chief of the Army Dental Corps.

Before his retirement, COL (Ret) King was the Consultant for Dental History to the Chief of the Army Dental Corps. He continues active interest in promoting the use of history as an aid to management.



Unique requirements of military dental care include, but are not limited to, a high degree of mobility and ability to set-up quickly. This photo from World War I shows one of many ways Army dental officers adapted civilian dental equipment, Army-designed field dental equipment, and standard military vehicles for these capabilities.

# CAD/CAM Dentistry for Today's On-The-Go Military

COL Jeffrey A. Hodd, DC, USA

## INTRODUCTION

Computerized dentistry was introduced in 1980 when Dr Werner Mörmann of the University of Zurich, anticipating the attraction of restoring posterior teeth with tooth-colored materials, developed the bonded ceramic inlay technique while at the same time addressing the issue of fabricating the restorations using computer-aided design/computer-aided manufacturing (CAD/CAM). This technology would enable a dentist to complete one or multiple ceramic restorations (inlays, onlays, veneers, and full crowns) chairside in a single appointment. Currently, there are 4 CAD/CAM systems on the market designed for the ceramic restorative dental application: CEREC Acquisition Center (Sirona, Bensheim, Germany), E4D (D4D Technologies, Richardson, TX), Lava C.O.S. (3M ESPE, St. Paul, MN), and iTero (Cadent, Carlstadt, NJ). The CEREC system is the original and most-researched system on the market and has been used in the US Army Dental Command since 2003, and will therefore be the focus of this article. Following is a brief discussion of the evolution of CEREC and CAD/CAM, a review of the literature, a detailed explanation on the use of the current state of the art CEREC AC, and an examination of the benefits of CAD/CAM to the US Army dental mission.

On September 19, 1985, the first chairside ceramic inlay restoration was placed at the University of Zurich Dental School with the CEREC 1 CAD/CAM system (Sirona Dental Systems, Charlotte, NC). The concept that a machine-milled ceramic restoration could be fabricated chairside with the benefit of only one dental visit was revolutionary for restorative dentistry. Even so, the idea was initially met with skepticism among practicing dentists, raising questions on the viability of its future acceptance.<sup>1</sup>

The CEREC (ceramic reconstruction) system has evolved dramatically over the past 25 years, encompassing 3 generations of equipment and software since the introduction of CEREC 1, which offered only ceramic inlays and veneers, through CEREC 2 which included onlays and full crowns, up to the present-day CEREC 3 which offers enhanced capabilities designed to improve overall speed and accuracy. Through continuous research and development, there have been significant hardware and software changes to the original CEREC system (Figure 1). The separation of the milling chamber from the image capture and design hardware led to a significant improvement in clinical efficiency by allowing simultaneous design of one restoration while milling a second one. Form grinding of dental ceramics (milling units) changed from a less precise diamond grinding wheel, which required more clinical adjustment, to a more precise 2-bur system in 2006 with a reduced diameter at the tips allowing for a more optimal internal and external detail of the ceramic restoration. Later improvements to the computer's speed, size, and memory, along with the change from a 2-dimensional design program (CEREC 2 in 1994), to a 3-dimensional (3D) one (CEREC 3 in 2003), resulted in a more realistic virtual display for dentists to design restorations in a way that they were used to seeing with stone casts. The 3D design also allowed better work flow, and software tools enabled manipulation of the digital partial or full crown anatomy to the preparation, adjustment of the proximal contacts, and the ability to adjust the occlusion with the introduction of the antagonist tool to the opposing tooth contacts. In 2006, Mehl and Blanz<sup>2</sup> introduced a biogeneric model software database for inlays, onlays, and partial crowns. In 2010, the latest CEREC software (version 3.8) includes full crowns, eliminating the biomimetic crown database for full

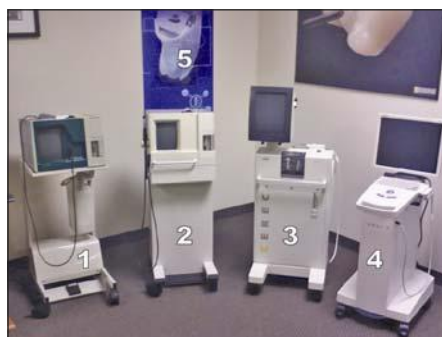

Figure 1. CEREC history:

1. Prototype
2. CEREC 1, 1987 (inlays, veneers)
3. CEREC 2, 1994 (onlays, crowns)
4. CEREC 3, 2000 (2003 3D)
5. CEREC AC, 2009



crowns. The biogeneric dynamic database, according to their research, looked at hundreds of caries-free and wear-free teeth as they scanned each individual tooth. The scans were completed at 100,000-point resolution per occlusal surface, capturing detailed anatomy. Using this database, average tooth characteristics were determined that encompass the statistical median of the population. During the biogeneric mathematical calculation, the average tooth shape is compared with the residual points on the surface of the tooth. Depending on the variance from the residual tooth structure to the average-shaped tooth, a final specific anatomy is proposed by the program. With full crowns, the software scans its neighboring teeth or an unrestored tooth in either dental arch to naturally reconstruct the occlusal surface while taking into consideration the antagonist (opposing) tooth. The end result is a more precise restoration with minimal to no adjustments intraorally.<sup>3</sup> In the most recent evolution, the CEREC Acquisition Center (AC) unit (Figure 2), has introduced a newly developed light-emitting diode camera (the Bluecam) that replaces the infrared-emitting camera from the CEREC Acquisition Unit system. The Bluecam features greater depth of field, higher precision, shorter acquisition times, an antishake feature, and automatic image capture.

As the CEREC hardware and software continued to improve, developments in ceramic materials ran in concert. The first ceramic material used for the CEREC 1 was the Mark I Vitablocs (Vident Zahnfabrik, Bad Säckingen, Germany) and has the longest clinical track record in the dental literature.<sup>4</sup> It was a fine-particle, feldspar-based ceramic that could be pressed into a block and then machined into a dental restoration. From 1987-1997, the Mark I was predominately replaced with the Mark II (Vident Zahnfabrik), a fine-grained, high-glass content, feldspar-based ceramic. Through continual development, and in order to keep pace with changes in the equipment, the materials became even stronger, and other companies joined the ranks, such as Ivoclar Vivadent, which developed the ProCAD block (Ivoclar Vivadent Inc, Amherst, NY) that was composed of 40% infiltrated leucite glass. Later, after several

modifications, ProCAD became Empress CAD. The use of ProCAD is also well documented in the dental literature.<sup>5</sup> Most recent developments include the lithium disilicate ceramic called IPS e-max CAD, that has a high flexural strength while maintaining its esthetics. In 2007, Sirona Dental Systems introduced their CEREC block which has properties similar to the Mark II block, but with its own shading nomenclature. All of the available blocks are offered in monochromatic or polychromatic form and can be stained and glazed to accommodate the desired esthetic effect.

### PROVEN TRACK RECORD OF CAD/CAM TECHNOLOGY

Regardless of the 25-year history of CAD/CAM in the dental office, it differs from traditional treatment and manufacturing methods and has been one of the most critically examined restorative dental technologies, despite its exceptional clinical performance. While there are 4 restorative dental CAD/CAM systems on the market today, all of the global clinical evidence-based literature regarding this technology pertains to CEREC. According to a recent PubMed\* search, there are 427 referenced articles for CEREC. The 5 most common areas discussed in the literature and among fellow dentists can be attributed to fit, longevity, strength, wear characteristics, and postoperative sensitivity.



Figure 2. Chairside CEREC AC, CEREC 3 Compact, and MCXL milling unit.

Marginal adaptation or fit varied through the 3 major generations of CEREC. Several authors have compared the marginal adaptation of the ceramic restoration to the prepared tooth by following thousands of patients and Mark I and II Vitablocs (Vident Zahnfabrik) restorations over the course of the CEREC evolution<sup>6-15</sup> The CEREC 1 and CEREC 2 technology on marginal gaps appeared to be significant with an approximate range between 200 and 300  $\mu$ m. With this increased gap, the resin-based composite cement would wear at the margin, leading to ditching along the tooth-restoration occlusal

\*PubMed, a service of the US National Library of Medicine, provides search access to the MEDLINE database of citations, abstracts, and some full text articles on life sciences and biomedical topics (<http://www.ncbi.nlm.nih.gov/pubmed>).

interface and minimal change at the interproximal tooth surfaces. Despite this clinically detectable discrepancy of the restoration, there was no evidence of secondary caries or microleakage, and, therefore, no clinical failure due to the margin wear. With the CEREC 3, marginal gaps significantly decreased; Nakamura and colleagues<sup>16</sup> reported a margin gap of 53 to 67  $\mu\text{m}$  for CEREC 3 crowns. The marginal gap with the CEREC 3 AC system continues to be consistent with these latter values.

Many advances in dental technology have taken place since the introduction of CEREC, and as CEREC has evolved, so have adhesive bonding techniques and methods. Several authors have validated the longevity of CEREC restorations. The Kaplan-Meier method survival probability was consistently 90% or greater at 10 years for many studies.<sup>6,12,17-24</sup> Ceramic fracture was the overwhelming primary reason for failure, followed by supporting tooth fracture. Ceramic fracture was thought to be a result of occlusal stress or insufficient ceramic thickness. Hickel and Manhart<sup>25</sup> reviewed clinical studies in the dental literature during the 1990s to determine annual failure rates of posterior restorations in stress-bearing areas. They found annual failure rates of cast gold inlays from 0% to 5.9%. For CAD/CAM, they found the annual failure rate to be 0% to 4.4%. CAD/CAM was slightly better than gold, which is often considered to be the gold standard. It is important to note that improvements in both CEREC technology and bonding techniques promise to produce even better results for restorations being placed today and in the future.

The fabrication of indirect all-ceramic restorations has proven to be a strong and reliable technique, and it is difficult to reproduce the exceptional strength and material composition through traditional fabrication means. CEREC materials are different in that they are industrially manufactured under controlled conditions and are presintered. This stringent guideline ensures that the ceramic blocks have consistent particle size, no porosity, and strength throughout the material. Combining the ability of adhesive technology and structurally reliable, industrially prepared ceramics, many authors<sup>6,8,9,11,12,25-30</sup> have reported a low level of restoration failure and low restoration fracture rates, making CEREC-generated restorations clinically durable and successful. The 2 major mechanisms for clinical failure for all other similar ceramic

restorations are ceramic fracture due to inadequate thickness of the ceramic material ( $<1.5$  mm) and tooth fracture due to the thin remaining walls of tooth structure ( $\leq 1$  mm). Bremer and Geurtsen<sup>31</sup> specifically looked at the fracture resistance of teeth following treatment with various types of adhesive restorations, and found there was no significant difference between the mean values of sound intact teeth (2,102 N) and the teeth with the CEREC ceramic inlay restorations (2,139 N).

Wear characteristics are always a concern for dentists when restoring teeth with various restoration types, since enamel is subject to different wear rates against different restorative materials. Therefore, the surface finish and microstructure of materials greatly influence enamel wear. CEREC ceramic restorations have among their qualities enamel-like wear characteristics due to the fine-grained particle size, absence of porosity, consistent manufacturer conditions, and uniform strength throughout the ceramic block. A number of studies show that CEREC materials level of tooth enamel wear essentially is equivalent to that of tooth enamel against tooth enamel if the surface is polished or glazed.<sup>32-35</sup> It is true that a machine-milled restoration alone decreases the strength of the ceramics. However, ceramics can be polished using rubber wheels of different coarseness and diamond paste to produce a surface that is superior to glazing, which brings the strength back to at least that of the premilled material. Furthermore, improvements in strength of about 160 MPa can be achieved by combining polishing and overglazing procedures with surface materials designed for these blocks. Al-Hiyasat and colleagues<sup>36</sup> investigated human enamel wear against 4 dental ceramics and gold and found that gold was the least abrasive material and most resistant to wear, although the difference in wear between the machinable ceramic and gold was not statistically significant. CEREC restorations are less abrasive to the opposing dentition than other restorative options.

The final attribute of CEREC restorations that is documented in the literature is postoperative sensitivity. Early clinical studies on CEREC-generated restorations reported significant levels of postoperative sensitivity. Several of these authors conveyed that most of the cases that involved sensitivity usually resolved within one month or less with no return in sensitivity. Some sensitivity issues were attributed to

the single appointment which resulted in occlusal interferences due to the technology at that time.<sup>6,17,37-39</sup> More recent studies have reported less postoperative sensitivity due to the advancement in adhesive materials, luting technique, and the addition of occlusion-adjustment capability in the software. These authors found that there were no sensitivity issues at the standard recall appointments of the patients during the 3 to 5 years studied. This lack of postoperative sensitivity in chairside CAD/CAM restorations can be attributed to careful isolation techniques such as the Isolite system (Isolite Systems, Santa Barbara, CA) which provides upper and lower suction, tongue and cheek retraction, light illumination, and mouth prop stabilization support. When acquiring an optical image of the preparation, good isolation techniques ensures the preparation, powdering, and the picture are all in concert with one another, which ultimately allows for a more predictable outcome with the luting process. The ability to deliver the restoration in a single appointment also prevents the potential for tooth contamination due to a possible poor fitting, leaking, or loss of the provisional restoration as seen in conventional crown fabrication techniques.<sup>7,40</sup> In summary, the evidence-based literature showed support for using the CEREC system in all of the primary areas of consideration when evaluating the efficacy of a restorative dental technology.

#### **CEREC ACQUISITION CENTER: STATE OF THE ART DENTAL INTERFACE**

Today, the state of the art CAD/CAM chairside equipment is the CEREC AC. The CEREC AC is designed to interface optimally with dental practice workflow while providing the most comprehensive array of CAD/CAM solutions, high level of digital impression precision and efficiency. The CEREC AC is easy to use and is powered by the short wavelength, lightweight Bluecam camera which offers an extensive depth of field, access to difficult areas intraorally, and the ability to acquire razor-sharp, 3-dimensional optical impression images of the prepared tooth and the antagonist (opposing tooth surface). A half-arch digital impression can be captured in 40 seconds, and a full-arch digital impression can be captured in 2 minutes. The high resolution of the produced virtual model has benchmarks that are approaching those established with laboratory scanners.<sup>41</sup> The CEREC AC also provides a convenient reserve battery pack, enabling the machine to move from operatory to

operatory without powering down. This is especially beneficial when there are multiple dentists in the clinic using the machine in the same day. The CEREC AC occupies minimal floor space, has a large 19-inch monitor, and a refined keyboard for optimal ergonomics and efficiency. The newest software for the CEREC AC is version 3.8. The patented Biogeneric software technology offers sophisticated restoration design and superb functionality. Using the patient's natural tooth structure as a basis, the software automatically creates perfect anatomical form for any single partial-coverage or full coverage tooth restoration. In the case of inlay and onlay restorations, the biogeneric software uses the residual occlusal structure surrounding the cavity of the prepared tooth. In the case of crowns, the user creates digital impressions of the preparation and a further intact tooth, preferably the antagonist, adjacent tooth, or the contralateral tooth to generate a matching restoration proposal. Scientific analysis demonstrates that the restoration proposal closely reproduces the original occlusal surface that is unique to that specific patient. The clinical applications of the CEREC AC allows the dentist to create esthetic, efficiently produced, all-ceramic inlays, onlays, veneers, and crowns with several ceramic block options available on the market today. Now with in-office fabrication of these restorations, there is little need to use an outside laboratory unless the dentist wants to send a digital impression via CEREC Connect, and have a stereolithography 3-dimensional model fabricated from Sirona and the final restoration fabricated from a CEREC dental laboratory.

#### **PREPARATION, POWDER, PICTURE AND WORKFLOW**

In order for the CEREC AC process to be successful, the dentist needs to acquire the proper training and practice in order to get past the learning curve that is to be expected with any new technology. Additionally, the dentist must incorporate sound clinical dentistry principles regarding case selection, preparation guidelines, intraoral isolation techniques, and an understanding of adhesive dentistry parameters. The fundamentals of CEREC dentistry can be summed up with the "3 Ps": preparation, powder, and picture for optimal clinical success. The preparation geometries and reduction parameters are specific for each type of restoration. The proper tooth reduction of all-ceramic restorations allows for adequate thickness of the ceramic material in order to prevent a potential



fracture of the restoration, but the overall reduction of the tooth is equivalent to a metal-ceramic restoration. The all-ceramic preparation must have the appropriate wall taper, as well as smooth and rounded surfaces to reduce any internal stress or microfractures of the ceramic material. As compared to traditional crown preparation guidelines of sharp, retentive, and resistive tooth form features, the all-ceramic crown preparation is usually devoid of these sharp angles, grooves, and boxes, and solely relies on adhesion to the enamel and dentin.<sup>42</sup> This is not to say, however, that the dentist should ignore the importance of having an appropriate amount of surface area to gain an achievable bond to the remaining tooth surfaces. Bindl and colleagues<sup>43</sup> studied classic, reduced, and endodontic crown preparations for premolars and crowns. They found that classic and reduced crowns had similar survival rates, but the endodontic crowns were acceptable only for molars. They attributed the success of the reduced crown preparations compared to the classic crown preparations to the adhesive luting technique used with the ceramic block material.

The workflow for acquiring and designing a full crown restoration on the CEREC AC is effortless with on-screen instructions that guide the dentist through each phase of the CEREC process. Once the preparation is complete, the dentist can further evaluate it by taking an optical digital image to evaluate the preparation criteria, adjacent proximal contacts, and marginal assessment on the large monitor, and then refine the tooth as necessary. Again, the accuracy of the software design is limited to the accuracy of the data imported into it, and it all starts with good tooth preparation. Occasionally, preparation margins are subgingival and are difficult to image. A diode laser or electrosurgery instrumentation can assist in the retraction of the gingival tissues to reveal all tooth margins to the camera clearly. Once the preparation is satisfactory, the dentist will take additional digital images of the preparation to form a working model, but first a light blue film of reflective powder (Optispray, Sirona Dental Systems) is applied to the surfaces of the preparation and the surrounding teeth to be recorded. The Optispray is quick, effective, and hygienic. The homogenous coating enhances the imaging capabilities of the CEREC Bluecam, especially with regard to the preparation margins. The CEREC Optispray is water soluble and easy to irrigate off the tooth and soft tissue surfaces once the virtual model is rendered.

The CEREC AC Bluecam camera has the capability to take pictures automatically within the specified 14 mm focal range. When holding the camera over the tooth surface, the camera automatically detects the right moment to trigger the exposure, whether it is directly on the tooth surface or slightly above the tooth surface. In both cases, the parallel light beam ensures an optimum depth of field as well as a high level of handling flexibility. The camera's blue light illuminates the treatment site and offers a built-in, antishake system, combined with a short capture time, to ensure that images are acquired only when the camera is absolutely still. The CEREC software automatically eliminates any substandard images.<sup>44</sup> To further capture additional images, all the dentist must do is move the camera in a mesial or distal direction over the relevant areas to capture the digital images required (usually 5 or less) for the working virtual model. It takes less than a minute to make optical impressions for the preparation and antagonist, provided you have a proper application of reflective blue spray and excellent isolation technique.

The virtual model is usually constructed in 60 to 90 seconds due to the improved software algorithms. The CEREC AC articulates the opposing arches in 2 ways. The first involves the use of a negative image of a bite registration material such as Virtual CADbite registration (Ivoclar Vivadent Inc, Amherst, NY) to produce a virtual working opposing model, thereby eliminating the need to scan the opposite arch separately. The second is by scanning both arches separately and then acquiring a third (Buccal) scan with both arches together in maximum intercuspation. The camera is positioned parallel to the buccal surfaces of the teeth and at least one or 2 images are sufficient to correctly articulate the maxillary and mandibular arches to a virtual articulated model. An advantage to this second method is that the model can be virtually opened to confirm the virtual occlusal contacts and the preoperative clinical patient occlusal contacts prior to the delivery of anesthetic. The next step in the workflow process is to virtually trim the model in order to view the proximal tooth surfaces during the design process. Next, the preparation margin is marked using the automatic margin finder. For those difficult regions, the manual mode option is available to highlight the difficult area in a grayscale view. This mode is less precise and should only be used in limited circumstances. The next step is to

establish the insertion axis for the proposed restoration. Any visible yellow color along the preparation indicates an undercut or undesirable insertion axis and should be reorientated as necessary by eliminating all the visible yellow color. A biogeneric restoration will be proposed according to the patient's own signature morphology. Restoration proposals generally require minimal editing by using the position, rotate, edit, scale, shape, form, and drop tools provided by the software. The dentist can often design the entire restoration within 5 to 7 minutes due to the proprietary biogeneric technology.<sup>3</sup>

The CEREC AC software has additional design features to give the dentist more design options in simple and in more complex treatment cases. The "correlation" option allows the dentist to copy information from a diagnostic wax-up for a more desirable occlusal relationship or from parts of the patient's natural remaining tooth structure. Examples of these two options include cases involving multiple restorations either in the anterior or posterior regions to include full-mouth rehabilitation or if a patient should fracture a cusp and there is sound intact tooth structure remaining to copy. The software simply takes the digital impression of the copied information and constructs an exact copied proposal which can then be superimposed and altered as necessary using the editing tools. The "Biogeneric Reference" option allows the dentist to either mirror the adjacent tooth, such as restoring an anterior tooth #8 and taking the mirror image of #9, or select an intact contralateral tooth, such as restoring #3 and copying reference data from tooth #14, or use some other intact tooth in the arch to aid in the proper biogeneric design. The "Articulation" option allows the dentist to consider information from a dynamic bite registration if the patient's occlusal scheme was in unilateral balanced articulation. The proposed restoration can now be adjusted with the editing tools through the virtual bite registration in order to eliminate any unwanted occlusal interferences.

Once the restoration design is physically completed, the dentist chooses a restorative material that best accommodates the patient's treatment situation. The advantage of the CEREC AC is that it is the only system capable of making use of all of the available materials on the market. The dentist can satisfy most esthetic situations by choosing either monochromatic or polychromatic blocks that are available through

Sirona, Vita, and Ivoclar Vivadent dental companies. The polychromatic or multiblocks have a built-in gradient effect with different levels of translucency to mimic most teeth provided that there is no underlying condition such as metal post and cores that would influence the value of the restoration. All of these materials can be stained and glazed to best meet the patient's esthetic needs. Once the appropriate block is chosen to match the patient's dentition, the dentist can begin milling the restoration by using the CEREC MC XL or CEREC 3 compact units. Simply place the block in the chuck, tighten in place, and press the start button. The milling unit has 2 diamonds, one flat ended and one tapered at the end to shape the final restoration with minimal damage to the ceramic block. The burs are cooled constantly with ports of a sprayed water and oil mixture. The MC XL is extremely quiet, has colored illumination in the milling chamber to indicate the milling status, and has a precision milling range of  $\pm 25 \mu\text{m}$ .

After only a few minutes, the final restoration is completely milled to the designed specifications. The dentist can now retrieve it from the milling chamber and perform a trial fit by applying a luting try-in gel cement color for verification on the restoration. Next, the dentist will use surface finishing techniques to refine the milled restoration by using impregnated polishing points, disc, and polishing paste with a stiff bristle brush to bring the restoration to a smooth finish. Alternately, in less than 20 minutes, the dentist can characterize the restoration even further by using a staining and glazing process in the dental laboratory or office to accommodate demanding esthetic situations. Lastly, the dentist will prepare the porcelain surface with a hydrofluoric acid gel solution, rinse, dry, and apply a silane coupling agent for the adhesive resin cement. The tooth is etched, primed, bonded, and the restoration is cemented with an acceptable ceramic resin luting medium, the excess cement is removed with fine-course diamonds, and the restoration receives a final polish intraorally. The end result is a reliable, predictable esthetic restoration, and, most of all, a happy patient.

#### **BENEFITS TO THE MILITARY DENTAL PRACTICE**

It is safe to say that CAD/CAM dentistry is here to stay. With its improved ease of use, it is becoming increasingly popular in practice, with a corresponding influx of additional systems entering the market

including E4D, Lava C.O.S., and iTero. The CEREC AC and the E4D are the only 2 systems with chairside milling capability. The Lava and iTero systems require the digital impression to be sent to an outside source. The overall approach to CAD/CAM technology and the decisions that surround each restoration option have become easier and more predictable through improvements in milling software, innovative restoration design options, and the array of ceramic material selection.

As with most technology, the patient plays a major role in how the dentist chooses to practice dentistry. Most patients today live a busy lifestyle with competing demands for their time. This also holds true for our active duty military population; additional time spent in the dental chair is not typically a priority or always possible. The main advantage of using CAD/CAM technology is the concept of having the patient come in for only a "single appointment" to prepare the tooth, make an optical impression, design, mill, and customize the final restoration, a process that would normally require multiple visits. This concept is very appealing to most dentists and patients, and has numerous time-saving benefits for the military dental practice, including a single administration of anesthetic, no retraction cord packing, no final impression material, no provisional restoration, and, depending on the system in use, no outside laboratory costs or turnaround time. The initial startup cost of the equipment is significant; however, the return on investment is realized by the savings from lower CAD/CAM operating material costs over time. The dentist must fabricate a minimum of 20 restorations per month to be cost effective. The average CEREC crown fabrication cost is approximately \$30, compared to a traditional metal-ceramic crown at \$200. Most single-unit restorations can be completed in 60 to 90 minutes. As the dentist's confidence increases, the treatment of quadrants and complete dental arches can be completed either at the dental chair or in the dental laboratory on traditional casts. In the laboratory, the technician can apply the same concepts from the dentist working intraorally and now indirectly fabricate the restorations on the mounted articulated dental casts.

A primary mission for the Army Dental Corps is First Term Dental Readiness. Why? Getting our Soldiers "war ready" is the primary objective of all dental team members in order to reduce avoidable dental emergencies for Soldiers who are deployed in a war

zone. CAD/CAM is an extremely useful tool for accomplishing dental readiness in an efficient manner with high quality results. Following are two cases that highlight this treatment efficiency where traditional methods would have failed to deliver a completed treatment plan, given the time constraints involved. Case 1 is a more traditional application of the CAD/CAM technology. Case 2 is an example of the technology used for full-mouth reconstruction. Both cases were completed by prosthodontic residents and the author at Fort Gordon, Georgia, using the CEREC AC and MC XL milling CAD/CAM equipment.

### Case 1

An Active Duty 19-year-old Soldier was referred to the Tingay Dental Clinic Endodontic Department for a symptomatic tooth #30 (Figures 3 and 4). Clinically, tooth #30 had a large coronal amalgam restoration. The patient's occlusion was in cross-articulation (cross-bite) and the oral hygiene was fair. The patient was due to deploy in 2 days. The traditional treatment plan would be to do a cuspal coverage amalgam after the root canal was completed, however, the patient's occlusal scheme presented something of a dilemma. If a cuspal amalgam was to be placed, most dentists would struggle to maintain the patient's current occlusion and probably place the restoration out of occlusion and below the occlusal plane to prevent fracture of the freshly placed amalgam. However, with CEREC the dentist can now reconstruct the patient's current tooth morphology and maintain a harmonious situation that accommodates that particular patient's needs. In this case, the dentist prepared the tooth and the pulp chamber to accommodate a combined core and crown restoration, often referred to as an endo crown<sup>43</sup> (Figure 5). The dentist chose to design the restoration in correlation mode, thereby copying the tooth from a diagnostic wax-up of tooth #30 to mimic what was present prior to treatment (Figure 6). Once the design was completed, the restoration was milled, fitted, finished, polished, and cemented (Figure 7). The preoperative and postoperative photos, Figures 8 and 9 respectively, confirm an exact replica of the tooth morphology and occlusion of tooth #30. The patient was now in a stable, deployable status after a single visit (Figure 10).

### Case 2

An Active Duty 23-year-old Soldier was referred to the Tingay Dental Clinic Endodontic and



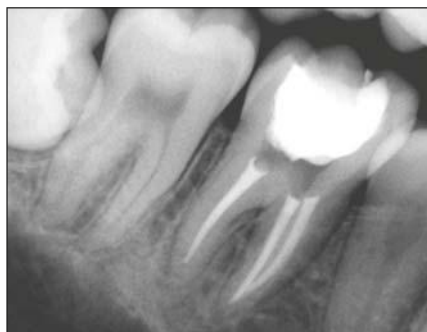

Figure 3. Tooth #30 preoperative periapical radiograph, post endodontic treatment.

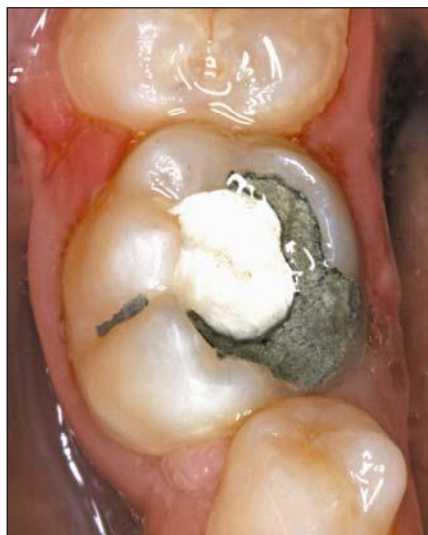

Figure 4. Tooth #30 clinical occlusal view, post endodontic treatment.

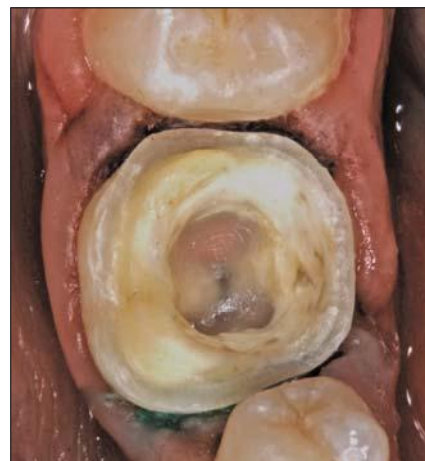

Figure 5. Tooth #30 endo crown preparation.

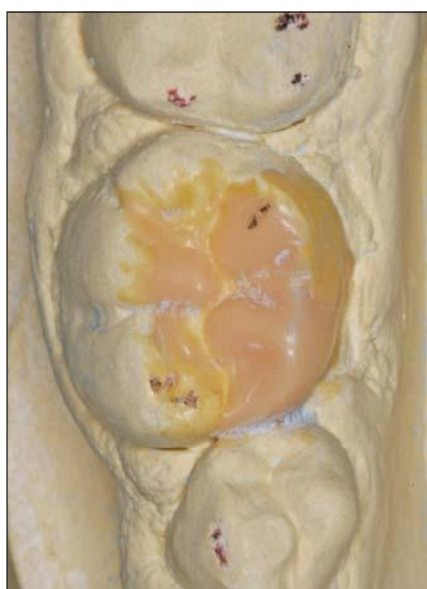


Figure 6. Tooth #30 diagnostic wax-up for the correlation mode design.

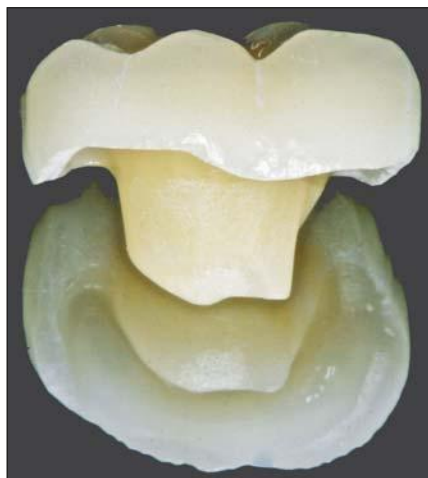

Figure 7. Tooth #30 final milled and polished ceramic endo crown prior to cementation (Sirona's multicolor ceramic block).

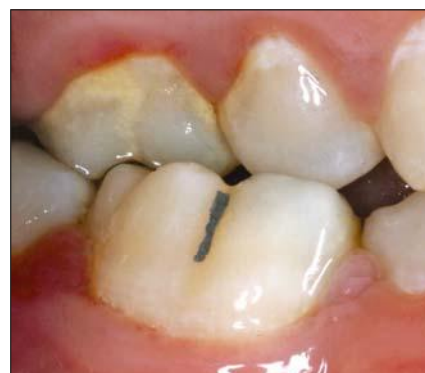

Figure 8. Tooth #30 preoperative buccal view.

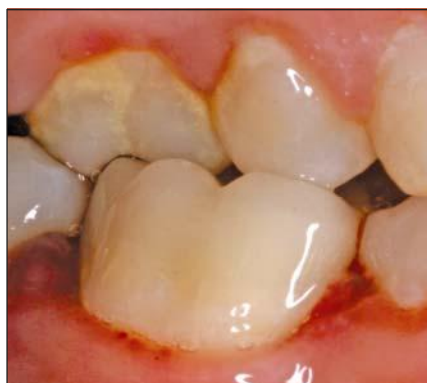

Figure 9. Tooth #30 postoperative buccal view.

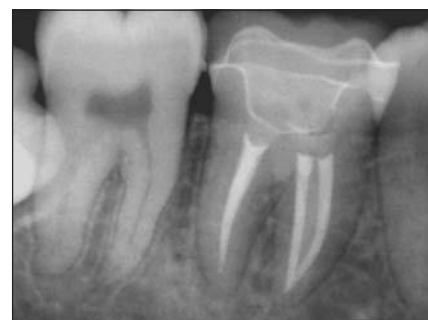

Figure 10. Tooth #30 postoperative periapical radiograph, final ceramic restoration.

Prosthodontic departments for a comprehensive evaluation. The patient presented with a suspected generalized enamel defect and a past history of drug abuse prior to entering active duty. Due to the weak enamel surfaces, multiple carious, and defective restorations were present along with a debilitated occlusion. Several teeth were symptomatic and the hygiene was poor (Figure 11). The patient was due to deploy in 7 months. The patient was assigned to a first-year prosthodontic resident for a complete examination and a definitive treatment plan. After gathering all the baseline data, full-mouth radiographs, and diagnostic casts, a diagnostic wax-up was

prepared to determine a viable treatment plan. Despite the generalized breakdown of the dentition, the patient advocated that he was interested in keeping all of his remaining teeth if possible. It was determined that the patient needed some immediate endodontic therapy for several teeth, oral hygiene instructions, diet counseling, soft tissue debridement, 4 posterior quadrants of crown lengthening procedures to gain an acceptable clinical crown height due to the level of prior tooth destruction, multiple prefabricated dowel and cores, and 28 CEREC all-ceramic restorations using the IPS e-max (Ivoclar Vivadent, Amherst, NY) CAD (lithium disilicate) material (Figure 12).

The milled lithium disilicate block must undergo a 2-stage crystallization process before cementation. The first stage is the “blue-violet block” precrystallized state. At this stage the glass ceramic has a crystal size range of 0.2 to 1.0  $\mu\text{m}$ , with approximately 40% lithium metasilicate crystals by volume. This precrystallized state allows the block to be milled easily without excessive diamond bur wear and damage to the material. The final crystallization occurs after the crown has been milled to the desired form and then crystallized in a porcelain oven at 850°C in a vacuum. The metasilicate crystal phase is dissolved completely and the lithium disilicate crystallizes. During this process, the blue color gets converted to the selected tooth shade and results in a glass ceramic with a fine-grained size of approximately 1.5  $\mu\text{m}$  and a 70% crystal volume in a glass matrix. The end result is an enhanced strength monolithic restoration that has a flexural strength of 360 MPa, which is approximately 2½ times greater than the other feldspathic monolithic block materials available. An advantage in using a monolithic (one-piece) material is that it helps prevent possible chipping, fracture, or delamination of the veneering porcelain as seen occasionally in a bilayered ceramic crown.<sup>45-48</sup>

Many dentists may consider this case to be impossible even with CEREC, but I decided that my extensive experience with both prosthodontics and CAD/CAM systems was up to the challenge. The prosthodontic resident and I developed a timeline for all required treatment to be accomplished in the short period of time available. The CEREC AC system was used to fabricate 22 full-contour lithium disilicate ceramic crowns and 6 ceramic veneers in the laboratory on articulated master casts. The diagnostic wax-up was systematically constructed to a more harmonious, functional situation, and the correlation mode of design was the optimal choice to copy the diagnostic wax-up “blueprint” information (Figure 13). With the new CEREC Bluecam camera and the more sophisticated software, detailed digital impressions were made from both the tooth preparation master casts and the duplicated diagnostic wax-up stone cast (Figure 14). They were then superimposed in the design process and minor adjustments were made using the software editing tools. After the milling process was completed for each of the ceramic restorations, they were fitted to the master cast to verify contours, interproximal, and occlusal contacts. All restorations were custom stained and glazed in the precrystallized state and then fully crystallized in the porcelain oven at 850°C in a vacuum (Figure 15). The full-mouth rehabilitation case was completed in a segmental fashion, and all ceramic restorations were cemented and followed normal bonded-ceramic protocol (Figure 16). The patient was followed for 2 weeks before his deployment and he was asymptomatic. The patient is scheduled to return after his one-year deployment to assess and evaluate the possibility of replacing the mandibular anterior veneers to full-coverage restorations. Ultimately, the patient endured a lot of treatment in a short window of available time, but the end result proved to be worth the effort (Figures 17 and 18).

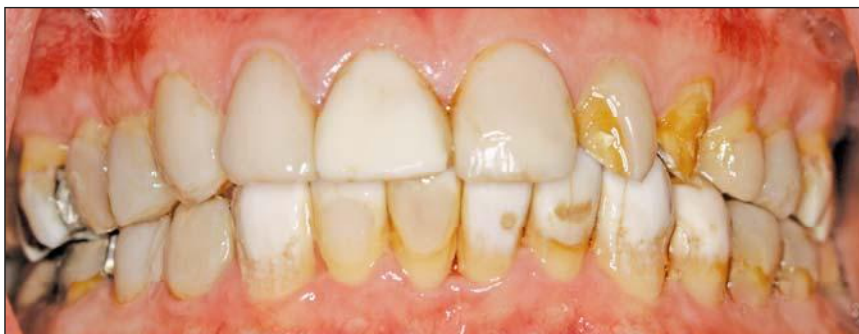

Figure 11. Case 2 preoperative frontal view.

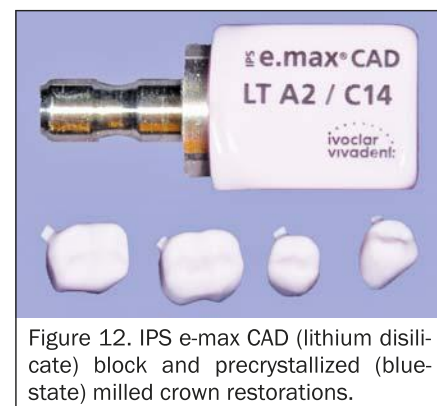


Figure 12. IPS e-max CAD (lithium disilicate) block and precrystallized (blue-state) milled crown restorations.



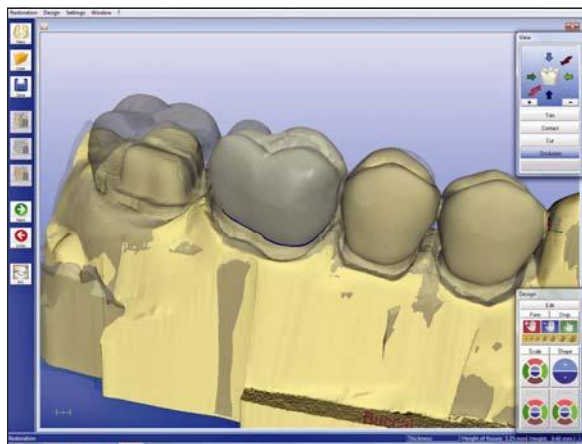


Figure 13. CEREC AC software correlation mode of the proposed restoration from the diagnostic wax-up.

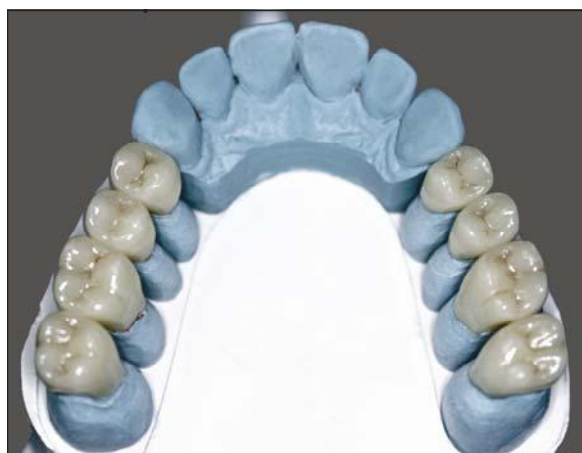

Figure 15. Maxillary master cast with final crystallization, staining, and glazing of the restorations.

## CONCLUSION

CAD/CAM systems like the CEREC AC have given Army Dental Corps professionals almost unlimited potential to reliably and efficiently fabricate chairside ceramic restorations in the military dental environment. Currently, there are approximately 30 chairside CEREC and other systems distributed throughout the Army Dental Command Regions. This technology is a viable tool because over the past 25 years CAD/CAM dentistry has proven to be an esthetically pleasing, effective, time saving, and cost effective approach to everyday dentistry restorative options. As we have seen through the progression of dentistry over the years, several dental techniques of the past, such as gold foil restorations, have become a lost art. As technology continues to progress, traditional

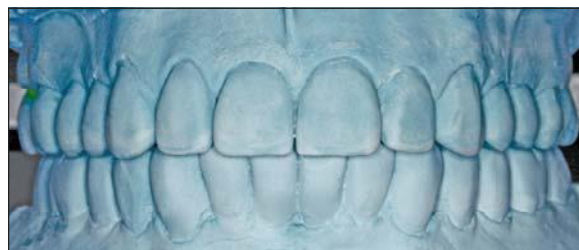

Figure 14. Diagnostic wax-up duplicated in dental stone. The blueprint for the final restorations.

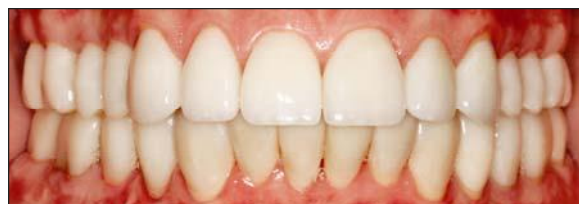

Figure 16. Postoperative frontal view.

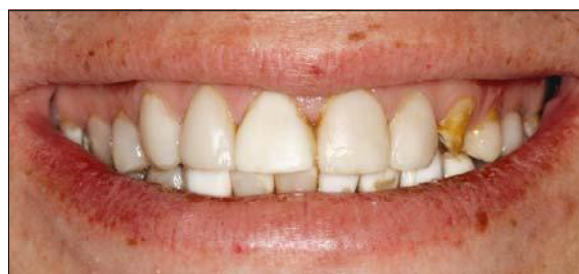

Figure 17. Preoperative smile.

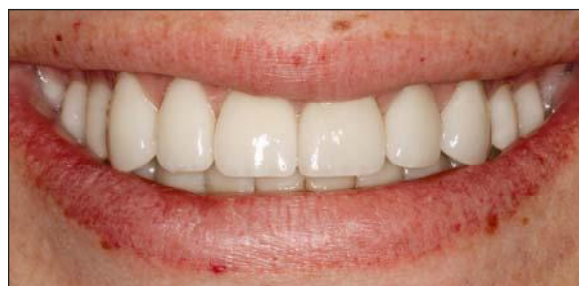

Figure 18. Postoperative smile.

impression techniques may become the new lost art as digital capabilities become the norm. Time will tell. Further, the Army Dental Corps can only benefit from the introduction of new companies and systems into the mix, providing a choice for the system that best serves the military dental practice. The next 5 years in CAD/CAM dentistry will surely be a roller coaster on which you will want to be riding. Now is an incredible time to be practicing dentistry!



## REFERENCES

1. Mörmann WH. The evolution of the CEREC system. *JADA*. 2006;137(9suppl):7S-13S.
2. Mehl A, Blanz V, Hickel R. A new mathematical process for the calculation of average forms of teeth. *J Prosthet Dent*. 2005;94(6):561-566.
3. Mehl A, Blanz V. New procedure for fully automatic occlusal surface reconstruction by means of a biogeneric tooth model. *Int J Comput Dent*. 2005;8(1):13-25.
4. Fasbinder DJ. Clinical performance of chairside CAD/CAM restorations. *JADA*. 2006;137(9 suppl):22S-31S.
5. Fradeani M, Redemagni M. An 11-year clinical evaluation of leucite-reinforced glass-ceramic crowns: a retrospective study. *Quintessence Int*. 2002;33(7):503-510.
6. Otto T, De Nisco S. Computer-aided direct ceramic restorations: a 10-year prospective clinical study of CEREC CAD/CAM inlays and onlays. *Int J Prosthodont*. 2002;15(2):122-128.
7. Heymann HO, Bayne SC, Sturdevant JR, Wilder AD, Robertson TM. The clinical performance of CAD/CAM-generated ceramic inlays: a four-year study. *JADA*. 1996;127:1171-1181.
8. Fasbinder DJ, Dennison JB, Heys DR, Lampe K. The clinical performance of CAD/CAM-generated composite inlays. *JADA*. 2005;136:1714-1723.
9. Isenberg BP, Essig ME, Leinfelder KF. Three-year clinical evaluation of CAD/CAM restorations. *J Esthet Dent*. 1992;4(5):173-176.
10. Gladys S, Van Meerbeek B, Inokoshi S, et al. Clinical and semiquantitative marginal analysis of four tooth-colored inlay systems at 3 years. *J Dent*. 1995;23:329-338.
11. Berg NG, Derand T. A 5-year evaluation of ceramic inlays (CEREC). *Swed Dent J*. 1997;21:121-127.
12. Posselt A, Kerschbaum T. Longevity of 2328 chairside CEREC inlays and onlays. *Int J Comput Dent*. 2003;6:231-248.
13. Bindl A, Mörmann WH. Clinical and SEM evaluation of all-ceramic chair-side CAD/CAM-generated partial crowns. *Eur J Oral Sci*. 2003;111(2):163-169.
14. Mörmann WH, Schug J. Grinding precision and accuracy of fit of CEREC 2 CAD-CIM inlays. *JADA*. 1997;128:47-53.
15. Denissen H, Dozic A, van der Zel J, van Waas M. Marginal fit and short-term clinical performance of porcelain-venerred CICERO, CEREC, and procera onlays. *J Prosthet Dent*. 2000;84:506-513.
16. Nakamura T, Dei N, Kojima T, Waabayashi K. Marginal and internal fit of CEREC 3 CAD/CAM all-ceramic crowns. *Int J Prosthodont*. 2003;16:244-248.
17. Sjögren G, Bergman M, Molin M, Bessing C. A clinical examination of ceramic (CEREC) inlays. *Acta Odontol Scand*. 1992;50(3):171-178.
18. Brauner AW, Bieniek KW. Seven years of clinical experience with the CEREC inlay system. In: Mörmann WD, ed. *CAD/CIM in Aesthetic Dentistry: CEREC 10 Year Anniversary Symposium*. Chicago, Illinois: Quintessence Publishing; 1996:217-228.
19. Sjögren G, Molin M, van Dijken JW. A 5-year clinical evaluation of ceramic inlays (CEREC) cemented with a dual-cured or chemically cured resin composite luting agent. *Acta Odont Scand*. 1998;56:263-267.
20. Reiss B, Walther W. Clinical long-term results and 10-year Kaplan-Meier analysis of CEREC restorations. *Int J Comput Dent*. 2000;3(1):9-23.
21. Sjögren G, Molin M, van Dijken JW. A 10-year prospective evaluation of CAD/CAM-manufactured (CEREC) ceramic inlays cemented with a chemically cured or dual-cured resin composite. *Int J Prosthodont*. 2004;17:241-246.
22. Reiss B. Clinical results of CEREC inlays in a dental practice over a period of 18 years. *Int J Comput Dent*. 2006;9(1):11-22.
23. Martin N, Jedynekiewicz NM. Clinical performance of CEREC ceramic inlays: a systematic review. *Dent Mater*. 1999;15(1):54-61.
24. Reiss B, Walther W. Survival analysis and clinical evaluation of CEREC restorations in a private practice In: Mörmann WH, ed. *International Symposium on Computer Restorations: State of the art of the CEREC method*. Chicago, Illinois: Quintessence Publishing; 1991:215.
25. Hickel R, Manhart J. Longevity of restorations in posterior teeth and reasons for failure. *J Adhes Dent*. 2001;3:45-64.
26. Mehl A, Kunzelmann KH, Folwaczny M, Hickel R. Stabilization effects of CAD/CAM ceramic restorations in extended MOD cavities. *J Adhes Dent*. 2004;6(3):239-245.
27. Tinschert J, Zvez D, Marx R, Anusavice KJ. Structural reliability of alumina-, feldspar-, leucite-, mica-, and zirconia-based ceramics. *J Dent*. 2000;28(7):529-535.
28. Chen HY, Hickel R, Setcos JC, Kunzelmann KH. Effects of surface finish and fatigue testing on the fracture strength of CAD/CAM and pressed-ceramic crowns. *J Prosthet Dent*. 1999;82(4):468-475.

29. Mörmann WH, Gotsch T, Krejci I, Lutz F, Barbakow F. Clinical status of 94 CEREC ceramic inlays after 3 years in situ. In: Mörmann WH, ed. *International Symposium on Computer Restorations: State of the art of the CEREC method*. Chicago, Illinois: Quintessence Publishing; 1991:355.
30. Palleson U, van Dijken JW. An 8-year evaluation of sintered ceramic and glass ceramic inlays processed by the CEREC/CAM system. *Eur J Oral Sci*. 2000;108:239-246.
31. Bremer BD, Geurtsen W. Molar fracture resistance after adhesive restoration with ceramic inlays or resin-based composites. *Am J Dent*. 2001;14(4):216-220.
32. Krejci I, Lutz F, Reimer M. Wear of CAD/CAM ceramic inlays: restorations, opposing cusps, and luting cements. *Quintessence Int*. 1994;25(3):199-207.
33. Abozenada B, Pober R, Giordano R. In-vitro wear of restorative dental materials. Paper presented at: The IADR/AADR/CADR 80th General Session; March 8, 2002; San Diego, CA. Available at: [http://iadr.confex.com/iadr/2002SanDiego/techprogram/abstract\\_13523.htm](http://iadr.confex.com/iadr/2002SanDiego/techprogram/abstract_13523.htm). Accessed May 24, 2006.
34. McLaren E, Abuzenada B, Pober R, Giordano R. Material testing and layering techniques of a new two-phase all-ceramic glass veneering porcelain for bonded porcelain and high-alumina frameworks. *Quintessence Dent Technol*. 2003;26:1-13.
35. McLaren E, Giordano R. Zirconia-based ceramics: material properties, esthetics, and layering techniques of new veneering porcelain, VM9, high-alumina frameworks. *Quintessence Dent Technol*. 2005;28:1-12.
36. Al-Hiyasat AS, Saunders WP, Sharkey SW, Smith GM, Gilmour WH. Investigation of human enamel wear against four dental ceramics and gold. *J Dent*. 1998;26(5-6):487-495.
37. Magnuson D, Oden A, Krystek I. Clinical evaluation of CEREC restorations. In: Mörmann WH, ed. *International Symposium on Computer Restorations: State of the art of the CEREC method*. Chicago, Illinois: Quintessence Publishing; 1991:339.
38. Fasbinder DJ, Lampe K, Dennison JB, Peters MC, Nematollahi K. Clinical performance of CAD/CIM generated ceramic onlays (abstract 2711). *J Dent Res*. 1999;78(special issue):444.
39. Otto T. Experience with CEREC in a Swiss practice. In: Mörmann WH, ed. *CAD/CIM in Aesthetic Dentistry: CEREC 10 Year Anniversary Symposium*. Chicago, Illinois: Quintessence Publishing; 1996:601.
40. Molin MK, Karisson SL. A randomized 5-year clinical evaluation of 3 ceramic inlay systems. *Int J Prosthodont*. 2000;13(3):194-200.
41. Mehl A, Ender A, Mörmann W, Attin T. Accuracy testing of a new intraoral 3D camera. *Int J Comput Dent*. 2009;12(1):11-28.
42. *IPS Empress CAD Instructions for Use Chairside*. Amherst, NY: Ivoclar Vivadent; 2006.
43. Bindl A, Richter B, Mörmann WH. Survival of ceramic computer-aided design/manufacturing crowns bonded to preparations with reduced macroretention geometry. *Int J Prosthodont*. 2005;18(3):219-224.
44. Gedosev M. The perfect companion: CEREC 3D software upgrade V3.40. *Int J Comput Dent*. 2009;12(1):59-70.
45. Conrad HJ, Seong WJ, Pesun IJ. Current ceramic materials and systems with clinical recommendations: a systematic review. *J Prosthet Dent*. 2007;98(5):389-404.
46. Della Bona A, Kelly JR. The clinical success of all-ceramic restorations. *JADA*. 2008;139(9 suppl):8S-13S.
47. Pjetursson B, Sailer I, Zwahlen M, Hammerle C. A systematic review of the survival and complication rates of all-ceramic and metal ceramic reconstructions after an observation period of at least three years, part I: single crowns [published correction appears in *Clin Oral Implants Res*. 2008;19(3):326-328]. *Clin Oral Implants Res*. 2007;18(suppl 3):73-85.
48. Fasbinder DJ, Dennison JB, Heys D, Neiva G. A clinical evaluation of chairside lithium disilicate CAD/CAM crowns: A two-year report. *JADA*. 2010;141(suppl):10S-14S.

---

#### AUTHOR

COL Hodd is Assistant Director, Prosthodontics, US Army Dental Activity, Fort Gordon, Georgia.

# Is the US Army Dental Corps Ready for the Digital Impression?

COL Michael R. Craddock, DC, USA

COL Richard J. Windhorn, DC, USA

## INTRODUCTION

One of the first known dental impressions that resulted in dental casts was made by the German Philip Pfaff in 1756.<sup>1</sup> Since then, dental impression materials have progressed to a point of very high accuracy. Recently, the “digital” impression has emerged where the impression material is replaced by a digital camera. Presently, there are 4 chairside digital impression systems on the US market: iTero (Cadent Inc, Carlstadt, NJ); E4D Dentist (D4D Technologies, Richardson, TX); CEREC Connect (Sirona, Bensheim, Germany), and Lava Chairside Oral Scanner (C.O.S.) (3M ESPE, St Paul, MN). While the iTero, E4D, and CEREC Connect use cameras that take individual snapshots of the teeth, the Lava C.O.S. camera takes a continuous video. This article will discuss the use of the Lava C.O.S. digital impression and the dental laboratory Lava CAD/CAM (3M ESPE, St Paul, MN) system by the US Army Dental Command.

## THE ARMY DENTAL LABORATORY

In the Army Dental Care System, dental impressions and casts have to be shipped to the only centralized dental laboratory for the US Army, the Army Dental Laboratory (ADL), located on Fort Gordon, near Augusta, Georgia. It is a unique command, reporting directly to the US Army Dental Command, and supports 147 dental clinics worldwide. The unique mission of the 95 (49 military, 38 government civilian, 8 contract) employees who work there is to produce fixed crowns, bridgework, removable dentures, and orthodontic appliances for the dental beneficiaries receiving care in the Army Dental

Care System. During its 31-year history at this location, the ADL has adapted to changes in the way the dental profession is practiced. Because 80% to 85% of their work involves fixed dental prostheses, the lab has adapted to new impression materials and techniques. One of the most recent changes has been the use of CAD/CAM to fabricate zirconia-based crowns and bridges. This technique can also be used to fabricate crowns using more traditional materials, and allows for more rapid and more accurate production. The new technology of a digital impression in the dental workflow of a restoration combines the dental office with the CAD/CAM dental laboratory in the electronic world.

In the Army Dental Care System, casts are shipped via commercial shipping from all over the world. The use

of the new digital impression by the C.O.S will eliminate the initial physical shipment to the ADL. The ADL will use the digital impression to have a specialized civilian facility fabricate physical dental casts. These casts are computer-generated using new technology called stereolithography (SLA), a rapid prototyping technology. The SLA machine generates the casts by curing layer upon layer of light-sensitive polymer resin material.<sup>2</sup> The SLA casts are then mounted (Figure 1) and the dental dies are cut-out and margins trimmed (Figure 2). The completed, articulated SLA casts are then shipped to the ADL for a nominal fee.

The ADL can use the articulated SLA casts to fabricate a variety of restorations from many materials; gold, metal ceramic, or all-ceramic. For example, the ADL can use the




Figure 1. Articulated stereolithography cast.



Figure 2. Cut-out dental die with margins trimmed.



laboratory 3M ESPE Lava CAD/CAM system (Figure 3) to fabricate wax patterns from the digital impression, cast the gold crown, and perform final seating/occlusion adjustments on the articulated SLA casts. The same could be said for the all-ceramic crown or fixed dental prosthesis; the laboratory Lava system fabricates the very strong, all-ceramic zirconia framework (Figure 4) from the digital impression and the lab technician then stacks the porcelain onto the zirconia framework. Final adjustments are on the articulated SLA casts. The turnaround time for submitted cases can be substantially reduced with the digital impression. More importantly, the dental lab work for the submitting dentist is virtually eliminated with the use of the digital impression. The digital impression is “dropped” into a virtual case-pan at the ADL computer, very similar to a civilian dentist dropping their material impression into a case-pan of a local dental laboratory. This newest method eliminates the need to pour stone dies and ship them to the laboratory; which saves time, materials, and shipping costs. In addition, studies<sup>3,4</sup> have shown that crowns fabricated using CAD/CAM technology exhibit better marginal integrity and fit.

## LAVA CHAIRSIDE ORAL SCANNER

### System Description

The 3M ESPE Chairside Oral Scanner (C.O.S.) is a standalone mobile unit (Figure 5). Basically, it is a computer with a touch screen monitor and a video camera (called the Wand by 3M ESPE). The computer runs on the LINUX operating system and connects by encryption through a wireless connection to a router in the clinic. The Wand scanning camera is comprised of 192 LEDs and 22 lenses, has a 13.2 mm wide tip, and weighs 14 ounces (Figure 6). This is one of the smallest end of scanners on the market. It is placed in the patient’s mouth (Figure 7) and the 3D-in-motion technology enables the user to capture approximately 20 3D data sets per second (close to 2400 data sets per arch) with patented wavefront sampling technology.<sup>5</sup> There is no keyboard, but a virtual keyboard can be displayed on the monitor. The wand has protective

plastic infection barrier sleeves. Disinfection of the monitor involves using a typical dental surface disinfectant. A list of recommended disinfectants is provided by 3M ESPE.

### Workflow Procedures

Preparation of selected tooth/teeth is/are performed. The same principles for a preparation design are followed for gold, metal ceramic, or all-ceramic. Conventional tissue retraction and saliva control procedures are still needed. Many aids are on the market that can assist the dental team in isolating and assisting in obtaining a digital impression (eg, the OptraGate lip and cheek retractor

(Ivoclar-Vivadent, Amherst, NY) as seen in Figure 7). Next, a titanium dioxide based spray is used to coat all surfaces. As compared to the CEREC, only a light spraying is needed because the C.O.S. only needs reference points to form a virtual picture of the preparation(s). A unique battery-powered titanium dioxide sprayer is provided with the C.O.S. system (Figure 8).

The dentist begins the scan by pressing the button on the wand or by pressing the start key on the touch-screen monitor. A pulsating blue light is emitted by the wand. The dentist then slowly moves the camera over the occlusal surfaces, then buccal, then lingual, and



Figure 3. Lava Mill CNC 500 at the Army Dental Laboratory.




Figure 4. Lava CNC 500 milling zirconia block at the Army Dental Laboratory.

ending where the scan began. This completes the “scanning loop.” If there is a sudden movement, the software will pause allowing the dentist to reorient the camera. As the teeth are scanned, the captured areas will turn light yellow, leaving red areas that need further scanning. The image is then evaluated on the monitor by rotating the image with simple finger movements on the touch screen (Figure 9). The dentist then scans the opposing arch and then the buccal occlusal surfaces with the patient in maximal intercuspation (Figure 10). Respraying of the surfaces may be needed due to loss of titanium dioxide on surfaces from movement, saliva, etc. Total time for the three scan phases is typically less than ten minutes, depending on experience of operator and complexity of case.

After review of the completed scans (Figure 11), the dentist fills in an on-screen electronic prescription and sends the encrypted case through the wireless network (Figure 12) to 3M ESPE servers. If multiple patients are being scanned during a day and to reduce chairside time, all cases can be uploaded at once during the night. The case(s) are transferred to registered 3M ESPE laboratories, in this case the Army Dental Laboratory. The ADL uses software to mark the preparation margins. If the Laboratory has problems with a margin location, they can send the capture areas of the margins in question to the dentist by email. The dentist then can mark the margins in question and return the information to the ADL. The digital case is then sent to a third-party facility that generates the SLA casts. The articulated SLA casts with cut-out preparation dies is returned to the ADL. This process usually requires no more than 3 days from the time the dentist sends the electronic impression/prescription. If

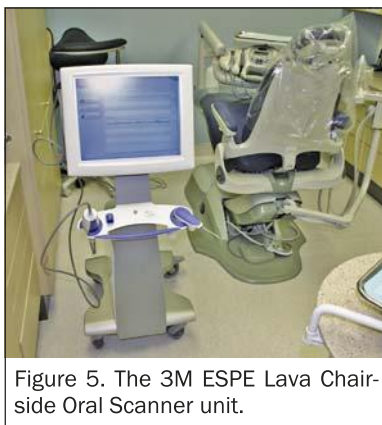

Figure 5. The 3M ESPE Lava Chair-side Oral Scanner unit.

a dentist wants to mark his or her own preparation margins, the margin-marking computer and software can be purchased from 3M ESPE.

While waiting for the articulated SLA casts, the ADL can start milling wax patterns for metal ceramics/gold crowns, or all-ceramic frameworks/crowns (Figure 13). Final porcelain addition and fit/adjustment are completed upon arrival of the articulated SLA casts. Typically, total

in-house time for a simple digital impression restoration is planned to be less than 10 calendar days. This period rivals any similar restoration time from a civilian dental laboratory for a digital impression or a conventional material impression.

The digital impression is a major new paradigm shift for the fabrication of a dental fixed restoration in the Army Dental Care System. Due to the widespread global locations of Army dental clinics, the use of new dental technologies like the digital impression in conjunction with new CAD/CAM technologies at the ADL has the potential to greatly reduce time and costs. This can be of great benefit to the Army Dental Corps, the Army and other US military services, and, most importantly, the military dental care patient.

## ACKNOWLEDGEMENT

The photos in Figures 1 through 5, Figures 7 through 11, and Figure 13 were provided by the author. The images in Figures 6 and 12 are courtesy of 3M ESPE.

## REFERENCES

1. Craig RG, Hanks CT, eds. *Restorative Dental Materials*. 9th ed. St Louis, Missouri: C.V. Mosby; 1993:8.
2. Pilsner D. Implementing digital impression. *J Dent Technol*. November/December 2010:28.
3. Christensen GF. *Clinicians Report* [serial online]. April 2010:3-4. Available at: <http://www.cliniciansreport.org/>. Accessed November 29, 2010.
4. Farah JW, Powers JM, eds. CAD/CAM update. *The Dental Advisor* [serial online]. 2009;26(7). Available at: <http://www.dentaladvisor.com/publications/the-dental-advisor/26-07.shtml>. Accessed November 29, 2010.

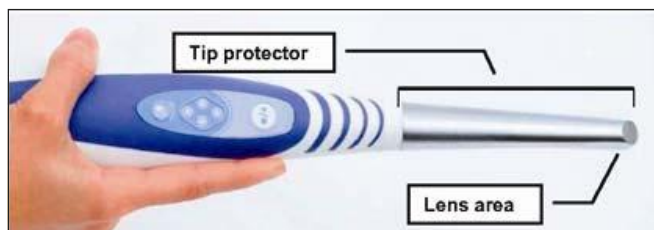

Figure 6. The wand used with the LAVA C.O.S. digital scanner. (Image reproduced from the 3m ESPE Lava C.O.S. user manual with permission.)



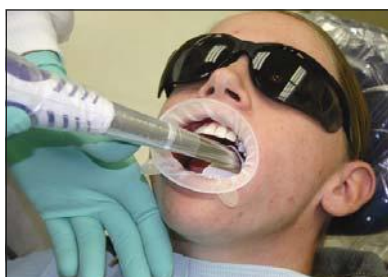

Figure 7. LAVA C.O.S. wand in use.

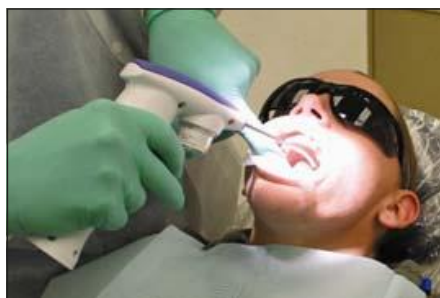

Figure 8. 3M ESPE battery-powered titanium dioxide sprayer.

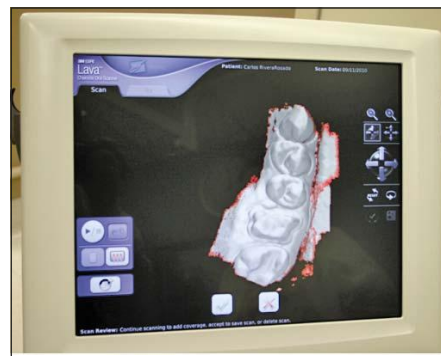

Figure 9. Typical scan of preparation.

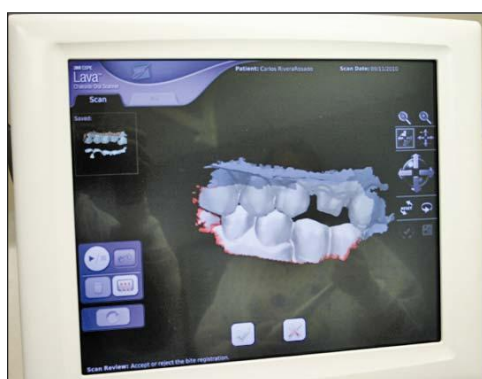

Figure 10. Scan of maximal intercuspation.

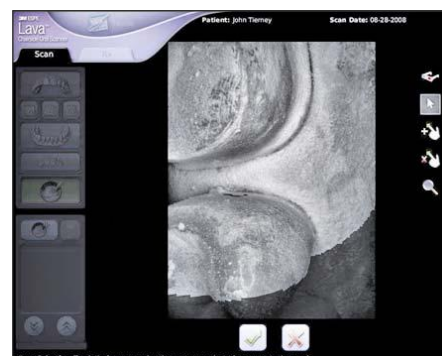

Figure 11. Completed up-close scan of preparation margins.

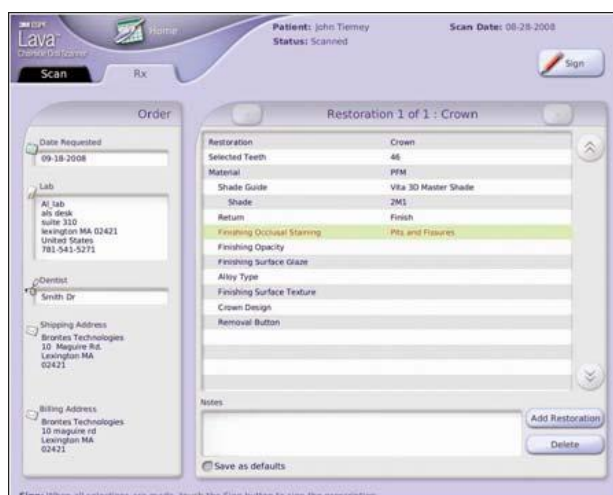

Figure 12. Example of 3M ESPE LAVA C.O.S. lab prescription. (Image reproduced from the 3m ESPE Lava C.O.S. user manual with permission.)

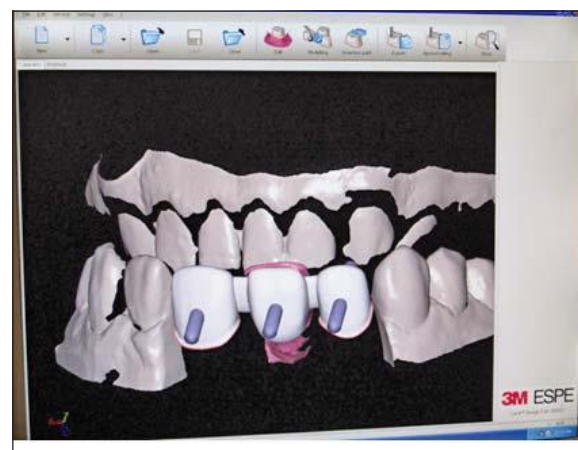


Figure 13. Example of a LAVA scan and design at the Army Dental Laboratory

5. Rohaly J, Hart DP, Brukilacchio TJ, inventors. 3M Innovative Properties Co, assignee. Three-channel camera systems with non-collinear apertures, US Patent 7,372,642. May 13, 2008.

## AUTHORS

COL Craddock is Chief of Prosthodontics, US Army Dental Activity, Fort Carson, Colorado.

COL Windhorn is Commander, US Army Dental Laboratory, Fort Gordon, Georgia.



# Ten-Month In Vitro Leakage Study of a Single-Cone Obturation System

LTC A. John McKissock, DC, USA  
COL Pete Mines, DC, USA  
COL Mark B. Sweet, DC, USA  
Col Steven L. Klyn, DC, USAF

## ABSTRACT

The purpose of this study was to compare the in vitro sealing ability of the continuous wave of condensation technique using gutta-percha and an epoxy resin based sealer, AH Plus to the sealing ability of the single-cone, glass-ionomer-based Activ GP Precision Obturation System over 10 months. Fifty maxillary anterior teeth were randomly divided into 2 test groups (20 canals each) and 2 control groups (5 positive and 5 negative). All teeth were stored in 0.9% saline. Group 1 (GP) was prepared with rotary instruments and obturated with the continuous wave of condensation technique using gutta-percha and AH Plus sealer. Group 2 (Activ GP) was prepared with rotary instruments and obturated using the heatless, single-cone, glass-ionomer-based Activ GP Precision Obturation System. Each canal orifice was sealed with amalgam and stored for 10 months in 100% humidity at 37°C. Amalgam was removed and leakage was evaluated by fluid transport at 10 psi. The median leakage for Group 1 (GP) was 0.500 mm and Group 2 (Activ GP) was 18.865 mm. A Mann-Whitney Rank Sum test was used to evaluate the data and determine if a difference existed between the 2 groups. Under the conditions of this study, the Activ GP glass-ionomer-based single-cone obturation technique demonstrated statistically significant higher leakage rates than a continuous wave of condensation technique.

## BACKGROUND AND LITERATURE REVIEW

Even before Kakehashi et al proved in their landmark 1965 germ-free rat study that bacterial contamination of the root canal system is the cause of apical periodontitis,<sup>1</sup> endodontists have sought the most effective means to seal the root canal space. Although successful endodontic therapy is a multifactorial process of bacterial elimination, the apical to coronal seal is well accepted as a key element of preventing reinfection and refractory disease.<sup>2</sup> Once pathogenic microorganisms have been reduced below a patient's threshold to cause disease, the goal is to 3-dimensionally fill and seal the complex root canal system.<sup>3-5</sup> However, the manner in which this goal is achieved has fueled a great deal of research and innovation.

Currently, there are many obturation systems available. For the purposes of this study, 3 obturation techniques are described: lateral compaction, continuous wave of condensation, and a less common single-cone technique. The first, lateral compaction, uses a master cone of gutta-percha supplemented by accessory cones. To this day, it is likely to be the first technique taught in dental school.<sup>6</sup> In 1967, Schilder described a warm vertical compaction technique that

hydraulically pushes thermoplasticized gutta-percha into the most apical parts of the canal system with a series of custom fitted pluggers.<sup>5</sup> Another warm vertical compaction technique incorporates thermoplasticized gutta-percha dispensers and standardized master cones that precisely match the taper of nickel titanium rotary files and is known as the continuous wave of condensation technique.<sup>7</sup> Once mastered, this technique can reduce the time required to complete obturation and is the technique of choice of many practitioners today.<sup>6</sup> The third technique, the single-cone technique, has been used for years in various forms. In 1984, Cohen and Burns described a technique using a single, uncondensed but fitted gutta-percha master cone for obturation.<sup>8</sup> The appeal of the single-cone technique is simplicity and speed of obturation.<sup>9</sup>

Regardless of the technique implemented, the type and composition of sealer is a key component in achieving the goal of a sealed root canal system. Today, a popular epoxy resin based sealer, AH Plus (E/T Endodontic Technologies Ltd, Halifax, Nova Scotia, Canada), has performed well in in vitro leakage studies.<sup>10-12</sup> Recently, glass-ionomer-based sealers have been reintroduced because of their chemical bond to dental hard tissues,<sup>13,14</sup> fluoride release,

antimicrobial activity and biocompatibility.<sup>15</sup> One such recently introduced glass-ionomer sealer is the Activ GP Precision Obturation System (Brasseler USA, Savannah, GA).

The Activ GP System combines a single-cone technique with a glass-ionomer-based sealer that the manufacturer claims will create a “monoblock” between the tooth, sealer, and core material. The term “monoblock” has been used in many of the methacrylate based obturation systems not examined here. Monoblock generally refers to a gap-free, solid mass of different materials that simultaneously improves the seal and fracture resistance of the filled canals.<sup>16</sup> The Activ GP System uses a gutta-percha master cone that has been coated and impregnated with glass ionomer particles. The rationale is the glass-ionomer-based sealer will bond to the dentinal walls of the canal as well as the glass ionomer particles in and on the master cone. The manufacturer recommends a heatless single-cone technique that relies on tapered cones that match prepared canals, as well as a glass-ionomer-based sealer to fill canal irregularities and seal the apical canal space. Unfortunately, single-cone techniques have not historically met the challenges of providing a 3-dimensionally filled and sealed root canal system.<sup>17</sup> The unfavorable geometry of the canal space<sup>18</sup> and a preponderance of sclerotic radicular dentin in the canal’s apical third<sup>19</sup> prevents a true, gap-free seal as suggested by the monoblock moniker used in many advertisements.

The purpose of this study is to compare the newly introduced Activ GP obturation system to the continuous wave of condensation technique with a resin based sealer over a 10-month period.

## **MATERIALS AND METHODS**

All procedures were completed by one investigator.

Fifty extracted, single-canal, human anterior teeth with at least 15 mm of root length were collected and stored in 0.9% saline. Calculus and soft tissue remnants were removed by mechanical means. All teeth were examined for cracks or fractures, as well as to confirm a single apical foramen using transillumination (Microlux Transilluminator, Adent Inc, Danbury, CT) and a dental operating microscope (Global Surgical Corporation, St Louis, MO). Teeth with canal curvatures greater than 10° or canal patency greater

than an International Standards Organization (ISO) size 15 K-type file (Henry Schein Inc, Melville, NY) were discarded.

The crowns were removed with a #557 carbide bur (Henry Schein, Melville, NY), leaving no less than 15 mm root sections. Working length was determined by subtracting 1.0 mm from the length that a 10 K type file was first visible at the apical foramen. All canals were hand filed to a 20 K type file using full-strength sodium hypochlorite (Clorox, Oakland, CA) as a lubricant. The 50 root canals were randomly divided into 2 experimental groups (n=20) and 2 control groups (n=5).

### **EXPERIMENTAL GROUP 1: CONTINUOUS WAVE OF CONDENSATION**

Canal preparation was completed using a crown down technique with 0.04 tapered nickel-titanium rotary instruments to a size 40 rotary file. The root canals were irrigated with sodium hypochlorite using a 28-gauge side port syringe (Max-i-Probe, Dentsply Rinn, Elgin, IL). Patency and apical stops were confirmed with a 10 K type file and a 40 K type file respectively. A final rinse of 5 ml of 17% ethylenediamine tetraacetic acid (Pulpdent Corp., Watertown, MA) was followed by 5 ml of sodium hypochlorite rinse. All canals were then dried using paper points (Henry Schein, Melville, NY).

An epoxy resin-based sealer, AH Plus, was mixed according to the manufacturer’s instructions and applied to the root canal walls while placing a size 40/0.04 taper master gutta-percha cone (Dia-ISO GT .04; DiaDent, Burnaby, BC, Canada) to working length. Once seated, a 0.08 tapered System B heat source plugger (SybronEndo, Orange, CA) set at 200° C was introduced into the canal. The System B was activated and slowly pushed into the canal within 4 mm of working length. The plugger was then held in position for 10 seconds, reactivated for 1 second, and withdrawn. A 5/7 plugger (Hu-Friedy Mfg Inc, Chicago, IL) was immediately introduced into the canal to assure seating of the apical plug. The coronal canal walls were coated with the epoxy resin-based sealer and backfilled with warm gutta-percha from an Obtura II (Spartan, Fenton, MO) set at 185°C. The warm gutta-percha was immediately down-packed with a 5/7 plugger.

## Ten-Month In Vitro Leakage Study of a Single-Cone Obturation System

Since the obturated canals were to be stored for 10 months, the coronal 2 to 3 mm of gutta-percha was removed with the System B, sealed with a 2 to 3 mm amalgam restoration (Tytin amalgam, Kerr Corporation, Orange, CA), and stored in 100% relative humidity at 37°C for 10 months.

### EXPERIMENTAL GROUP 2: SINGLE-CONE TECHNIQUE (ACTIV GP)

Experimental Group 2 was prepared the same as Group 1 in regards to working length, hand filing, and smear layer removal. The final canal preparation was completed using a crown down technique with 0.04 tapered nickel-titanium rotary instruments to a size 40 rotary file.

Per the manufacturer's recommendations, the Activ GP glass-ionomer sealer was mixed and placed in the canal with a clean 40 K type file using a circular motion to the working length. An Activ GP 0.04 taper gutta-percha master cone was coated with sealer and slowly inserted to working length, allowing the sealer to escape coronally. The coronal 2 to 3 mm of gutta-percha was removed with the System B, and the canal orifice was sealed with an amalgam and stored in 100% relative humidity at 37°C for 10 months.

### EXPERIMENTAL GROUPS 3 AND 4: POSITIVE AND NEGATIVE CONTROLS

Five roots were treated the same as Group 1 with the exception that no sealer was used. These 5 roots served as the positive controls to test the maximum fluid flow through the fluid transport device. The last 5 roots were treated the same as Group 1 with the exception that the root surfaces were sealed with cyanoacrylate to act as the negative controls. All roots were sealed with amalgam and stored in 100% relative humidity at 37°C for 10 months.

### LEAKAGE TESTS

Using a fluid transport model (Figure 1) as described by Maloney et al,<sup>20</sup> Koagel et al,<sup>21</sup> and Stratton et al,<sup>22</sup> Plexiglass blocks were penetrated by an 18-gauge stainless steel tube (SafetyGlide Needle, Franklin Lakes, NJ) so that 1.0 mm of tubing protruded from the root side of the Plexiglass. The 2.0 to 3.0 mm deep amalgam restorations were removed from each root with a 330 carbide bur. The roots were mounted with

viscous cyanoacrylate cement to the Plexiglass blocks with the orifices located over the steel tubing. The negative controls were re-treated with cyanoacrylate prior to testing.

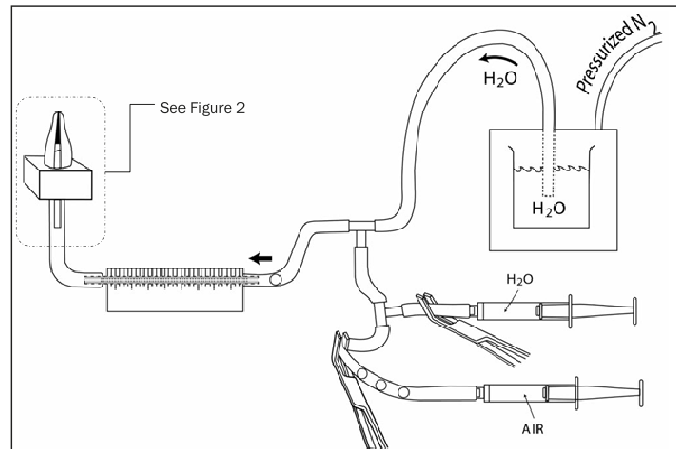


Figure 1. General schematic of the fluid transport model used to conduct the leakage tests on study objects.

Each Plexiglass-root assembly (Figure 2) was attached to the fluid transport-measuring device. The fluid transport device used compressed nitrogen gas and a pressure pot to push a solution of 0.02% sodium azide at 10 psi through the stainless steel tube of the Plexiglass-root assembly and ultimately the root being tested. The fluid rates through the tested specimens were quantified by measuring the progress of a tiny air bubble as it traveled within the polyethylene tubing along a 150 mm Fisher Scientific ruler. Each specimen was tested 3 times for 3 minutes and the bubble's movement was recorded to the tenth of a millimeter. A Mann-Whitney Rank Sum test (SigmaStat 3.5, Point Richmond, CA) was calculated to determine the existence of a statistically significant difference between the two groups. Values of  $P < .05$  were considered significant.

### RESULTS

The leakage of the negative controls was uniformly zero and the leakage of the positive controls was immeasurably high. The leakage results of 14 of the 20 teeth (70%) in Group 2




Figure 2. Photo of typical Plexiglass-root assembly test object.



(Activ GP) were immeasurably high using a fluid transport system with a 150 mm ruler. The 6 teeth that registered measurable levels in Group 2 (Activ GP) had a median leakage of 18.865 mm, and the median leakage for Group 1 (GP) was 0.500 mm.

A Mann-Whitney Rank Sum test indicated the differences in the median values is greater than would be expected by chance. The results showed a statistically significant difference between the test groups ( $P < .001$ ).

## COMMENT

Although obturation techniques and materials continue to improve, the results of this study remind one that no current obturation technique or material can completely seal a complex root canal space.<sup>23-25</sup> The advantage of testing leakage with a fluid transport model is its unique ability to quantify leakage. Under the conditions of this study, the magnitude of difference between the two test groups is statistically significant.

The high leakage rates of the Activ GP obturation system may be due to the potential for gapping along the sealer/dentin interface.<sup>26</sup> Additionally, the contribution of glass ionomer's adhesive properties in the apical third of a canal has been theorized but not demonstrated in the literature.<sup>21-30</sup> Also, some researchers have expressed concern over glass-ionomer cement/sealer's propensity for disintegration and leakage.<sup>31,32</sup>

In vitro studies of another glass-ionomer sealer, Ketac-Endo (3M/ESPE, Minneapolis, MN), found lower leakage rates than traditional zinc oxide-eugenol sealers.<sup>25,33,34</sup> However, this is not conclusive and some studies have found more leakage with glass-ionomer-based sealers.<sup>10,35</sup> An English-language literature search for glass-ionomer sealer studies failed to reveal any studies for a period greater than 90 days. It appears that time may be correlated to the Activ GP obturation system's high leakage rates and the concern for disintegration of glass-ionomer-based sealers merits further research.

One consistent finding of fluid transport model studies is that sealers have lower leakage rates when the sealer is the thinnest.<sup>36</sup> A single-cone technique is often considered inferior to continuous wave of

condensation because the volume of sealer is high relative to the volume of the cone.<sup>37</sup> The Activ GP obturation system is no exception, especially when ovoid shaped canals are obturated. The imbalance in sealer-to-cone ratio promotes void formation and likely reduces the quality of the seal.<sup>38</sup> Currently, the goal is to maximize the amount of solid core material and minimize the amount of sealer<sup>39</sup> to best seal the root canal system, entomb remaining bacteria and fill irregularities of the prepared canal.<sup>40</sup>

Under the conditions of this study, the incorporation of glass ionomer in the sealer and master cone of the Activ GP obturation system does not appear to solve the historically poor in vitro leakage rates often associated with single-cone techniques. However, any correlation between fluid transport leakage rates and bacterial leakage is currently unknown.<sup>33</sup>

## CONCLUSION

Within the parameters of this study, a complete seal did not occur for any test group. Using a fluid transport system, the Activ GP glass-ionomer-based single-cone obturation technique demonstrated significantly higher leakage rates than a continuous wave of condensation and gutta-percha technique ( $P < .001$ ).

## REFERENCES

1. Kakehashi S, Stanley HR, Fitzgerald RJ. The effects of surgical exposures of dental pulps in germ-free and conventional laboratory rats. *Oral Surg Oral Med Oral Pathol Oral Radiol Endod.* 1965;20:505-516.
2. Paque F, Sirtes G. Apical sealing ability of Resilon/Epiphany versus gutta-percha/AH Plus: immediate and 16-month leakage. *Int Endod J.* 2007;40:722-729.
3. Michaud R, Burgess J, Barfield R, Cakir D, McNeal S, Eleazer P. Volumetric expansion of gutta-percha in contact with eugenol. *J Endod.* 2008;34:1528-1532.
4. Ozok AR, van der Sluis LW, Wu MK, Wesselink PR. Sealing ability of a new polydimethylsiloxane-based root canal filling material. *J Endod.* 2008;34:204-227.
5. Schilder H. Filling root canals in three dimensions. *Dent Clin North Am.* 1967;11:723-744.
6. Cailleteau JG, Mullaney TP. Prevalence of teaching apical patency and various instrumentation and obturation techniques in United States dental schools. *J Endod.* 1997;23:394.

## Ten-Month In Vitro Leakage Study of a Single-Cone Obturation System

7. Buchanan L. Continuous wave of condensation technique. *Endod Prac.* December 1998;115-125.
8. Cohen S, Burns RC, eds. *Pathways of the Pulp*. 3rd ed. St Louis, MO: C.V. Mosby; 1984:XX-XX. Cited by: Beatty RG, Vertucci FJ, Zakariasen KL. Apical sealing efficacy of endodontic obturation techniques. *Int Endod J.* 1986;19(5):237-241.
9. Horsted-Bindslev P, Andersen MA, Jensen MF, Nilsson JH, Wenzel A. Quality of molar root canal fillings performed with the lateral compaction and the single-cone technique. *J Endod.* 2007;33:468-471.
10. Monticelli F, Sword J, Martin RL, Schuster GS, Weller RN, Ferrari M, Pashley DH, Tay FR. Sealing properties of two contemporary single-cone obturation systems. *Int Endod J.* 2007;40:374-385.
11. Ozok AR, van der Sluis LW, Wu MK, Wesselink PR. Sealing ability of a new polydimethylsiloxane-based root canal filling material. *J Endod.* 2008;34:204-207.
12. Brackett MG, Martin R, Sword J, Oxford C, Rueggeberg RA, Tay FR, Pashley DH. Comparison of seal after obturation techniques using a polydimethylsiloxane-based root canal sealer. *J Endod.* 2006;32:1188-1190.
13. Aboush YE, Jenkins CB. An evaluation of the bonding of glass-ionomer restoratives to dentine and enamel. *Br Dent J.* 1986;161:179-184.
14. Powis DR, Folleras T, Merson SA, Wilson AD. Improved adhesion of glass ionomer cement to dentin and enamel. *J Dent Res.* 1982;6:1416-1422.
15. De Bruyne MA, De Moor RJ. The use of glass ionomer cements in both conventional and surgical endodontics. *Int Endod J.* 2004;37:91-104.
16. Teixeira FB, Teixeira EC, Thompson J, Leinfelder KF, Trope M. Dentinal bonding reaches the root canal system. *J Esthet Restor Dent.* 2004;16:348-354.
17. Whitworth J. Methods of filling root canals: principles and practices. *Endod Top.* 2005;12:2-24.
18. Schwartz RS. Adhesive dentistry and endodontics: part 2-bonding in the root canal system: the promise and the problems-a review. *J Endod.* 2006;32:1125-1134.
19. Kim YK, Grandini S, Ames JM, Gu L, Kim SK, Pashley DH, Gutmann JL, Tay FR. Critical review on methacrylate resin-based root canal sealers. *J Endod.* 2010;36:383-399.
20. Maloney SM, McClanahan SB, Goodell GG. The effect of thermocycling on a colored glass ionomer intracoronary barrier. *J Endod.* 2005;31:526-528.
21. Koagel SO, Mines P, Apicella M, et al. In vitro study to compare the coronal microleakage of Tempit UltraF, Tempit, IRM, and Cavit by using the fluid transport model. *J Endod.* 2008;34:442-444.
22. Stratton RK, Apicella MJ, Mines P. A fluid filtration comparison of gutta-percha versus Resilon: a new soft resin endodontic obturation system. *J Endod.* 2006;32:642-645.
23. Wu MK, Wesselink PR. Endodontic leakage studies reconsidered. part 1. methodology, application and relevance. *Int Endod J.* 1993;26:37-43.
24. Camps J and Pashley D. Reliability of the dye penetration studies. *J Endod.* 2003;29:592-594.
25. Bal AS, Hicks ML, Barnett F. Comparison of laterally condensed .06 and .02 tapered gutta-percha and sealer in vitro. *J Endod.* 2001;27:786-788.
26. Tay FR, Loushine RH, Lambrecht P, Weller RN, Pashley DH. Geometric factors affecting dentin bonding in root canals: a theoretical modeling approach. *J Endod.* 2005;31:584-589.
27. Miletic I, Anic I, Pezelj-Ribaric S, Jukic S. Leakage of five root canal sealers. *Int Endod J.* 1999;32:415-418.
28. Oliver CM, Abbott PV. An in vitro study of apical and coronal microleakage of laterally condensed gutta percha with Ketac-Endo and AH-26. *Aust Dent J.* 1998;43:262-268.
29. Koch K, Min PS, Stewart GG. Comparison of apical leakage between Ketac-Endo sealer and Grossman sealer. *Oral Surg Oral Med Oral Pathol.* 1994;78:784-787.
30. de Gee AJ, Wu MK, Wesselink PR. Sealing properties of Ketac-Endo glass ionomer cement and AH26 root canal sealers. *Int Endod J.* 1994;27:239-244.
31. Friedman S, Lost C, Zarrabian M, Trope M. Evaluation of success and failures after endodontic therapy using glass ionomer cement sealer. *J Endod.* 1995;21:384-390.
32. Schäfer E, Zandbiglari T. Solubility of root canal sealers in water and artificial saliva, *Int Endod J.* 2003;36:660.
33. Dalat DM and Önal B. Apical leakage of a new glass ionomer root canal sealer. *J Endod.* 1998;24:161-163.
34. Wu MK, De Gee AJ, Wesselink PR. Leakage of four root canal sealers at different thickness. *Int Endod J.* 1994b;27:304-308.
35. Smith MA, Steiman HR. An in vitro evaluation of micro-leakage of two new and two old root-canal sealers. *J Endod.* 1994;20:18-21.

36. Wu MK, Wesselink PR, Boersma J. A 1-year follow-up study on leakage of four root canal sealers at different thicknesses. *Int Endod J*. 1995;28:185-189.
37. Kontakiotis EG, Tzanetakis GN, Loizides AL. A 12-month longitudinal in vitro leakage study on a new silicon-based root canal filling material (Gutta-Flow). *Oral Surg Oral Med Oral Pathol Oral Radiol Endod*. 2007;103:854-859.
38. Bouillaguet S, Shaw L, Barthelemy J, Krejci I, Wataha JC. Long-term sealing ability of pulp canal sealer, AH-Plus, GuttaFlow and Epiphany. *Int Endod J*. 2008;41:219-226.
39. Wu MK, Kašáková A, Wesselink PR. Quality of cold and warm gutta-percha fillings in oval canals in mandibular premolars. *Int Endod J*. 2001;34:485-491.
40. Ørstavik D. Materials used for root canal obturation: technical, biological and clinical testing. *Endod Top*. 2005;12:25-38.

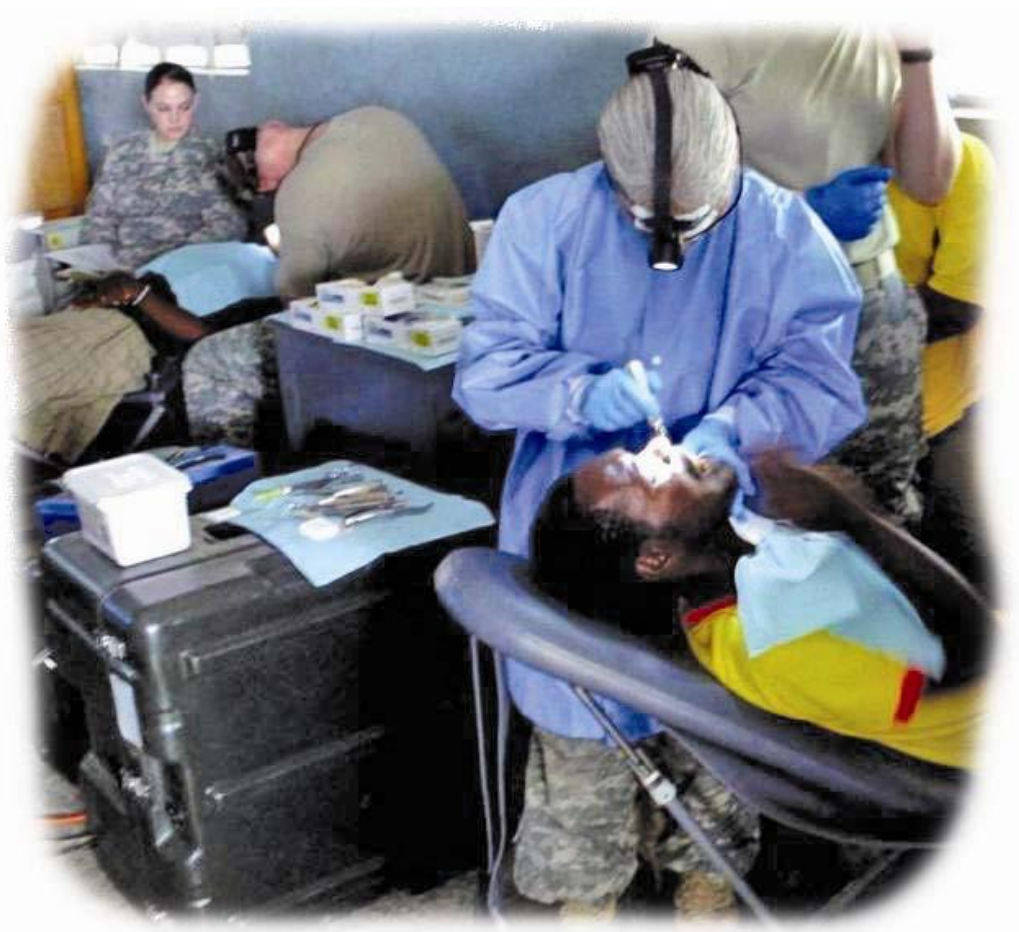
## AUTHORS

LTC McKissock is Chief, Endodontic Services, US Army Dental Activity, and Officer in Charge, Smith Dental Clinic, Fort Carson, Colorado.

COL Mines is Chief, Endodontic Services, US Army Dental Activity, and Officer in Charge, Rohde Dental Clinic, Fort Bragg, North Carolina.

COL Sweet is Commander, Vicenza Dental Clinic Command, US Army Garrison, Vicenza, Italy.

Col Klyn is Chief of Endodontics, 10th Dental Squadron, United States Air Force Academy, Colorado.



Humanitarian relief and assistance missions, such as this one in Haiti in 2009, are a regular part of the practice of dentistry by members of the US Army Dental Corps. Photo courtesy of the US Army.



# US Army Dental Command Information Management: Poised to Provide Quality Support for the Next 100 Years

LTC Jeffrey S. Marks, MS, USA  
MAJ Thomas E. Strohmeyer, MS, USA

In 1998, the US Army Dental Command (DENCOM) Information Management and Technology Division (IM&TD) was tasked with replacing the existing scheduling and workload entry applications with a single enterprise solution. DENCOM leadership mandated that this single solution must be able to collect, process, present, and archive dental workload, readiness, and patient scheduling data. The end result of their efforts is the Corporate Dental Application (CDA).

## EVOLUTION OF AN ENTERPRISE SOLUTION

From its initial deployment, CDA has continued to evolve as new mission demands have driven the addition of new capabilities. These new capabilities have not only allowed Army dental providers to improve the efficiency of care, but have also resulted in significant improvements in the quality of care.

Originally intended to serve only as a portal for entering workload data and updating dental readiness classification information, CDA has grown into a robust enterprise dental solution comprised of modules for scheduling, data entry, reporting, digital image acquisition and viewing, and even a dental lab management tool. All of these modules are integrated into a single data repository that contains one of the largest collections of dental data ever accumulated. Some examples of the types and volume of data processed by CDA include:

- 12,000 appointments scheduled daily
- 1,300 dental lab cases processed monthly
- Approximately 2 million workload entries per year
- Approximately 5,000 digital images processed daily
- Over 19 million archived digital images

## SEAMLESS INTEGRATION OF SCHEDULING, WORKLOAD, AND READINESS

The core of CDA functions are presented within an internet interface that permits providers to collect, process, present, and archive dental workload, readiness, and patient scheduling data from a single portal. Commanders, staff, and functional managers throughout the Army can access this information online in real-time from a single point of access.

The primary component within CDA is the Web Scheduler. As an appointment is scheduled, the Web Scheduler adds the appointment data to a single data repository. As changes are made to the appointment, these changes can be viewed throughout the dental enterprise. These changes are also reflected in real-time within the clinic so that providers can view the activities within the entire clinic without leaving their treatment area.

After an appointment is completed, providers must complete the treatment needs and workload information for that patient encounter within CDA. Providers are supplied with visual reminders if these details are not completed, and additional reporting capabilities allow clinic managers and leadership to track such information gaps. As part of the data entry process, the provider must also identify a Soldier's dental readiness classification (DRC).

Providers and unit commanders can also leverage the DRC information processed by CDA to improve the deployability of Soldiers. Each treatment encounter includes a dental readiness component. As a provider completes each appointment, they must determine the DRC of the Soldier being treated. If a Soldier has treatment needs that preclude him or her from deployment, they must account for these needs within the

system. Other providers can then access the information as the Soldier returns for treatment and carry out the required procedures. Unit commanders are permitted to view the DRC information for Soldiers assigned to their units so that they can ensure their personnel meet the deployment requirements.

## **INTEGRATING DIGITAL IMAGING**

In recent years, CDA has added digital radiographic images to the data that is collected within the enterprise through its integration with the Army Dental Digital Repository (ADDR). The ADDR is the central image archive that hosts all digital images acquired throughout the Army dental enterprise. As of the end of fiscal year 2009, the ADDR hosted over 14 million digital images.

One of the primary concerns in the adoption of a digital radiography solution for the CDA dental enterprise was how to deal with the many sites to which digital x-ray equipment had been deployed. To completely replace existing systems would quickly exhaust the DENCOM's budget. A system was needed that could use existing hardware, but still allow other sites to be "digitized" without waiting for all Army dental treatment facilities to have the same set of equipment across the enterprise. Hardware replacement was not an option, so DENCOM IM&TD turned to a software solution to the problem. After examining all commercial products available the time, it became clear that if a software solution was required, it would be necessary for DENCOM IM&TD to develop it. The resulting software solution is the Dental Enterprise Viewing and Acquisition Application (DEVAA).

DEVAA creates an industry standard Digital Imaging and Communications in Medicine (DICOM) object. The use of DICOM ensures interoperability with current and future imaging systems and ensures that any provider at any location can view the images, without requiring proprietary software to take those images. DEVAA uses a vendor's own device drivers to initialize the sensors and take the images from within the application interface.

After an image is acquired using DEVAA at the local clinic, it is transmitted to the ADDR via the Department of Defense Nonclassified Internet Protocol Router Network. Digital images are available 24 hours a day, 365 days a year from the internet. Images can be

searched based on the Soldier's social security number and the type of image that the provider wants to view. Images can be enhanced by the providers using various image tools that are built into the interface. These tools allow a user to adjust magnification, contrast, brightness, and even image mirroring.

## **DELIVERING A HIGHER STANDARD OF CARE**

CDA has provided a significant number of benefits in the quality and efficient delivery of care. Key among these benefits realized by dental providers is the ability to create a real-time view of patient status. To see the current status of patients in the clinic, a user only needs to view the appointments displayed in the scheduler grid. As the status of each patient changes, the appointment information is updated in the database. CDA depicts the status change using predefined color codes.

Patient care has also been directly enhanced by the development of CDA and its associated modules. The Web Scheduler incorporates scheduling, workload, and readiness into a seamless data process that reduces the time requirements for administrative tasks. This time-savings results in a corresponding increase in time available for providers to perform patient treatment tasks.

CDA used in conjunction with the Interactive Patient Check-In application allows patients to check in for appointments using standalone machines that update the clinic's overall appointment schedule. This gives front desk personnel more time to assist in patient care activities.

Another benefit provided by CDA is the ability to better allocate provider resources. Recent history has proven that dental readiness can directly impact operational capabilities. Before CDA was introduced, it was difficult to determine which facilities may be experiencing a shortage of specific skills that directly impact dental readiness. By using CDA, supervisors can generate reports that detail the readiness status at the regional dental command, base, and dental treatment facility levels, and assign resources accordingly.

The integration of digital imaging into the CDA data store has greatly increased a provider's ability to identify patient care issues. Digital images allow for true "portability" of image records. This portability

## US Army Dental Command Information Management: Poised to Provide Quality Support for the Next 100 Years

allows providers to consult other dentists to allow for improved teleradiology efforts at any location. In addition, the ability to access records taken at another site greatly reduces the need to retake images. This reduces the cost and risk to the patient from exposure to ionizing radiation.

DEVAA has also allowed for dramatic improvements in the workflow process at many clinics. For example, workers normally tasked with developing x-ray images are now able to assist in other aspects of patient care. At basic training bases, new recruits are required to have one panographic scan and 4 bitewings taken when they are processed upon arrival. Before the deployment of DEVAA, it could take an entire day to process just the panographic images. After DEVAA was deployed, clinic personnel were able to take 5 digital images in the same amount of time required to take traditional film x-rays.

### COORDINATION WITH OTHER AGENCIES

Since 2003, the US Air Force has partnered with the DENCOM to use the scheduling features of CDA. Relevant data is separated by service, but all data is contained in a single data repository. While the Air Force does not yet fully utilize all of the capabilities

provided by CDA, each service has been provided with a “total” integrated view of their patient population which directs their efforts to maximize both access to care and quality of care accordingly.

DENCOM IM&TD is also working with the US Navy Medical Information Management Center to establish a digital image sharing agreement between the services. The agreement establishes an image backup at the National Naval Medical Center (Bethesda) for the Army, and at Fort Sam Houston for the Navy, while allowing each service access to the other services’ images as necessary.

The future of technology and its use in healthcare is exciting and unlimited, and the DENCOM Information Management and Technology Division stands ready to support its evolution throughout the next 100 years.

---

### AUTHORS

LTC Marks is the Chief Information Officer, US Army Dental Command, Fort Sam Houston, Texas.

MAJ Strohmeyer was formerly the Chief Information Officer, US Army Dental Command, Fort Sam Houston, Texas.



Articles published in the *Army Medical Department Journal* are indexed in MEDLINE, the National Library of Medicine’s bibliographic database of life sciences and biomedical information. Inclusion in the MEDLINE database ensures that citations to *AMEDD Journal* content will be identified to researchers during searches for relevant information using any of several bibliographic search tools, including PubMed.



A service of the National Library of Medicine  
and the National Institutes of Health



# Use of the Army Dental Command Corporate Dental Application as an Electronic Dental Record in the Iraq Theater of Operations

COL Steven Eikenberg, DC, USA  
MAJ Robert Keeler, DC, USA  
SFC Thomas Green, USA

## ABSTRACT

More than 97% of the dental encounters in Iraq between June 2009 and July 2010 were captured on an electronic dental record. Data from more than 56,000 patient encounters, with detailed treatment notes, and 19,000 DNBI surveys indicates that caries accounted for 22.5% of the dental emergency visits, pulpal disease requiring endodontic (root canal) therapy accounted for 20%, and visits associated with wisdom teeth (third molars) accounted for 4.2%. This data, in combination with the large numbers of one dental officer clinics, indicates that every dental officer must be proficient in endodontic and exodontia diagnosis and treatment. There is evidence that Dental Fitness Category 3 definitions should be revised.

The US Army Dental Command (DENCOM) first fielded the Corporate Dental Application (CDA) in 1999 and completed full implementation throughout all DENCOM dental treatment facilities in 2000. Initially, the CDA focused on the collection of dental workload information or dental weighted values which were based on the Department of Defense (DoD) dental procedure codes. Dental providers entered treatment workload into the CDA and recorded treatment notes, treatment plans, and other information on paper dental records. In subsequent years, the CDA was enhanced to capture data on patient treatment needs, caries risk, and tobacco use. In 2006, a narrative capability was added to the CDA which enables providers to type treatment notes into the CDA. Further development of the CDA was halted as resources were focused on AHLTA\*-dental as an electronic dental record (EDR). The Army Medical Command stopped the fielding of AHLTA-dental on November 1, 2009.<sup>1</sup> Following the cancellation, the Military Health System (MHS) planned to evaluate both AHLTA-dental and CDA for the comprehensive military EDR.<sup>2</sup> CDA is included in the evaluation process because a version of CDA is currently deployed in Army and Air Force dental clinics, CDA is in alignment with future EDR requirements and strategies, and CDA has some capabilities that are not supported by AHLTA. Until a final agreement is made by all 3 services, paper records will continue to be the standard of care in fixed facilities.

\*AHLTA is the current US military electronic medical record.

Historically, theater-wide dental emergency and dental treatment data had not been collected from a deployed environment. Previous deployed dental treatment and dental needs studies were based on small sample sizes that may not have been representative of the entire patient population.<sup>3</sup> Multiple articles were published based on dental records maintained by a single dentist or small group of dentists.<sup>4-6</sup> In 1997, the Naval Dental Research Institute gathered data on dental treatment provided to US Marines in Desert Storm via a retrospective study of available temporary dental records.<sup>7</sup>

There are various legitimate reasons for the failure to collect auditable dental data on a sizeable sample population in a deployed environment. The technology to electronically capture such data was not available until the advent of the CDA. In 2003, the 502nd Medical Company (Dental Services) deployed to Iraq. At that time, Iraq was an immature theater of operations. The focus of the 502nd and other deployed dental providers was to provide emergency dental care in an austere environment using field portable dental equipment. Dental officers did not have the technology or internet capability to electronically record and capture dental workload or treatment needs data.

In 2005, the 502nd Medical Company (Dental Services) was redesignated as the 502nd Dental Company Area Support (DCAS) and became a direct

## Use of the Army Dental Command Corporate Dental Application as an Electronic Dental Record in the Iraq Theater of Operations

reporting unit (DRU) to the 1st Medical Brigade. In October of 2005 the 502nd deployed to Iraq as a DRU to the Medical Task Force (TF MED) under the command and control of the 30th MED BDE. The 502nd occupied fixed dental clinics with established internet capability. The 502nd DCAS dutifully recorded dental workload in the CDA and maintained paper dental records in accordance with established policy. The dental records were offered to the unit or to the individual Soldier. It was not practical for the 502nd to maintain copies of the records for epidemiologic reasons, therefore, the 2006-2007 dental records cannot be retrieved for a retrospective study. Record audits were not performed. It is probable that not all of the in-theater dental workload was annotated in the CDA.

The 502nd deployed to Iraq as a direct reporting unit to the TF MED from June 25, 2009, to June 4, 2010. The mission of the 502nd was to “Envision, design, and maintain the highest quality patient care system for eligible beneficiaries while planning and executing the orderly transition of dental resources to an expeditionary HSS [Health Support System]. Support 1st Medical Brigade efforts to facilitate long-term, sustainable Iraqi health care delivery.” One of the 5-unit Mission Essential Task List items was “Electronically collect patient treatment and treatment needs data.” Coincidentally, DENCOM added an electronic disease and nonbattle injury (DNBI) survey form to the CDA in April 2009 as part of an effort to obtain detailed information on DNBI in a deployed environment.

In order to achieve an Army Dental Care System unity of effort for data collection, DENCOM incorporated several minor changes in the CDA which were designed to support the collection and analysis of dental data from a deployed environment. Prior to June 2009, CDA data for deployed providers was collected and “sorted” according to the parent unit of the clinician; not geographic location of the dental clinic. The various organizations from multiple theaters were listed in the DEPRDC (deployed; non-DENCOM clinics) section of the CDA data. Listed units included those currently deployed and units which had

redeployed. Those units included multiple medical companies (dental services), combat support hospitals, area support medical companies, and brigade combat teams.

Dental data collected “by unit” could not be easily assigned to an area or geographic location, such as a forward operating base (FOB). In addition, it was not uncommon for more than one dental organization to have treatment teams at a single FOB. The inability to quickly and accurately assign dental workload to a particular location made it difficult for medical planners at the theater or task force level to objectively and equitably distribute dental assets in-theater. The CDA became a valuable tool for medical planners as data for deployed providers became retrievable in the same fashion as data from DENCOM dental treatment facilities (DTFs), individual providers, the DTF (geographic location), and region (theater of operations). Brigade combat teams and medical units with dental providers continued to have the ability to collect data for their respective providers.

The lack of a uniform theater policy for using the CDA to collect dental data meant that objective data was not available for use to request and justify dental resources for the theater based on patient demand. The 502nd sought to establish a policy to mandate the use of the CDA as an electronic dental record. The commander of the 1st Medical Brigade supported the concept. Prior to deployment, it became policy for all TF MED dental providers to use the CDA as an electronic dental record in lieu of paper dental records. This policy also mandated the use of the electronic DNBI survey for all military dental emergencies.

In cooperation with DENCOM, the 502nd developed written guidelines based on *Army Regulation 40-66*<sup>8</sup> and *Technical Bulletin MED 250*<sup>9</sup> for the utilization of the CDA as an electronic record. The process and standards were established to ensure that all providers would know the process to use the CDA as an electronic dental record. The first group (26 PROFIS\* dental officers from the 502nd DCAS) was trained to the new standard prior to deployment. The TF 1st

\*PROFIS predesignates qualified Active Duty health professionals serving in Table of Distribution and Allowance<sup>†</sup> units to fill Active Duty and early deploying and forward deployed units of Forces Command, Western Command, and the medical commands outside of the continental United States upon mobilization or upon the execution of a contingency operation.<sup>10</sup>

†Prescribes the organizational structure, personnel and equipment authorizations, and requirements of a military unit to perform a specific mission for which there is no appropriate table of organization and equipment (the document which defines the structure and equipment for a military organization or unit).

MED, with the 502nd, had command and control of 85% of the dental assets in the Iraq theater. Clinician education in the CDA and electronic record process refinement were immediate priorities. To ensure compliance with this policy and to maximize the reliability of collected dental data, it was decided to audit 100% of the CDA electronic patient encounters submitted. Clinician compliance with the electronic dental record policy, the quality of the data, and practical application of the data were readily apparent after the first month.

On September 1, 2009, the Multi-National Corps-Iraq (MNC-I) adopted the TF 1st MED policy. The Dental Services appendix to the Medical Services Annex of MNC-I Operations Order 09-09\* stated that “Dental treatment documentation and accountability of all dental procedures provided for active duty service members and other beneficiaries will be recorded on the CDA...website.” This policy applied to all dental providers in theater. Army dental officers assigned to brigade combat teams, and USN and USAF dental officers working in Army facilities quickly complied with this new policy. To ensure compliance and maximize the reliability of collected dental data, it was decided to audit 100% of the CDA electronic patient encounters submitted in the Iraq theater of operations. These “audits” were conducted by the 502nd DCAS Commander, who also served as the Theater Dental Consultant (TDC).

An audit process was designed using the concepts taught by the US Army Medical Command Lean Six Sigma program.<sup>†</sup> A senior dental noncommissioned officer (NCO) first reviewed each CDA encounter within 48 hours of the treatment submission. There were several areas of interest:

- Did the annotated DoD procedure codes, which captured the dental workload value, match the treatment narrative?
- Were all A0199 coded emergency visits accompanied by an electronic DNBI survey form?
- Were emergency dental exams, DoD procedure code D0140, written in SOAP format (symptoms, observations, assessment, prognosis)?

\*Internal military document not generally accessible by the general public.

†Information available at: <http://www.armyobt.army.mil/cpi-kc-tools-iss.html>.

- Was there a treatment plan recorded for each non-emergency dental exam (DoD procedure code D0120)?
- Was the appropriate biographical data entered for each patient?

The number of daily patient encounters entered into the CDA ranged from 21 to 405, with a mean of 257 per day. The dental NCO required approximately 5 hours to review the daily encounters and record apparent discrepancies. The results of the preliminary audits were forward to the TDC. The TDC reviewed the audit results for each dental officer and then personally emailed each dental provider the results of the daily record audit. The number of patients treated and the value of the dental workload were also listed in the email. A member of the dental officer’s chain of command was provided a copy of the email correspondence between the TDC and individual dental officer. The overwhelming majority of the audits, more than 91%, stated “zero negative findings.” When discrepancies were noted, the dental provider was asked to make the appropriate correction. As part of the audit process, the dental record audit NCO would recheck the patient encounter to ensure the corrections were made. On the rare occasion when a correction was not submitted, the TDC would again email the provider. The TDC spent approximately 75 minutes supporting the dental audit process.

The daily record audit has several advantages:

- Maximizes the probability of uniformity in dental workload reporting.
- Maximizes the probability that all dental workload is captured by providers.
- Provides an opportunity to contact all theater dental providers daily and provide positive feedback.
- Enhances the reliability of collected data.

Over an 11-month period (July 1, 2009 to May 31, 2010), dental officers in Iraq recorded in the CDA more than 56,000 patient encounters (visits) and 190,000 procedure codes, with a value of \$17.7 million. More than 19,000 of these encounters were defined as emergency visits and were accompanied by DNBI surveys. It is estimated that the CDA and DNBI data captured more than 97% of the dental patient



## Use of the Army Dental Command Corporate Dental Application as an Electronic Dental Record in the Iraq Theater of Operations

encounters in Iraq during this period. The 97% calculation is based on patient encounters and workload recorded by 2 USAF dental clinics using the USAF version of the CDA. The USAF data did not include treatment notes or DNBI data. The USAF dental production data was incorporated into the monthly dental reports to the MNC-I Surgeon.

The validated dental data was used during the deployment by the TDC and TF MED 502nd to equitably distribute dental resources during the deployment. There were several reasons that a redistribution of dental assets was necessary. Military and other dental beneficiary populations on the various installations continually fluctuated due to troop restationing plans, as well as retrograde operations in support of the responsible drawdown of forces in Iraq. It was often necessary to backfill dental personnel. Dental personnel were redeployed early from theater for a variety of reasons and personnel replacement times ranged from one to 3 months. Dental personnel who used the rest and recuperation leave program were absent from their clinic for approximately 3 weeks. As the troop levels decreased, accompanying productivity and patient needs data justified eliminating several dental officer PROFIS requests generated by non-DCAS units.

For the first time, reliable and auditable dental data on a valid, representative sample of the entire population is available to medical manpower analysts. The Army Medical Department (AMEDD) Strategic Studies Branch stated that the “dataset provided for the dental health project (through the use of electronic dental records and electronic DNBI surveys) is by far one of the cleanest, most complete datasets encountered in years.” It is anticipated that medical planners at the AMEDD and Army Command levels can use this data to objectively establish dentist, dental ancillary, and dental equipment requirements for a deployed patient population based on patient needs and potential risk. The data clearly indicates that the dental treatment of nonmilitary beneficiaries must be considered by medical planners. The data reveals that deployed dental treatment facilities are significantly more efficient when the assistant to dental officer ration is greater than 1:1. Many 502nd DCAS and TF 1st MED DTFs had a 1:1 plus one staffing ratio. The “plus one” is an additional assistant available to perform reception, administrative, and instrument sterilization duties, as well as chairside assistance. These 1:1+1

clinics produced 38% more procedures per dentist than DTFs with a 1:1 ratio.

Dental data from any theater and time period should be normalized to account for difference in the assigned mission, theater policies, staffing ratios for dentists and their ancillaries, and theater infrastructure. Data collected by the TF MED providers during this period includes prophies (dental cleanings) comprising 14% of the nonexamination dental procedures. TF MED policy was that all dental providers spend 40 to 44 hours a week providing hands-on patient care. This policy increased the amount of routine dental care provided to Soldiers on a space available basis. This policy contributed to increased levels of Soldier dental wellness, enhanced patient morale, and enhanced unit morale as TF MED Soldiers stayed busy and productive in-theater.

In 32 various after-action reports, deployed dental officers made recommendations for changes to the current DoD definitions of Dental Fitness Category (DFC) 3. DFC3 is defined as a high risk for a dental emergency within 12 months. An examination of 19,000 DNBI surveys and 56,000 electronic dental records may provide the scientific justification for the proposed additions to DFC3 definitions:

1. Endodontically obturated posterior tooth without cuspal coverage. Currently, DoD Health Affairs (HA) Policy 02-011<sup>11</sup> lists DFC2 for “teeth restored but for which protective cuspal coverage is indicated.”
2. Partially erupted wisdom teeth which will not erupt into occlusion. Currently HA Policy 02-011, lists DFC3 only if “historical, clinical, or radiographic signs of pathosis.”
3. All interim restorations or prosthesis. Current DFC3 definition is “interim restorations or prosthesis that cannot be maintained for a twelve month period.”
4. A Soldier with more than 6 DFC2 lesions.
5. A Soldier with orthodontic brackets and wire.
6. A high-carries-risk Soldier with interproximal posterior composite restorations.

The data from the DNBI surveys completed between July 1, 2009, and 30 June 30, 2010, are listed in Tables 1 through 8 and presented in the Figure (page 53).

There were 16,084 military personnel DNBI encounters recorded, with a total of 19,084 recorded DNBI encounters in this period. Unfortunately, the MNC-I policy to collect dental emergency data and DNBI surveys applied only to military personnel. Some dental providers took it upon themselves to record nonmilitary DNBI data.

The gender and component of the military personnel who sought emergency dental treatment are shown in Tables 1 and 2 respectively. Emergency encounters were collected under the code “A0199 emergency visit-problem focused” found in the DoD Guidelines for Dental Procedure Codes and Dental Weighted Values.<sup>12</sup> According to this code, providers are to take credit only once per each unscheduled visit to a dental facility, regardless of the reason for which the patient sought expedited care. It is obvious that males were the predominate group that sought treatment of dental emergencies. However, without theater-wide personnel data on the component and gender composition of US forces in Iraq during this period, which component and gender was statistically more prone to seek treatment for a dental emergency cannot be determined. Gender, component, and age data should indicate which group of Soldiers should be the main target audience for preventive dental messages.

The DNBI survey also tracked the number of months that the Soldier had been deployed when the Soldier sought emergency dental care. Conventional wisdom is that dental emergency rates increased as the deployment dwell time increased. The data collected during this period does not support this conventional hypothesis. The number of months a patient had been deployed when he or she sought emergency dental treatment are shown in Table 3, and percentages for the deployment period are shown the Figure. There appears to be an initially high dental sick call rate in the first month of deployment and another peak at the 7-month mark. There are several potential explanations for the findings. One potential explanation is that Soldiers arrive with untreated dental emergencies. Another explanation is sequela from dental treatment just prior to deployment. Using CDA data, further investigation is warranted. Data on the average dwell time for these patients is needed. It is possible that in-theater dental sick-call rates are directly related to the amount of time since the Soldier's last dental exam. Soldiers who deployed in December 2008 may have had their last dental exams anytime between December 2007 and

Table 1. Dental emergency encounters by gender.

Gender	Encounters	Percentage
Male	13,572	84.38
Female	2,512	15.62

Table 2. Dental emergency encounters by military service.

Component	Encounters	Percentage
Army Active Duty	9,036	56.18
Army National Guard	3,977	24.73
Army Reserve	1,912	11.89
Air Force	720	4.48
Navy	289	1.80
Marine Corps	150	0.93

Table 3. Dental emergency encounters by number of months deployed.

No. of Months in Theater	Emergency Visits	Percentage of Emergency Visits per Deployed Month	Cumulative Percentage of Emergency Visits
1	2,377	14.8	14.8
2	949	5.9	20.7
3	1,090	6.8	27.5
4	1,152	7.2	34.6
5	1,322	8.2	42.8
6	1,229	7.6	50.5
7	1,627	10.1	60.6
8	1,508	9.4	70.0
9	1,265	7.9	77.8
10	1,047	6.5	84.3
11	1,070	6.7	91.0
12	903	5.6	96.6
13	299	1.9	98.5
> 13	246	1.5	100.0

Table 4. Etiology of dental chief complaint.

Etiology of Chief Complaint (Primary Classifications)	Frequency of Diagnosis	Percentage
Enamel, dentin, or restoration	11,947	48
Pulpal disease	4,860	20
Dentoalveolar surgery or 3rd molar	3,249	13
Periodontal disease	2,169	9
Other dental conditions	1,008	4
Temporomandibular disorder	805	3
External trauma	603	2
Totals	24,641	100

## Use of the Army Dental Command Corporate Dental Application as an Electronic Dental Record in the Iraq Theater of Operations

December 2008. Other potential factors influencing dental sick-call include, but are not limited to, the patient's, caries risk, oral hygiene, and the number of untreated DFC2 dental lesions.

Tables 4 through 8 reveal the etiology of the patient's chief complaint and the multiple etiology subsets. As part of the DNBI survey, more than one etiology could be applied to a visit. The most notable findings were that caries accounted for 22.5% of the dental emergency visits, pulpal disease requiring endodontic (root canal) therapy accounted for 20%, and visits associated with wisdom teeth (third molars) accounted for 4.2%. The data, in combination with the large numbers of single dental officer clinics, indicates that every dental officer must be proficient in endodontic and exodontia diagnosis and treatment. The complexity of many third molar extractions combined with the standard of care to provide sedation therapy for many of these patients confirms the theater need for a oral and maxillofacial surgeon to support third molar exodontias requirements. The alternative is the evacuation of military personnel from theater for complications from erupting third molars.

In a deployed environment, the CDA as an electronic dental record and electronic DNBI surveys proved a significant improvement over paper records and surveys. The low record audit error rate indicates that dental officers will use a clinician friendly electronic record, and that dental officers are aware of the Army Dental Care System requirement to collect accurate dental data. There is room for improvement. Dental record audits could be conducted from a location in the United States. A triservice electronic dental record should be adopted to ensure all dental data is collected and treatment notes are accessible to home duty station military DTFs and postdemobilization nonmilitary dental providers. Until a triservice solution is adopted, CDA as an electronic dental record should be the standard of care for deployed providers. DENCOM is studying potential modifications and improvements to the CDA. In October 2010, an electronic exam form or mass event module was added for use at first term dental readiness and Soldier readiness processing sites. The potential baseline data from an electronic dental exam for dental treatment needs could further refine dental manpower and equipment requirement justifications in both the deployed and fixed facility environments.

Table 5. Subset of enamel dentin restoration diagnosis.

<b>Etiology Subset 1 of 7 Enamel Dentin Restoration Diagnosis</b>	<b>Frequency</b>	<b>Percentage</b>
Fractured with caries	2,319	19.41
Hypersensitivity	2,262	18.93
Defective with caries	1,944	16.27
Caries	1,475	12.35
Defective without caries	1,349	11.29
Other	1,262	10.56
Hyperocclusion	988	8.27
Fractured without caries	348	2.91
<b>Totals</b>	<b>11,947</b>	<b>100.00</b>

Table 6. Subset of pulpal diagnosis.

<b>Etiology Subset 2 of 7 Pulpal Diagnosis</b>	<b>Frequency</b>	<b>Percentage</b>
Pulpitis	1,629	33.52
Pulpless/ previously treated	888	18.27
Necrotic pulp	618	12.72
Periapical abscess	578	11.89
Anatomic space infection	558	11.48
Other	505	10.39
Periapical periodontitis	84	1.73
<b>Totals</b>	<b>4,860</b>	<b>100.00</b>

Table 7. Subset of dental alveolar diagnosis.

<b>Etiology Subset 3 of 7 Dental Alveolar Diagnosis</b>	<b>Frequency</b>	<b>Percentage</b>
Alveolar osteitis (3-5 day postoperation)	1,104	33.98
Pericoronitis	1,003	30.87
Other	599	18.44
Sequestrum from previous extraction	190	5.85
Normal postoperation pain or swelling	184	5.66
Hemorrhage	109	3.35
Eruption pain	52	1.60
Anatomic space infection	8	0.25
<b>Totals</b>	<b>3,249</b>	<b>100.00</b>

Table 8. Subset of periodontal diagnosis.

<b>Etiology Subset 4 of 7 Periodontal Diagnosis</b>	<b>Frequency</b>	<b>Percentage</b>
Gingivitis/Gingival Bleeding	931	42.92
Other	747	34.44
Necrotizing Ulcerative Gingivitis	420	19.36
Ailing/Failing Implant	36	1.66
Periodontal Abscess	25	1.15
Anatomic Space Infection	10	0.46
<b>Totals</b>	<b>2,169</b>	<b>100.00</b>



## ACKNOWLEDGEMENT

The authors thank the US Army Dental Command and the Dental Staff at the Office of The Surgeon General for their superb level of support to the Soldiers of the 502nd DCAS during the deployment.

## REFERENCES

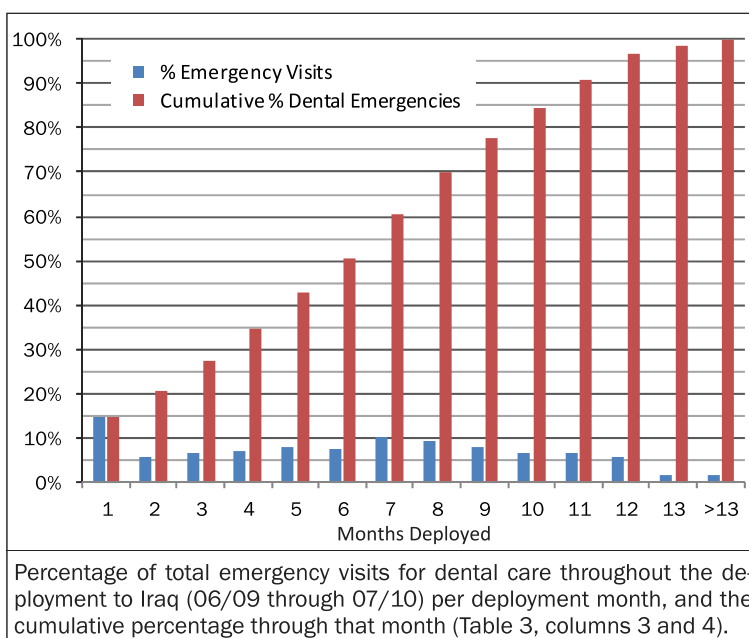
1. Brewin, Bob. Army abruptly stops rollout of electronic dental record application. *Government Executive.com* [serial online]. November 3, 2009. Available at: <http://www.govexec.com/dailyfed/1109/110309bb1.htm>. Accessed November 15, 2010.
2. Brewin, Bob. Military Health to evaluate two electronic dental record systems. *Government Executive.com* [serial online]. November 25, 2009. Available at: [http://www.nextgov.com/nextgov/ng\\_2009/1125\\_6460.php](http://www.nextgov.com/nextgov/ng_2009/1125_6460.php). Accessed November 15, 2010.
3. Eikenberg S, White K. Report of dental emergencies treated by the 257th Medical Company (Dental Service) in Haiti during Operation Uphold Democracy. *Army Med Dept J*. September-October 1995:17-21.
4. Tewles RB, King JE. Impact of troop dental health on combat readiness. *Mil Med*. 1987;152(5):233-235.
5. Chaffin J, King JE, Fretwell LD. U.S. Army dental emergency rates in Bosnia. *Mil Med*. 2001 (12);166:1074-1078.
6. Moss DL. Dental emergencies during SFOR 8 in Bosnia. *Mil Med*. 2002;167(11):904-906.
7. Deutsch WM, Simecek JW. Dental emergencies among Marines ashore in Operations Desert Shield/Storm. *Mil Med*. 1996;161(10):620-623.
8. *Army Regulation 40-66, Medical Record Administration and Health Care Documentation*. Washington, DC: US Dept of the Army; June 17, 2008.
9. *Technical Bulletin MED 250: Dental Record Administration, Recording, and Appointment Control*. Washington DC: US Dept of the Army; April 28, 2006.
10. *Medical Corps Professional Development Guide*. Fort Sam Houston, TX: US Army Medical Department Center and School; March 2002:27.
11. Assistant Secretary of the Army for Health Affairs. Memorandum: Policy on Standardization of Oral Health and Readiness Classifications. Washington, DC: US Dept of the Army; June 4, 2002. Available at: <http://www.ha.osd.mil/policies/2002/02-011.pdf>. Accessed October 28, 2010.
12. *Guidelines for Dental Procedure Codes and Dental Weighted Values*. Falls Church, VA: Tricare Management Activity, US Dept of Defense; October 1, 2009.

## AUTHORS

COL Eikenberg is Commander, 502nd Dental Company (Area Support), Fort Hood, Texas.

MAJ Keeler is Deputy Commander for Clinical Services, 502nd Dental Company (Area Support), Fort Hood, Texas.

SFC Green is the Treatment Platoon Leader, 502nd Dental Company (Area Support), Fort Hood, Texas.



# Dental Readiness of Army Reserve Components: A Historical Review, Part Two

COL Mark B. Bodenheimer, DC, USAR

## INTRODUCTION

In a previous article in the *AMEDD Journal*,<sup>1</sup> I presented a historical review of dental readiness of the Army Reserve components from 1968 to the end of September 2005. This article focuses on the progress of dental readiness for the Army Reserve components (RC), which consist of the Army National Guard (ARNG) (component 2) and the US Army Reserve (USAR) (component 3), for the period October 2005 through September 2010. During this period, the US Army Dental Command (DENCOM) processed over 192,000 ARNG and 88,000 USAR Soldiers through mobilization stations. The dental-ready report rate to the mobilization station for ARNG Soldiers improved from 56% to 86%, and that for USAR Soldiers improved from 36% to 64%. These improvements reduced dramatically the “just in time” dental exams and treatment that had historically been performed at mobilization stations in order to deploy dentally fit Soldiers. In August 2008, DENCOM initiated the RC Demobilization Dental Reset which, through the end of Fiscal Year (FY) 2010, had examined and treated over 141,000 RC Soldiers and reset 92% of them to the dental deployment standard before their release from active duty status. Through the implementation of programs and electronic processes described in this article, the RC baseline dental readiness as identified by the Army Medical Protection System improved from approximately 42% dental-ready in FY 2006 to approximately 71% dental-ready by the end of FY 2010.

## HISTORICAL PERSPECTIVE

By the end of FY 2005, RC dental-ready report rates to mobilization platforms had improved to 56% for the ARNG and 36% for the USAR, from 13% dental-ready at the beginning of FY 2004. In November 2005, MG Joseph G. Webb, Chief of the Dental Corps and Deputy Surgeon General, directed the creation of the Dental All Army Working Group (DAAWG) to continue the improvement in dental-ready report rates

and foster cooperation among the dental stakeholders of the three Army components. This group consisted of dental surgeons from the Army National Guard Bureau (NGB), the Army Reserve Command, the Office of The Army Surgeon General (OTSG), and the DENCOM. This core group of stakeholders would be instrumental in directing the future paradigm shifts in RC dental readiness. Two issues had to be addressed: (a) the development of an all Army synchronized electronic dental database which would improve dental readiness validation processes at mobilization stations; and (b) an Army directed and funded RC dental readiness program that operates outside of alert status which would improve baseline RC dental readiness, leading to dental-ready RC Soldiers presenting to mobilization installations.

## SYNCHRONIZED ELECTRONIC DATABASES

In the absence of an Active Component (AC) electronic dental record, by 2006 the NGB dental surgeon's office had developed DENCLASS, an electronic dental record and dental readiness tracking system. At the same time, the DENCOM Information Management and Technology Division (IM&TD) had developed and implemented the Digital Enterprise Viewing and Acquisition Application (DEVAA) for use within the Active Army Dental Care System (AADCS). DEVAA permitted the standardized storage of digital radiographs, regardless of sensor type used by any dental treatment facility within the AADCS. By June 2007, IM&TD began development of the Army Dental Digital Repository (ADDR) to which DEVAA images taken at local dental treatment facilities could be uploaded, permitting viewing of dental digital radiographs worldwide. At the same time, images taken by the Federal Strategic Health Alliance (FEDS\_HEAL), a primary provider network performing premobilization RC dental readiness exams, radiographs, and treatment, started transmitting digital radiographs to the ADDR. By early 2008, the USAR started using DENCLASS for their electronic dental

record. This initiated a series of DENCLASS improvements which permitted radiographs and electronic examination records produced by the Reserve Health Readiness Program (which replaced FEDS\_HEAL) or direct contracted networks to be placed into the ADDR using DENCLASS as the entry portal. This improved Soldier Readiness Processing (SRP) validation at mobilization stations when paper records were lost or incomplete. In early 2009, the DAAWG directed that all RC dental readiness data must be placed into the ADDR through the DENCLASS portal starting October 1, 2009. In early 2010, the DAAWG directed that a digital panograph would be on file in the ADDR for all Army Soldiers starting October 1, 2010. DENCLASS also had portal links to the DENCOM Corporate Dental Application (CDA) database, allowing RC contracted entities to see radiographs and dental record documentation, regardless of whether that data was produced by the RC dental readiness system and recorded in DENCLASS or was produced within the AADCS and recorded in CDA. These improvements gave new tools to all three components to reduce duplication of examination and radiograph processes.

The foundation had been laid for the three Army components to synchronize their electronic dental databases. The fact that the AC and RC databases were not synchronized by a common electronic dental record posed a significant challenge. All databases were awaiting full development of an AHLTA\* electronic dental record. In late 2009, a strategic pause was ordered for the AHLTA electronic dental record throughout Department of Defense (DoD) dental treatment facilities. However, the AADCS required an electronic examination document that was simple to use for mass events, such as the RC demobilization dental reset. In early 2010, the DAAWG agreed to an aggressive October 1, 2010 deadline to produce an AADCS electronic examination document for mass events, and to synchronize all databases in order to produce an RC electronic dental SRP validation system. A CDA program team developed the Mass Event Module (MEM), creating an electronic dental examination record which recorded charting of disease, diagnosis,

treatment procedures required, and the Dental Readiness Class (DRC) of a Soldier. By August 2010, the MEM was tested and released for system-wide implementation for RC mobilizations and demobilizations. The use of the MEM eliminated multiple paper record processing steps required to place data into the ADDR, and provided more accurate, standardized examination documentation for the RC.

Another CDA program team tackled synchronizing the databases to produce an electronic dental SRP validation process. By 2009, the DAAWG realized that the way dental data was fed to the Army's Medical Protection System (MEDPROS), which reports the medical and dental readiness of AC and RC individuals or units, lacked data integrity. Nondental unit personnel with MEDPROS write-access could change dental readiness data without any electronic dental data input or paper proof of dental readiness. In addition, CDA and DENCLASS were sending dental data to MEDPROS independent of each other, which led to system overwrites of DRC status and exam dates. Thus, paper records were required at the mobilization station in order to verify one source of information. By late 2009, the DAAWG agreed to a circular system of data flow, illustrated in Figure 1, which could only be accessed and changed by authorized AC or RC dental personnel using either

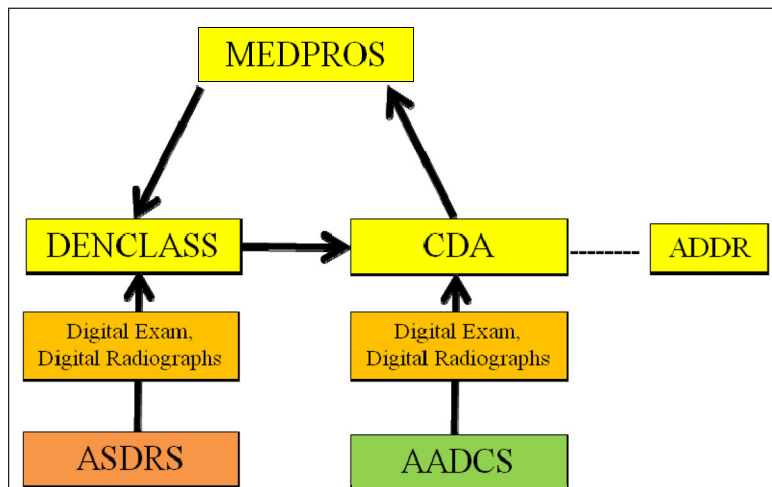


Figure 1. Clinical dental readiness data synchronization.

Glossary

MEDPROS - Army Medical Protection System

CDA - Army Dental Command Corporate Dental Application

ADDR - Army Dental Digital Repository

DENCLASS - Army National Guard electronic dental record and dental readiness tracking system

ASDRS - Army Selected Reserve Dental Readiness System

AADCS - Active Army Dental Care System

\*AHLTA is the current US military electronic medical record.



## Dental Readiness of Army Reserve Components: A Historical Review, Part Two

CDA or DENCLASS. In December 2009, MEDPROS access was limited to dental personnel with write-access in DENCLASS or CDA, which led to an immediate improvement in dental readiness data quality. Then, by August 2010, the single pathway flow of dental readiness data was developed whereby CDA became the entry point for all dental data to MEDPROS. Data produced by DENCLASS would update CDA, which in turn would update MEDPROS. Data first entered into CDA would then update MEDPROS and then update DENCLASS. With a single pathway flow of real-time dental readiness data, 6 common data elements could be used to electronically determine if a RC Soldier could be validated as dental-ready without the use of paper dental records. The RC electronic dental SRP validation process was tested in September 2010 and fully implemented throughout DENCOM operated mobilization and demobilization stations on October 1, 2010. The RC Soldier's dental readiness status could now be validated electronically using trusted electronic dental data.

### PROGRAMMATIC RC DENTAL READINESS SYSTEM

By 2005, dental examinations and DRC 3 treatment at no charge to the RC Soldier were based on the RC Soldier's alert for mobilization. Outside of this alert status, no dental readiness program was available for RC Soldiers. Dental readiness care was being delivered by FEDS\_HEAL for the USAR and by FEDS\_HEAL and direct contractors for the ARNG. By 2007, DoD directed the creation of a contracted medical and dental readiness provider network for the RC, the Reserve Health Readiness Program (RHRP), to replace FEDS\_HEAL. After the RHRP contract was approved in September 2007, the RHRP DoD representative became a sitting member of the DAAWG. In the meantime, the Army leadership was developing the Armed Forces Generation cycle (ARFORGEN), a rotational plan involving pools (reset/train; ready and available) of Army AC and RC units. However, except for Soldiers in the alert status of the ARFORGEN available pool, there was no Army directed RC dental readiness program. In December 2006, the OTSG Dental Staff Officer (action officer), COL James Honey, focused the DAAWG to work toward an Army directed dental readiness system which would provide annual exams and DRC 3 treatment throughout the ARFORGEN cycle. This

system would require an electronic database for dental readiness tracking and authorization to use RC Operation and Maintenance funding to purchase contract dental readiness care at home station. The necessary authorization for funding was made possible in January 2007 when the Secretary of Defense directed that RC mobilizations would be limited to one year. This meant that RC units did not have the luxury of staying at the mobilization platform for 60 to 120 days prior to deployment but would now be deployed within 30 to 60 days of arriving at the mobilization station. Consequently, in February 2008, the Assistant Secretary of the Army, Manpower & Reserve Affairs (ASA-M&RA) issued a policy stating that all Selected Reserve Soldiers would deploy within 75 days of mobilization. All Selected Reserve Soldiers would now qualify as "early deployers" and therefore be entitled to dental readiness care in accordance with existing Federal law, 10 USC, §1074a (d)(1). This policy provided key support for the ongoing staffing process to create the Army Selected Reserve Dental Readiness System (ASDRS). In April 2008, the ASDRS was staffed through Headquarters, Department of the Army in preparation for final approval through ASA-M&RA. At the same time, the Army's Chief of Staff also focused on Army Initiative Four to "operationalize" the Reserve component forces. Within his first 100 days as Army Surgeon General, LTG Eric Schoomaker directed a complete review of RC dental readiness. The Assistant Surgeon General for Force Projection assembled a multicomponent work group in March 2008 to conduct a capabilities-based assessment and develop a prioritized list of courses of action. In April 2008, I testified before the Subcommittee on Oversight and Investigations of the House Armed Services Committee,<sup>2</sup> outlining the history of RC dental readiness and initiatives that were being reviewed by the Army leadership. Proposed initiatives included the expansion of the existing First Term Dental Readiness program, establishment of paid dental readiness days for the RC, creation of an Army Selected Reserve Dental Readiness System (ASDRS), development of an enhanced TRICARE\* dental program, and introduction of a demobilization reset. By May 2008, the Army's Vice Chief of Staff directed the dental reset of the RC forces upon demobilization, and by August 2008, DENCOM implemented the

\*TRICARE is DoD's health care program for members of the uniformed services, their families, and their survivors. Information available at <http://www.tricare.mil>.

Reserve Components Demobilization Dental Reset. By September 2008, the ASA-M&RA approved ASDRS and issued a policy guidance memorandum which directed the Chief, Army Reserve and Director, Army National Guard to implement the ASDRS using base program readiness (operation and maintenance) funding. The memorandum included the requirement to achieve the DoD Health Affairs dental readiness policy standard<sup>3</sup> of 95% DRC 1 or 2 in support of all Selected Reserve Soldiers outside of alert for mobilization. ASDRS could use contingency funds for Ready Reserve Soldiers (Selected Reserve, Individual Ready Reserve, and Inactive National Guard) once they are alerted (and called or ordered to active duty for a period of more than 30 days), in accordance with 10 USC, §1074a (f)(1). By FY 2010, RC Soldiers were being provided paid medical/dental readiness days which compensated Soldiers' time off from their civilian jobs to achieve medical and dental readiness standards.

## SUMMARY

The multiyear RC dental readiness improvement initiative outlined in this article met the original 2 requirements of the DAAWG:

- A seamless system of RC dental readiness access (Figure 2) throughout the ARFORGEN cycle at no cost to the RC Soldier. The DENCOM-commanded AADCS has operational responsibility for the First Term Dental Readiness program when the RC Soldier is in initial entry training; mobilization/demobilization station dental readiness deployment care; and the RC Demobilization Dental Reset. The ASDRS, as directed through the Chief, Army Reserve and Director, Army National Guard, has operational responsibility for RC dental readiness throughout the ARFORGEN reset/train, ready, and available pools.
- A trusted, synchronized, electronic dental readiness validation and record system which reduces duplication of processes and improves mobiliza-

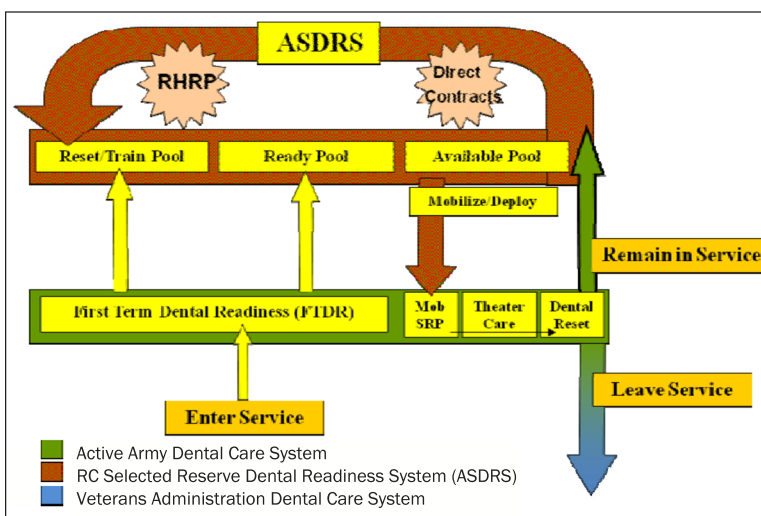


Figure 2. Army Reserve component Armed Forces Generation cycle dental readiness model. RHRP indicates Reserve Health Readiness Program.

tion station efficiencies. Future improvements in RC dental readiness will require continued improvements in electronic data system synchronization and RC command-directed implementation of the ASDRS.

## REFERENCES

1. Bodenheimer MB. Army Reserve components dental readiness: a historical review since the first gulf war. *Army Med Dept J*. January-March 2006;27-30.
2. *Challenges Associated with Achieving Full Dental Readiness in the Reserve Component: Hearings Before the Subcommittee on Oversight and Investigations of the House Armed Services Committee*, 110th Cong, 2nd Sess (April 23, 2008).
3. Assistant Secretary of Defense for Health Affairs. Memorandum: Policy on Oral Health and Readiness [HA Policy 06-001]. Washington, DC: US Dept of Defense; January 9, 2006. Available at: [http://www.health.mil/libraries/HA\\_Policies\\_and\\_Guidelines/06-001.pdf](http://www.health.mil/libraries/HA_Policies_and_Guidelines/06-001.pdf). Accessed November 23, 2010.

## AUTHOR

COL Bodenheimer is Chief of Reserve Components Operations, US Army Dental Command, and the Drilling Individual Mobilization Augmentee to the Dental Corps Chief, Fort Sam Houston, Texas.

# The 2008 Army Recruit Oral Health Survey Results

COL David L. Moss, DC, USA

## EXECUTIVE SUMMARY

This report presents the findings from an oral health survey of US Army recruits at time of entry into the armed services. The survey was conducted from December 2007 to November 2008. Prior to analysis, the sample of 1,928 Army recruits was weighted to represent the estimated total number of Army recruits attending basic training (171,348) during this period. Weighting factors included military service, gender, and military service status or component, thus allowing comparisons among Regular (Active Duty), Reserves, and National Guard recruits of each service. The distribution of the recruits by service:

- Army 57.1%
- Marines 15.2%
- Navy 15.1%
- Air Force 12.6%

The distribution of Army recruits by component:

- Regular 50.3%
- Reserve 16.8%
- National Guard 32.9%

The oral health findings were compared to results from the 1994 and 2000 Tri-Service Oral Health Recruit Studies where data were available.

## DoD Dental Fitness Classification

The percentage of recruits in Department of Defense (DoD) Dental Fitness Class (DFC) 3 was 52.5% compared to 42% in 2000 and 33.3% in 1994.

Only 4.3% of 2008 Army recruits did not require any treatment at the time of examination (DFC 1).

There was no statistical difference in the distribution of DFC among the 3 Army components.

## Treatment Needs

Almost all (84.3%) 2008 Army recruits needed an oral prophylaxis. While only 4.3% of Army recruits were DFC 1 at initial exam, an additional 6.7% would be DFC 1 after prophylaxis.

Operative needs were the most common area of dental treatment required for recruits. One quarter of recruits did not require any restorations and 21% required 7 or more restorations. The operative need of recruits was similar for all components. Mean number of restorations needed for each recruit was 3.7.

Seventeen percent of recruits required some fixed prosthodontic care, none were completely edentulous, and no removable partial dentures were indicated.

There was a significant improvement in the percentage of Army recruits who required no extractions (39.6%) in 2008 compared to 27.1% in 2000.

The status of 2008 recruits did not significantly change when compared to 2000 Army recruits. The percentage of 2008 recruits who had a worst periodontal screening and recording (PSR) score of 1 was 24.8% compared to 28% for year 2000 Army recruits.

Only 7.7% of 2008 recruits required any endodontic treatment, compared to 10.9% in 2000 and 18.1% in 1994.

## Dental Utilization

The percentage of 2008 Army recruits who had seen a dentist within the 12 months prior to reporting for training was 38.3% and increased to 66.5% within the previous 2 years.

The percentage of recruits who had some type of dental insurance before reporting to the recruit center was 44.3%.

---

This article is a reprint of the report, *2008 Army Recruit Oral Health Survey Results*, which is the US Army data from the 2008 DoD Recruit Oral Health Survey. The Army results and DoD report may be obtained through the Uniformed Services University of the Health Services, <http://www.usuhs.mil/tscchs/>.



## Perceived Need for Dental Care

The percentage of 2008 Army recruits who felt they needed dental care was 60.4%.

Among those who felt they needed dental care, 27.1% responded that they needed dental care “right away”, 41.5% “within 6 months.”

The most common reason for not seeking care prior to training was that it was too expensive.

## BACKGROUND

The TRICARE Management Activity directed the Tri-Service Center for Oral Health Studies with concurrence by the Services' Deputy Dental Corps Chiefs, to conduct the 2008 DoD Recruit Oral Health Survey. The primary goal of the survey was to estimate the level of dental readiness, oral health, and dental treatment needs of recruits entering military service. The results provide essential information for determining dental manpower requirements and other areas of readiness planning that are especially vital during wartime. Key objectives of the survey were to identify initial dental classification and specific dental treatment needs for recruits, determine dental caries prevalence, periodontal status and other oral conditions, evaluate levels of risk for dental caries, oral cancer, and periodontal disease, and describe results of the DoD Recruit Oral Health Survey Questionnaire. When possible, findings from this survey were compared to the 1994 and 2000 Tri-Service Comprehensive Oral Health Surveys.

## METHODS

For a detailed discussion on the methods used for the 2008 DoD Recruit Oral Health Survey, refer to the Methods section of the DoD report of the 2008 DoD Recruit Oral Health Survey (available at: <http://www.usuhs.mil/tscchs/>).

## SAMPLE DEMOGRAPHICS

A total of 1,928 Army recruits were examined at the five Army Basic Combat Training (BCT) sites from December 2007 thru November 2008 (Table 1).

Table 1. Distribution of study sample population across Army Basic Combat Training Locations

Basic Combat Training Location	Unweighted Sample	Estimated Population
Fort Benning	403	39,041
Fort Jackson	586	61,613
Fort Knox	202	19,246
Fort Leonard Wood	462	33,375
Fort Sill	275	18,073
Total	1,928	171,348

Table 2. Distribution of study sample population by component and gender.

Component	Male	Female	Overall
Active Army	42.4%	7.9%	50.3%
Army National Guard	26.2%	6.6%	32.9%
Army Reserve	12.0%	4.8%	16.8%
Total	80.6%	19.3%	100.0%

Table 3. Distribution of study sample population by pre-enlistment education.

Component	Non-high school graduate	High school graduate	Post high school studies	2 year degree	4 year degree and beyond
Active Army	0.8%	33.8%	11.5%	2.2%	2.0%
Army National Guard	1.4%	21.7%	7.9%	1.0%	0.9%
Army Reserve	0.6%	9.6%	4.9%	0.7%	1.1%
Total	2.8%	65.1%	24.2%	4.0%	4.0%

Table 4. Distribution of study sample population by age.

Component	Age						
	17	18-19	20-24	25-29	30-34	35-39	40 & up
Active Army	3.2%	20.8%	18.8%	5.0%	1.4%	0.8%	0.2%
Army National Guard	3.1%	13.5%	10.9%	3.1%	1.2%	0.9%	0.2%
Army Reserve	1.1%	6.3%	6.2%	1.5%	0.9%	0.6%	0.2%
Total	7.4%	40.4%	36.0%	9.6%	3.6%	2.2%	0.6%

The component distribution of the sample is presented in Table 2. The numbers were weighted in order to adjust the sample to the actual population distribution of the 2008 recruit total.

Tables 3 and 4 present the sample population distribution by pre-enlistment education levels and age. The

## The 2008 Army Recruit Oral Health Survey Results

overall percentage of recruits without a high school education is 2.8% is likely an exaggeration due to National Guard recruits on a split entry option reporting for BCT prior to high school graduation.

### FINDINGS

During the dental examination, each recruit's DoD Dental Classification was calculated based upon the worst dental class assigned to each tooth, each PSR sextant, soft tissue finding, and temporomandibular disorder/orthodontic referral as noted by the study examiners.

Figure 1 shows the trend in DFC distribution over the 3 study years. The distribution of DFC did not differ significantly among the 3 Army components for the 2008 data.

Table 5. Number of restorations required for the 2008 recruit sample population.

None	1-3	4-6	7+
25.4%	34.0%	19.8%	20.9%

Table 6. Mean number of restorations by type for the 2008 recruit sample population.

1 Sur	2 Sur	3 Sur	4 Sur	5 Sur
1.53	1.40	0.57	0.17	0.05

Table 7. Distribution of DFC based only on operative needs of the sample population.

Study Year	DFC 1	DFC 2	DFC 3
2008	25%	33%	42%
2000	23%	51%	26%
1994	20%	50%	30%

This distribution among those that required at least one restoration was not statistically different across the 3 study years. The mean number of restorations by type for 2008 recruits is shown in Table 6.

This distribution also did not vary significantly across the 3 study years. The distribution of dental fitness class based solely on operative need for 2008 recruits is presented in Table 7.

### Oral Surgery Requirements

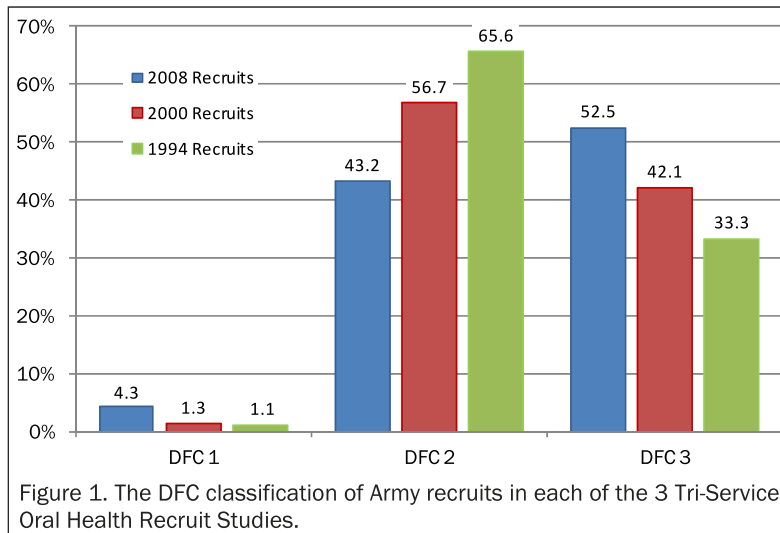
Among 2008 recruits, there was a significant decrease in the number of recruits who needed oral surgery treatment. In the 2000 study, 26.6% had no need. In the current study, this increased to 39.6%, as shown in Figure 2.

The average number of extractions among all 2008 recruits was 2.1.

Based only on oral surgery conditions, 39.6% of 2008 recruits were DFC 1, 35.1% DFC 2, and 25.4% were in DFC 3.

Among 2008 recruits that required at least one extraction, the majority required 3 to 4 teeth removed indicative of a treatment plan for the removal of all third molars. The mean number of extractions among this group by type was 0.9, 0.25, and 2.3 for simple, complex, and impacted, respectively.

There was no statistical difference for oral surgical need across the 3 components.



### Operative Need

Survey examiners assessed the health status and treatment needs of each tooth using standardized mirrors and explorers and current radiographs. Examiners were instructed to use a very light touch when using the dental explorer to avoid causing cavitation with aggressive probing.

The mean number of restorations needed for 2008 recruits was 3.7. The distribution of required restorations is shown in Table 5.

### Periodontal Health Status and Treatment Needs

Periodontal status and treatment needs were assessed using the Periodontal Screening and Recording (PSR) index. Survey examiners recorded the PSR score for each sextant of the dentition using the #23/Hu-Friedy WHO Style Expro (XP23/11.5B) explorer/periodontal probe.

Figure 3 shows the distribution of recruits by worst PSR score in each study year. The percentage of 2008

recruits whose worst PSR score is 3 or 4 (indicating periodontal disease) has decreased significantly from 55% in 1994 and 18% in 2000 to only 10% in 2008. Nearly 90% of 2008 recruits had a worst PSR score of 2 or lower.

The distribution of PSR scores was similar among the 3 components as shown in Figure 4.

### Prosthodontic Treatment

Survey examiners assessed the number of missing teeth and/or teeth requiring removal for each patient and made the determination whether to replace missing teeth using fixed or removable prostheses. Current use of partial or complete removable prostheses was assessed along with need for their replacement or repair.

Among 2008 recruits, only 17% required any fixed pros care, none were completely edentulous, and no removable partial dentures were indicated (Table 8). This compares to 24% and 34% requiring care in 2000 and 1994, respectively. The mean number of fixed pros units among those that required pros care was 2 units.

Table 8. Distribution of the number of fixed prosthodontic units needed by 2008 recruits.

Fixed Prosthodontic Units Needed				Mean Fixed Units (Per 1,000 Recruits)
None	1-2	3-6	7+	
82.8%	12.8%	3.8%	0.7%	366

### ENDODONTIC TREATMENT REQUIREMENT

The majority of endodontic need will be diagnosed acutely and not at routine examination. Survey examiners assessed the potential need for endodontic therapy using radiographs and visual inspection. Definitive vitality testing for suspect teeth was beyond the scope of this survey. If the examiner believed a tooth would require endodontic care following extensive restorative procedures, it was indicated in the record as needing endodontic care.

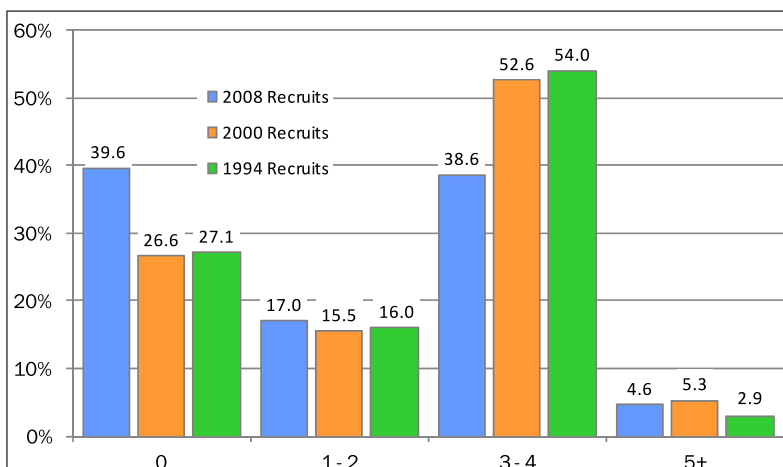


Figure 2. Distribution of Army recruits requiring oral surgery in each of the 3 Tri-Service Oral Health Recruit Studies.

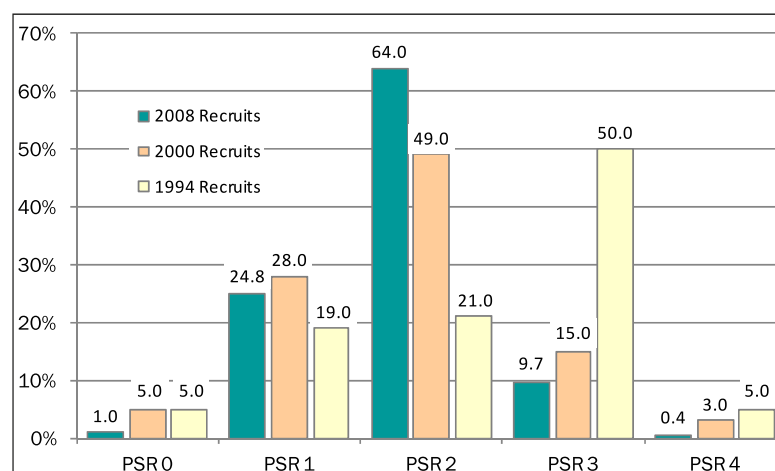


Figure 3. Distribution by Tri-Service Oral Health Recruit Study year of sample population periodontal screening and recording score (based on patient's worst sextant PSR score).

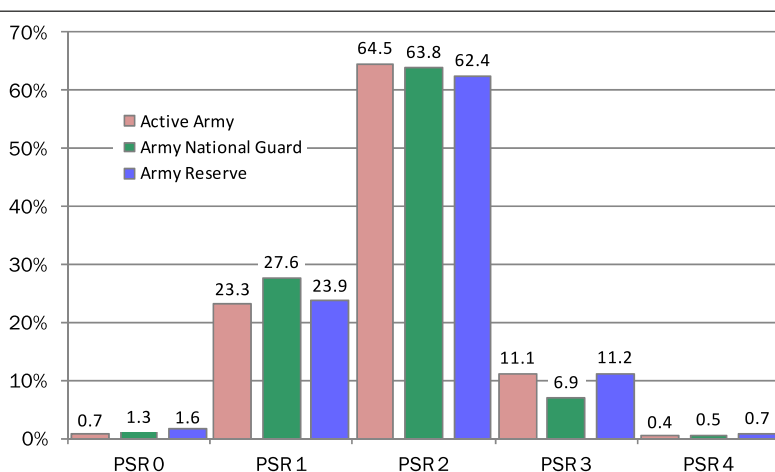
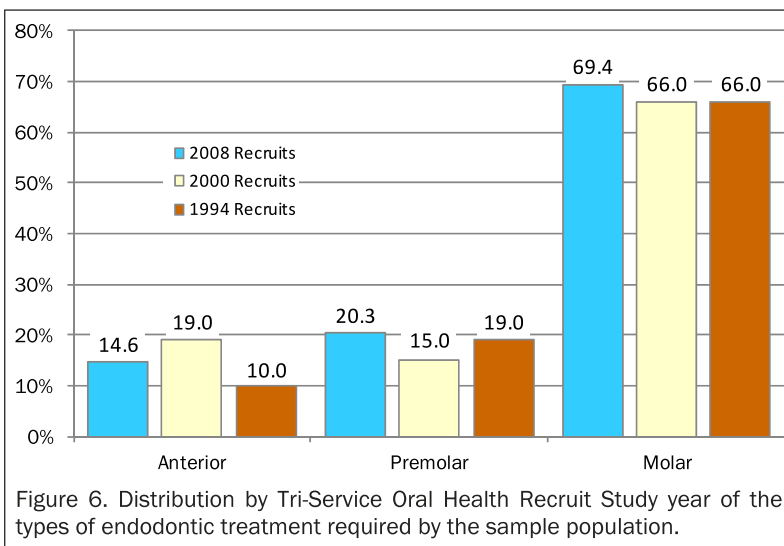
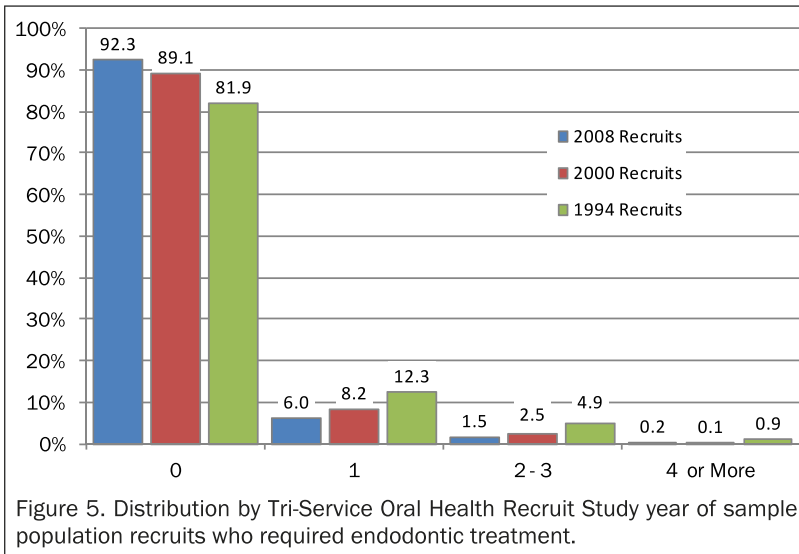


Figure 4. Distribution by component of 2008 recruit periodontal screening and recording score (based on patient's worst sextant PSR score).



## The 2008 Army Recruit Oral Health Survey Results



As shown in Figure 5, only 7.7% of 2008 recruits required endodontic treatment at the time of initial examination.

Among those Army recruits who required endodontic care, the mean number of teeth is one.

The distribution of the type of teeth that required endodontic care (Figure 6) shows that the majority are molars. The 2008 recruit components were not statistically different in distribution of endodontic treatment need.

### Other Clinical Findings

Overall, 3.4% of 2008 recruits exhibited a soft tissue lesion. The distribution of the types of lesions is very

similar with the most common being pericoronitis, orthodontic issues, and aphthous ulcers, 1.2%, 0.6%, and 0.5%, respectively. The prevalence of temporomandibular dysfunction was less than 0.2%. The mean number of dental sealants treatment planned was 0.4 per recruit and the mean number of teeth treatment planned for remineralization was 1.2 (Table 9).

Table 9. Remineralization and sealant requirements among 2008 recruits.

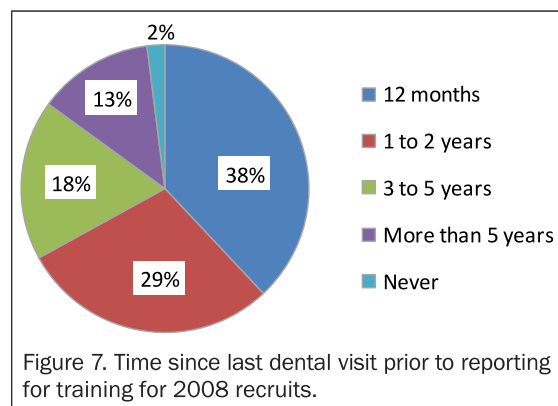
Sealants Required				Mean
None	1 - 2	3 - 4	5 +	
82%	11.9%	4.2%	1.8%	0.4
Remineralizations Required				Mean
70.3%	14.9%	4.9%	10%	

### Dental Care Prior to Entry

Dental utilization prior to entering military service was assessed for all recruits using a self-administered questionnaire.

The distribution of responses for 2008 recruits concerning the time since last dental visit prior to reporting for training is shown in Figure 7.

The percentage of 2008 recruits who had seen a dentist within the last 12 months prior to reporting for training was 38.3%, increasing to 66.9% within the last 24 months. There was no statistical difference among the 3 components for time since last visit.



Among those recruits who received dental care within the last 12 months, the percentage that had their teeth cleaned prior to reporting for training was 80.6%, 30.4% had operative care, and 17.2% had teeth removed.

The percentage of 2008 recruits who had some type of dental insurance was 44.3% (Figure 8).

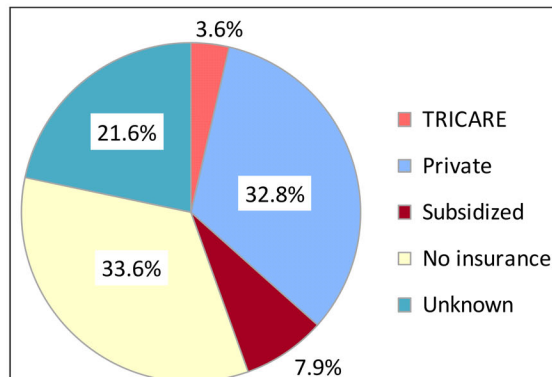


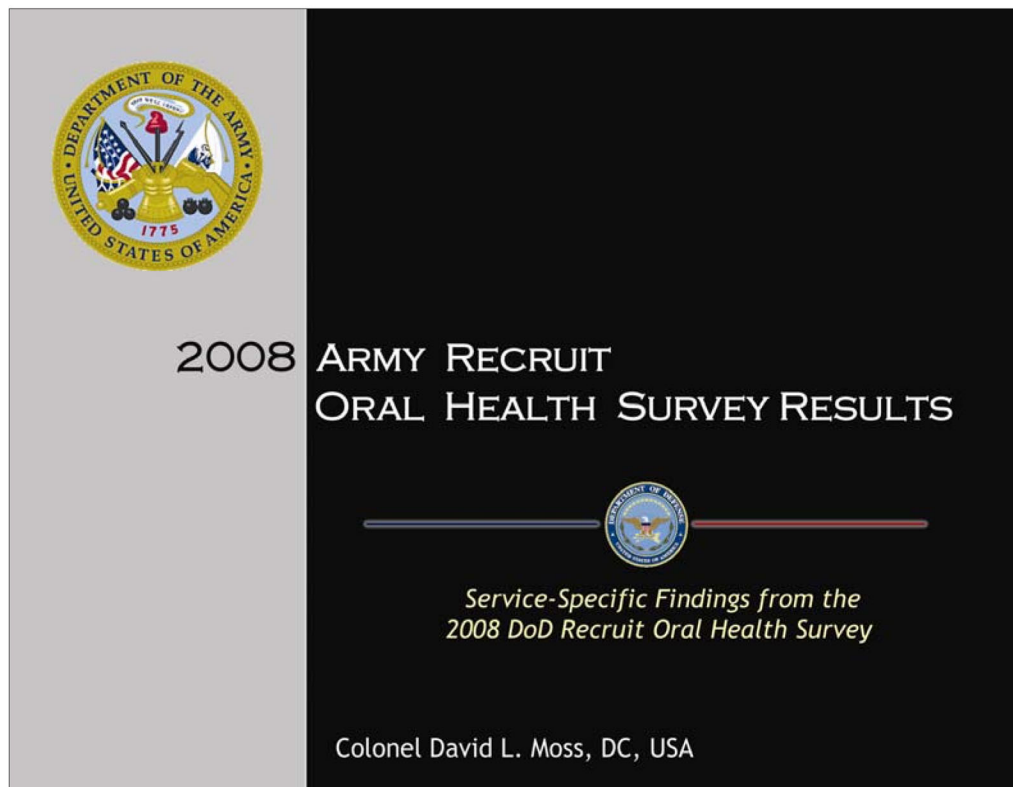
Figure 8. Distribution of dental insurance coverage among 2008 recruits.

## Perceived Need

Perceived need for dental care was also assessed for all recruits using the same self-administered questionnaire. The percentage of 2008 Army recruits who felt that they needed dental care was 60.5%. Among those that perceived a need for dental care, 27.1% responded that they needed dental care right away and 41.5% responded that they needed dental care within 6 months. The most common reason for recruits who felt they needed care, but had not received it, was the anticipated expense.

## AUTHOR

COL Moss is Director, Tri-Service Center for Oral Health Studies, Department of Preventive Medicine and Biometrics, and Assistant Professor of Preventive Medicine and Biometrics at the Uniformed Services University of the Health Sciences, Bethesda, Maryland.



# The US Army Dental and Trauma Research Detachment: Now Part of the Army Institute of Surgical Research

MAJ Davin E. Mellus, DC, USA  
Jacqueline Amaya

The US Army Dental and Trauma Research Detachment (DTRD) has relocated from the Naval Training Center, Great Lakes, Illinois, to Fort Sam Houston, Texas. This move, completed in August 2010, marks a new era in military dental research. Not only are the location and research buildings new, but the entire DTRD research program is new and redefined to reflect new opportunities to collaborate with scientists and clinicians collocated at the Department of Defense's largest medical research campus.

In accordance with 2005 Base Closure and Realignment Committee action, all combat casualty care military research units, less neuroprotection, are now collocated on the Battlefield Health and Trauma Research Institute (BHT) on the campus of Brooke Army Medical Center in San Antonio. The BHT includes the Army Institute of Surgical Research (ISR), the Naval Medical Research Unit, San Antonio, and the US Air Force Dental Evaluation and Consultation Service. The DTRD, once a detachment of Walter Reid Army Institute of Research, is now aligned under the ISR, the surgical research unit of Army Medical Research and Materiel Command (MRMC).

The DTRD, a detachment of Dental Corps officers assigned to MRMC, provides militarily-relevant research and solutions to diseases and injuries to the teeth and craniomaxillofacial region. It is comprised of approximately 40 personnel, including officers, enlisted specialists, and civilians. Professional specialties include oral and maxillofacial surgeons, periodontists, dental public health, comprehensive dentists, prosthodontists, microbiologists, physiologists, cell biologists, chemists, and microscopists. Assigned enlisted personnel reflect diverse military occupational skills, including dental, operating room, animal care, and laboratory technicians.

The collocation of combat casualty care research units at the Battlefield Health and Trauma Research Institute creates a robust environment for researchers and clinicians to collaborate, developing better ways to treat battle injuries and diseases of service members.

## MISSION AND VISION

In addition to a renewed research program, DTRD redefined its mission to provide militarily-relevant research and solutions for the prevention, treatment, and rehabilitation of craniofacial trauma and infectious dental diseases. DTRD's mission is the provision of world-class solutions in prevention, treatment, and rehabilitation of Warfighters with craniofacial trauma and infectious dental disease, and contributing expertise across the spectrum of combat casualty care. To meet those goals, DTRD research focuses on 3 areas: biofilm-induced dental disease (and wound impairment), craniomaxillofacial regenerative medicine, and mitigation of facial burns and scars.

DTRD's research mission receives strong support and collaboration from the ISR Extremity/Regenerative Medicine and Burn researchers, as well as newly collocated combat casualty care research units of the Navy and Air Force. To forge strong research relationships, DTRD's Research Steering Committee includes DTRD leadership, members of the ISR's extremity research team, and members of both Navy and Air Force dental research teams. Leaders from academia and the biomedical research industry also hold positions on the committee.

The BHT consists of 2 state-of-the-science research buildings, including a newly completed 150,000 sq ft building. DTRD, along with the dental research elements of the Navy and Air Force, occupies the first floor of this new building, designated BHT-2. The BHT also houses a 50,000 sq ft vivarium allowing scientists to perform critical experiments in order to translate research into improvements in combat casualty care.

## BIOFILM RESEARCH

No scientific advancements in work by DTRD at the Great Lakes location were lost in the transition to San Antonio. For example, following relocation, the research in the treatment and prevention of biofilm dental disease,



a disease which accounts for 20% of sick call cases in the combat zone, achieved approval by MPMC's Decision Gate Board to receive \$3.8 million for the manufacture of antiplaque chewing gum, a drug delivery device, in preparation for Food and Drug Administration clinical trials.

## BONE REGENERATION

According to the Joint Theater Trauma Registry (JTTR) data, 26% of battle injuries are to the maxillofacial region, which often includes jaw fractures.<sup>1</sup> Resultant bone and dentoalveolar defects common after severe and comminuted fractures are difficult to reconstruct without lengthy, invasive multi-staged procedures involving bone graft harvests. Before dental implants can return the jaws to full function, reconstruction must precisely position the implant supporting bone to the opposing dental arch, a requirement seldom achieved without surgical revisions. Aggravating reconstruction of major defects is a frequent complication and wound healing problems are accepted as unavoidable consequences of jaw reconstruction using conventional techniques and biomaterials. The DTRD, in collaboration with ISR's extremity research group, directly addresses the shortfalls of conventional techniques and biomaterials in reconstructing bone defects.

Using a novel flowable biomaterial, DTRD now performs research on critical size defects in animals to tune the biomaterial's characteristics for optimal bone regeneration. The flowable nature of the biomaterial promises to allow the surgeon to reconstruct bone defects through minimally invasive surgical procedures, manipulating the biomaterial as it sets into the proper shape and orientation to the opposing dental arch. Continued success of this bone regeneration research elevates the standard of care in jaw reconstruction by achieving better clinical results through fewer and less invasive surgeries.

## FACIAL BURNS AND SCARS

Another major thrust of DTRD research is to mitigate the consequences of severe facial burns and scars. According to JTTR data, facial burns occur in 77% of all burned service members who are evacuated from the combat theater.<sup>2</sup> Severe facial burns and scars often lead to contractures and hypertrophic scars which are especially problematic to the eyelids, nostrils, and mouth. The effect to the injured service member is lifelong microstomia, lip incompetence, ectropion, and facial disfigurement, conditions all important to the dental profession.

Improvement over conventional care of facial burns and scars includes strategies to modulate inflammation and comprehensively reconstruct the wound through advanced regenerative medicine and tissue engineering technologies. To deploy these technologies, DTRD is collaborating with bioengineers at University of Texas, Arlington, to develop an in situ bioreactor in the form of a custom, multifunctional polymer-based mask. The basic concept of this "biomask" is to optimize the burn wound bed, modulate excessive inflammation, and tissue-engineer all layers of the skin sequentially under a protective mask that enhances tissue engraftment. Development will take many years, but, if successful, the biomask will represent a paradigm shift in facial burn management.

Over the short time since DTRD arrived in San Antonio, the collocation of combat casualty care research has already proved to be a successful strategy. Located on the campus of a major medical center, DTRD's research and development of devices, therapeutic agents, and techniques to treat and rehabilitate craniomaxillofacial trauma and prevent infectious dental disease has been given a new focus. DTRD's new home fosters continuous, direct, and personal contacts with BHT researchers, enriching the process of exchanging ideas and technologies. The net result is acceleration of new biomedical technologies to return the Wounded Warrior to full function and a normal life.

---

## REFERENCES

1. Lew TA, Walker JA, Wenke JC, Blackburne LH, Hale RG. Characterization of craniomaxillofacial battle injuries sustained by United States service members in the current conflicts of Iraq and Afghanistan. *J Oral Maxillofac Surg*. 2010;68(1):3-7.
2. Kauvar DS, Wolf SE, Wade CE, Cancio LC, Renz EM, Holcomb JB. Burns sustained in combat explosions in Operations Iraqi and Enduring Freedom. *Burns*. 2006;32(7):853-857.

---

## AUTHORS

MAJ Mellus is Chief, Oral and Maxillofacial Surgery, Cranio-Maxillo-Facial Surgery Section, US Army Dental and Trauma Research Detachment, US Army Institute of Surgical Research, Fort Sam Houston, Texas.

Ms Amaya is the Administrative Officer, US Army Dental and Trauma Research Detachment, US Army Institute of Surgical Research, Fort Sam Houston, Texas.

# Clinical and Electrodiagnostic Abnormalities of the Median Nerve in Army Dental Assistants Before and After Training as Preventive Dental Specialists

David G. Greathouse, PhD, PT      1LT Bryan B. Pickens, SP, USA  
1LT Tiffany M. Root, SP, USA      Thomas G. Sutlive, PhD, PT  
CPT Carla R. Carrillo, SP, USA      LTC Scott W. Shaffer, SP, USA  
1LT Chelsea L. Jordan, SP, USA      COL Josef H. Moore, SP, USA

## ABSTRACT

**Purpose:** Dentists and dental hygienists have been reported as having a high prevalence of upper-extremity musculoskeletal disorders, including carpal tunnel syndrome. Unfortunately, previous research has not involved the impact of preventive dental specialist training on dental assistants. Therefore, the purpose of this study was to determine the presence of median and ulnar neuropathies in US Army dental assistants before and after training as preventive dental specialists.

**Methods:** Thirty-five US Army dental assistants (24 female, 11 male; age range 18-41 years) volunteered for the study. Twenty-eight preventive dental specialist students completed both the pretraining and posttraining data collections. Subjects were evaluated during the first and last weeks of their 12-week course. Subjects completed a history form, were interviewed, and underwent a physical examination. Nerve conduction status of the median and ulnar nerves of both upper extremities were obtained by performing motor, sensory, comparison (unilateral median to ulnar distal motor and sensory latencies), and F-wave nerve conduction studies (NCS). Descriptive statistics for subject demographics and pre to post physical examination and nerve conduction variables were calculated. Chi square ( $\chi^2$ ) analysis was also conducted to determine if a significant shift in the prevalence of neuropathies occurred following dental training.

**Results:** With the exception of comparison studies, pre-NCS and post-NCS electrophysiological variables were normal. Specifically, 9 subjects (26%) involving 14 hands (20%) were found to have meaningful ( $>1.0$  millisecond) delayed median to ulnar distal motor latency comparisons in the pretraining assessment. Additionally, there was no statistically significant shift in the prevalence of electrodiagnostic abnormalities of the median nerve following the 12-week training program ( $\chi^2=0.280$ ,  $P=.60$ ).

**Conclusion:** The prevalence of clinical and electrodiagnostic abnormalities of the median nerve in this sample of US Army dental assistants closely mirrors the prevalence reported for other dental professionals. This study also demonstrates that, for this sample, the 12-week training program did not appear to affect the electrophysiologic status of the median or ulnar nerves.

---

## INTRODUCTION

Median mononeuropathy at or distal to the wrist or carpal tunnel syndrome is one of a number of muscle-, tendon-, and nerve-related disorders that affect people performing intensive work with their hands. During the past 20 years there has been a tremendous increase in the reported cases of CTS,<sup>1-3</sup> resulting in an increased focus on occupational surveillance and screening.<sup>2</sup> Dental hygienists reportedly have a high prevalence of upper-extremity musculoskeletal disorders, including CTS.<sup>4-13</sup>

## OVERVIEW

Dental personnel, including dentists, dental hygienists, and dental assistants, have been reported as having a high prevalence of upper-extremity musculoskeletal disorders, including carpal tunnel syndrome (CTS). A research study was developed and implemented to determine the presence of median and ulnar neuropathies in a population of experienced dental assistants as they trained to become preventive dental specialists. Subjects completed a history form, were interviewed, underwent a physical examination, and

had nerve conduction studies performed on both upper extremities during the pretraining and posttraining data collection sessions. The pretraining data collected on experienced dental assistants has been presented<sup>14</sup> and served as a baseline measure in this study to determine the effects of preventive dental specialist's training. Although the prevalence of clinical and electrodiagnostic abnormalities of the median nerve in this sample closely mirrors the prevalence reported for other dental professionals, the 12-week training program did not appear to further impact the electrophysiologic status of the median or ulnar nerves. Further long-term prospective research involving the impact of dental practice and techniques for reducing upper extremity injuries in dental professionals appears to be warranted.

## REVIEW OF THE LITERATURE

Lalumandier and McPhee<sup>11</sup> surveyed US Army dental personnel and stated that 75% of dental hygienists reported having hand problems, and 56% exhibited probable or classic symptoms of CTS. In a study determining the presence of hand problems in Army dental personnel, 45% of the dental personnel surveyed indicated hand problems, and 25% were determined to indicate a high probability of CTS.<sup>12</sup> The authors concluded that Army dental personnel are at greater risk of developing CTS than the general public.<sup>12</sup> In a separate investigation, Rice et al<sup>13</sup> reported symptoms associated with CTS were noted by 75.6% of the dental workers, 11% reported diagnosed CTS, and 53% reported back and shoulder pain. Individuals in the dental hygienists and dental assistant-expanded function group were found to be at the greatest risk for developing upper extremity symptoms, CTS, and back pain. Other investigators have reported the prevalence of CTS among dental hygienists was 3%,<sup>9</sup> 6%,<sup>15</sup> 7%,<sup>8</sup> and 8%.<sup>4</sup>

Several ergonomic risk factors associated with CTS include repetitiveness of work, forceful exertions, mechanical stress, posture, temperature, and vibration.<sup>16</sup> These risk factors may be present for dentists and dental hygienists as dental instruments may cause contact stress over the carpal tunnel, and wrists may be held in awkward positions for prolonged periods.<sup>17</sup> In a study of dental hygienists, Bramson et al<sup>17</sup> evaluated several risk factors using hand-surface goniometry and electromyography, and concluded that dental hygienists' exposure to high-risk postures was

minimal, and that the force they exerted during work was of medium risk.

Median mononeuropathy at or distal to the wrist and other musculoskeletal dysfunction of the upper extremities is a well-documented problem among dentists and dental hygienists. Unfortunately, there is a lack of information in the literature to document the presence of CTS or upper extremity musculoskeletal dysfunction in Army dental assistants (MOS\* 68E) as they train to become Army preventive dental specialists (MOS 68E-X2). The job description for the preventive dental specialist is similar to that of a civilian dental hygienist, however, the training and educational requirements for the 2 positions are different. Therefore, the purpose of this study was to determine the presence of clinical and electrodiagnostic abnormalities of the median and ulnar nerves in both upper extremities in this sample of Army dental assistants during their training to become Army preventive dental specialists.

## METHODS AND MATERIALS

All dental assistants (n=47) participating in the September 2007 and January 2008 preventive dental specialist classes were approached to participate in this study. Three potential subjects declined to participate, 2 volunteered but were dropped from the course prior to data collection, and 7 volunteered but were not included in the study as they had no prior clinical experience as an Army dental assistant. The 7 dental assistants without dental assistance experience had proceeded directly from completion of the dental assistant course and matriculated into the preventive dental specialist course. All participated in the study during the first and last weeks of their 12-week Preventive Dental Specialist Course. A prerequisite for admission in the Army Preventive Dental Specialist Course is completion of the Army Dental Assistant Course.

Experimental procedures, risks, and subject rights were discussed with all subjects before participation in the study. All subjects signed an institutionally-approved, written consent form. Pregnant individuals were excluded. The study was approved by the Institutional Review Board of the Brooke Army Medical Center, Fort Sam Houston, Texas.

---

\*Military occupational specialty.



## Clinical and Electrodiagnostic Abnormalities of the Median Nerve in Army Dental Assistants Before and After Training as Preventive Dental Specialists

A history, physical examination, and upper quarter neuromusculoskeletal screen were performed to determine the status of the neural integrity of the median and ulnar nerves. These assessments were performed in both the pretraining and posttraining phases of the data collection.

### History

A history was taken from each patient in questionnaire format. The history included information pertaining to demographics, medical history, military background, dental assistant experience, hand dominance, and the amount of time using a computer.

### Physical Examination

A physical (screening) examination was part of the evaluation process of each subject. The physical examination included assessment of active range of motion, manual muscle tests, sensory evaluation, reflex testing, and select special tests.<sup>18,19</sup> Specifically, active range of motion was assessed for the cervical spine, shoulders, elbows, and wrists and hands. Manual muscle testing was performed for all major muscle groups in both upper extremities. Sensory assessment was determined with both light touch and pain/pin prick assessment of both peripheral nerves and dermatomes in both upper extremities. Muscle stretch reflexes (also known as deep tendon reflexes) were obtained from the biceps brachii, brachioradialis, and triceps in the upper extremities, and the quadriceps (patellar tendon), and triceps surae (Achilles tendon), in the lower extremities. Both upper and lower extremity pathological reflexes were assessed with the Hoffman sign (upper extremity) and Babinski sign (lower extremity). Last, the special tests of Tinel's sign of median and ulnar nerves at the wrist, Tinel's sign of the ulnar nerve at the elbow, Phalen's test, and the assessment of the radial pulses during positional changes of the upper extremities and neck (Adson's maneuver) were examined.<sup>18,19</sup>

### Nerve Conduction Studies

At the time of volunteer solicitation, potential subjects were instructed to abstain from exercising for one hour prior to testing. Skin temperature at the wrist was measured using a digital thermometer model TM99A (Cooper Instrument Corporation, Middlefield, CT), and was maintained at or above 32°C. If skin temperature fell below this value, the wrist, hand, and forearm were rewarmed with warm towels.

The Cadwell Sierra LT electromyograph and stimulator (Cadwell Laboratories, Inc, Kennewick, WA) were used to measure the compound motor action potential (CMAP) and sensory nerve action potential (SNAP) latencies and amplitudes. The stimulating current was a monophasic pulse 0.1 millisecond long. The oscilloscope was set to a sweep duration of 2.0 milliseconds per division and a gain of 20  $\mu$ V per division for the SNAPS. For the CMAPs, the oscilloscope was set to a sweep duration of 2.0 milliseconds per division and a gain of 5 mV per division. The filter settings were 10 Hz to 10 kHz for the motor potentials and 10 Hz to 2 kHz for the sensory potentials. The sensory latency was measured at the negative peak of the SNAP, and the amplitude was measured from negative peak to positive peak. The motor latency was measured from the negative takeoff of the evoked CMAP, while the amplitude was measured from the baseline to the negative peak of the evoked response. The obtained results were recorded manually and on computer printout.

Specific details for performing the median and ulnar nerve conduction studies (NCS) were presented in a study by Harkins et al<sup>20</sup> and follow procedures previously described.<sup>14,21-24</sup> The median and ulnar nerve palmar and digital distal sensory latencies (DSLs), distal motor latencies (DMLs), F-wave latencies, and conduction velocities were obtained from both upper extremities. All NCS procedures included measurement of the anatomic course of the nerve: median and ulnar palmar DSLs (8 cm), median and ulnar digital DSLs (14 cm), and median and ulnar DMLs (8 cm). In addition to comparing median nerve palmar and digital DSLs, DMLs, F-wave latencies, and conduction velocities with a chart of normal values, comparison studies between median and ulnar palmar DSLs, digit DSLs (digit 2 and digit 5, digit 4 median/ulnar), and DMLs in the same and opposite extremities were obtained. Examination of median and ulnar latencies in the same extremity and median and ulnar latencies in opposite extremities has been shown to assist in early electrodiagnosis of CTS.<sup>14,21-24</sup>

### Data Management and Analysis

Descriptive statistics for subject demographics and nerve conduction study variables and chi square ( $\chi^2$ ) analysis for NCS comparison studies were calculated using Statistical Package for Social Sciences software, version 12.0 (SPSS Inc, Chicago, IL).

## RESULTS

### Pretraining Assessment

#### History

Thirty-five subjects participated in this study (24 female, 11 male). The age of the subjects ranged from 18 to 41 years, and the mean  $\pm$ SD was  $23.3 \pm 5.6$  years.<sup>14</sup> Thirty of the subjects were right-handed. The mean number of months the dental assistants had been working in a dental clinic prior to preventive dental specialist training was 13.9 months, with a range of 2 to 84 months. All subjects had been in the military for at least 4 months, had completed basic combat training, and had completed dental assistant training. When asked about warm-up exercises prior to practicing as a dental assistant, 33 subjects responded to performing no warm-up exercises, and 2 subjects responded affirmatively. Thirteen of the subjects reported that they did not take breaks when working as a dental assistant, and 22 subjects did report taking breaks from work at 30 minutes (6 subjects), 45 minutes (2 subjects), 60 minutes (5 subjects), and less frequently than every hour (9 subjects).<sup>14</sup>

In assessing the time the subjects spent working on a computer, the mean time was 5.9 hours per week with a range of one to 25 hours per week. Six of the subjects played video games with a mean of 1.8 hours per week. Only five of the subjects reported playing musical instruments with a mean of 0.4 hours per week (range 1-5 hours/week).

When asked to describe their general health, thirty of the subjects reported being in excellent/good health and five of the subjects failed to respond to this question. None of the subjects reported having a history of neuropathic disease, renal disease, peripheral vascular disease, thyroid disease, diabetes, or arthritis.<sup>14</sup> When asked if they had experienced an injury, sixteen of the subjects responded affirmatively. Twelve of the subjects responded positively to having a problem with their head, neck, or upper extremities during the previous 6 months prior to data collection. All other subjects denied having any musculoskeletal problems in the past 6 months.

When asked specifically about current pain or symptoms in the neck or upper extremity, the following information was gathered: neck or scapular pain (n=8), left arm/forearm pain (subject 24), right

wrist/hand pain and/or numbness/tingling (N/T) (subjects 5, 8, 12, and 13), and left wrist/hand pain and/or N/T (subjects 12 and 14).<sup>14</sup>

In review of the subjects' history, the following subjects had subjective complaints suggestive of median or ulnar dysfunction: subject 5 had right wrist pain, subject 12 had N/T and pain in the right digit 3-4-5 and left digit 4, and subject 14 had N/T in the palm of the left hand.<sup>14</sup> Otherwise, from the information obtained in the history, there were no indicators suggesting median or ulnar nerve abnormalities in the upper extremities of these dental assistants.

#### Screening Examination

All subjects had normal active mobility of the cervical spine, shoulder, elbow, wrist and hand. Quadrant tests were determined to be normal without radicular symptoms in either upper extremity.

**Motor Strength**—Subject 19 had  $4/5$  strength right flexor pollicis longus and flexor digitorum profundus digit 2 (anterior interosseous nerve); subject 24 had  $4/5$  strength left elbow extensors, left wrist extensors, left wrist flexors, and left abductor pollicis brevis; subject 30 had  $4/5$  strength left/right shoulder abduction and  $4/5$  strength left abductor digiti minimi (ADM); and subject 39 had  $4/5$  strength left/right ADM.<sup>14</sup> Otherwise, all subjects were assessed to have normal ( $5/5$ ) muscle strength for the neck flexors, extensors, and rotators (C1-5); and both upper extremities to include the scapula elevators, depressors, protractors, and retractors (C1-5); shoulder flexors, abductors, and external/internal rotators (C5-6); elbow flexors and extensors (C5-8); wrist flexors and extensors (C6-8); finger flexors and extensors (C7-T1); and hand intrinsics (C8-T1). All upper extremity peripheral nerves (motor components) and myotomes (C4-T1) were assessed during motor testing.

**Sensation**—Subject 10 had decreased pinprick in the palmar surface of left digit 5.<sup>14</sup> Otherwise, all subjects had normal peripheral nerves (sensory components) and C4-T1 dermatome sensory testing results for light touch and pain/pin prick in both upper extremities.

**Muscle Stretch Reflexes and Pathological Signs**—All subjects displayed present and equal muscle stretch reflexes and pathological signs (Hoffman and

## Clinical and Electrodiagnostic Abnormalities of the Median Nerve in Army Dental Assistants Before and After Training as Preventive Dental Specialists

Babinski) were absent in all subjects in both the upper and lower extremities.

**Special Tests**—Ten subjects had positive findings for the special (provocative) tests (Tinel's or Phalen's) of the median or ulnar nerves (Table 1). All other subjects were noted to have negative findings with the performance of special tests.

**Thoracic Outlet Tests**—Subject 9 had decreased radial pulses bilaterally in the scalene, costoclavicular, and clavipectoral fascia/humeral positions. Otherwise, all subjects displayed normal radial pulses when the upper extremities were tested in the 3 thoracic outlet syndrome testing positions.<sup>14,18,19</sup>

Other than subjects 24, 30, and 39 (motor strength), subject 10 (sensory testing), and the 10 subjects that had positive findings on the special tests portion of the physical examination, there were no diagnostic indicators or evidence of median and ulnar nerve abnormalities in either upper extremity of the dental assistants tested during the physical examination portion of the assessment.<sup>14</sup>

### Nerve Conduction Studies

The results of the nerve conduction studies are presented in Table 2. The values for these electrophysiological variables for each subject were compared to a chart of normal values. This chart of normal values was developed in the Clinical Electrophysiological Laboratory, Texas Physical Therapy Specialists, and revalidated at the Electrophysiological Laboratory, US Army-Baylor University Doctoral Program in Physical Therapy. The chart of normal values depicted in Table 2 is similar to other charts of normal values.<sup>14,21-24</sup>

When comparing the results of the study with the chart of normal values, all subjects had normal NCS values including conduction latencies, amplitudes, and conduction velocities of the median and ulnar nerves in both upper extremities. Interestingly, when comparison studies between the median and ulnar palmar DSLs, digital DSLs, and DMLs in the same and opposite extremities, and the digit 4 median/ulnar comparison study in the same extremity were assessed, there were electrodiagnostic abnormalities of the median nerve at or distal to the wrist in 9 subjects (26%) involving 14 hands (20%) (Table 3).<sup>14</sup> In the present

Table 1. Subjects with positive findings on special tests of the upper extremities (pretraining).\*

Subject	Hand	Tinel's Sign at wrist (median)	Tinel's Sign at wrist (ulnar)	Tinel's Sign at elbow (ulnar)	Phalen's Test
7	Left	X			
7	Right	X†			
8	Left		X	X	
10	Right	X			
11	Right	X†			
14	Left			X	
29	Left	X			
32	Right		X	X	
32	Left			X	
35	Right	X	X	X	
35	Left	X	X	X	
38	Left	X			X
38	Right	X			X
41	Right	X			X

\*Data from Greathouse et al.<sup>14</sup> Reproduced with permission.

†Subjects with electrodiagnostic abnormalities of the median nerve or distal to the wrist.

study, the normal comparison values for palmar<sup>14,21-26</sup> and digital DSLs<sup>14,21-28</sup> were a difference of less than 0.5 millisecond, for DMLs<sup>14,21-26</sup> were a difference of less than 1.0 millisecond, and for digit 4 median/ulnar comparison a difference of less than 0.6 millisecond.<sup>14,21-24,29</sup> When using these comparison values, prolonged latency differences in the median-ulnar DMLs in the same extremity were observed in the right upper extremities in 4 subjects (4, 12, 32, and 38). When using these comparison values, prolonged latency differences in the median-ulnar DMLs in the same extremity were also observed in both upper extremities of 5 subjects (7, 9, 11, 25, and 39). In addition, subject 39 also had a prolonged difference of 0.7 millisecond between the digit 4 median and ulnar digital DSLs comparison study in the right hand (Table 3).<sup>30-32</sup>

### Posttraining Assessment

The preventive dental specialist course is a 12-week course that includes both didactic and clinical learning experiences. Twenty-eight of the subjects successfully completed the training to become preventive dental specialists and were tested during their last week of training (posttraining assessment). Seven of the subjects failed to complete the training due to academic or administrative problems and were not tested during the second phase (posttraining) of data collection.



Table 2. Mean, standard deviation, and range of values for neural conduction measurements (pretraining, n=35).\*

Right upper extremity				Left upper extremity			Normal Values
Median nerve	Mean	SD	Range	Mean	SD	Range	
Motor							
DML (ms)	3.5	0.4	2.8–4.2	3.4	0.4	2.7–4.1	<4.2
Amp CMAP (mV)	9.0	2.7	5.0–14	8.7	2.5	5.0–17	>5.0
MNCV BE - W (meters per second)	58.4	3.6	50–68	59.2	4.0	51–68	>50.0
Sensory							
Palmar DSL (ms)	1.8	0.2	1.6–2.2	1.8	0.1	1.6–2.1	<2.2
Palmar Amp SNAP (μV)	78.5	36.9	24–164	72.9	35.4	15–144	>15.0
2 Digit DSL (ms)	2.9	0.2	2.5–3.5	2.8	0.2	2.5–3.3	<3.5
2 Digit Amp SNAP (μV)	32.8	19.9	15–110	30.8	12.9	15–83	>15.0
F-Wave (ms)	26.2	2.1	21.6–30.3	25.8	2.1	21.5–29.6	<32.0
Ulnar nerve							
Motor							
DML (ms)	2.6	0.3	2.2–3.3	2.7	0.3	2.2–3.2	<3.6
Amp CMAP (mV)	8.5	2.3	5–14	8.0	1.9	5–12	>5.0
MNCV BE - W (meters per second)	60.9	5.9	50–73	60.5	4.1	54–72	>50.0
MNCV AE - BE (meters per second)	67.2	8.8	52–96	64.4	8.0	54–92	>50.0
Sensory							
Palmar DSL (ms)	1.7	0.1	1.4–2.0	1.7	0.1	1.5–2.1	<2.2
Palmar Amp SNAP (μV)	39.0	24.1	15–110	35.0	20.0	15–99	>15.0
5 Digit DSL (ms)	2.9	0.2	2.4–3.4	2.9	0.2	2.4–3.3	<3.5
5 Digit Amp SNAP (μV)	36.2	34.0	15–164	30.6	20.6	15–101	>15.0
F-Wave (ms)	26.2	2.4	20.7–31.2	26.2	2.1	22.5–31.3	<32.0
*Data from Greathouse et al. <sup>14</sup> Reproduced with permission. AE indicates above elbow; Amp, amplitude; BE, below elbow; CMAP, compound motor action potential; DML, distal motor latency; DSL, distal sensory latency; MNCV, motor nerve conduction velocity; SNAP, sensory nerve action potential; W, wrist.							

## History

In review of the subjects' posttraining history, the following subjects had subjective complaints suggestive of median or ulnar dysfunction: subject 5 had right wrist pain (median, pretraining complaint); subject 7 had N/T in the right palm (median, new); subject 8 had N/T left D5 (ulnar, new); subject 9 had N/T in the palm of both hands (median, new); subject 11 had right > left hand pain (median, new); subject 12 had N/T and pain in the right digit 3-4-5 and left digit 4 (ulnar, pretraining complaint); and subject 30 had N/T right digit 1 (median, new). Otherwise, from the information obtained in the history, there were no indicators suggesting median or ulnar abnormalities in the upper extremities of these subjects that had completed the preventive dental specialty course.

## Screening Examination

In the posttraining screening examination, the following subjects had findings on the physical examination

to suggest median or ulnar abnormalities: subject 7 had a positive Tinel's sign over the median nerve at the wrist in both hands (median, pretraining finding); subject 8 had a positive Tinel's sign over the left ulnar nerve at the elbow and wrist (ulnar, pretraining finding) and decreased sensation to light touch and pain in the palmar surface of left D5 (ulnar, new); subject 11 had a positive Tinel's sign over the right median nerve at the wrist (median, new); and subject 12 had decreased sensation to the palmar aspect of the left D5 (ulnar, new). Other than the subjects mentioned above, there were no diagnostic indicators or evidence of median and ulnar nerve abnormalities in either upper extremity of the subjects tested during the posttraining physical examination portion of the assessment.

## Nerve Conduction Studies

As in the pretraining nerve conduction evaluation, when comparing the results of the study with the chart of normal values, all subjects had normal NCS values

## Clinical and Electrodiagnostic Abnormalities of the Median Nerve in Army Dental Assistants Before and After Training as Preventive Dental Specialists

including conduction latencies, amplitudes, and conduction velocities of the median and ulnar nerves in both upper extremities. Similarly, when comparison studies between the median and ulnar palmar DSLs, digital DSLs, and DMLs in the same and opposite extremities, and the digit 4 median/ulnar comparison study in the same extremity were assessed, there were electrodiagnostic abnormalities of the median nerve at or distal to the wrist in 6 subjects (21%) involving 10 hands (18%) (Table 4). When using these comparison values, prolonged latency differences in the median-ulnar DMLs in the same extremity were observed in the right upper extremities in 2 subjects (12 and 32). When using these comparison values, prolonged latency differences in the median-ulnar DMLs in the same extremity were also observed in both upper extremities of 4 subjects (7, 9, 11, and 39). In addition, subject 12 also had a prolonged difference of 0.7 millisecond between the digit 4 median and ulnar digital DSLs comparison study in their right hand (Table 3).<sup>30-32</sup>

In comparing the pretraining and posttraining nerve conduction data, six of the subjects had electrodiagnostic evidence of median abnormalities at or distal to the wrist during both phases of testing. Two of the

subjects (4 and 25) with electrodiagnostic evidence of median abnormalities at or distal to the wrist in the pretraining phase of data collection failed to successfully complete the preventive dental specialist course and were not tested during the posttraining phase of data collection. One subject (38) had electrodiagnostic evidence of right median nerve abnormality during the pretraining data collection, but on posttraining assessment, results of the NCS comparison studies were normal. There was no new electrodiagnostic evidence of median nerve abnormalities during the posttraining phase of data collection in the other 22 subjects. There was no statistically significant shift of the nerve conduction values in the prevalence of median neuropathies following the 12-week training program ( $\chi^2=0.280$ ,  $P=.60$ ).

### COMMENT

To our knowledge, no studies have used histories, physical examinations, and NCS to assess the status of the median and ulnar nerves in dental assistants enrolled in a preventive dental specialist course. A thorough history and physical examination are considered essential screening tools for detecting signs

Table 3: Subjects with positive findings on neural conduction comparison studies (pretraining).\*

Subject	Hand	Palmar DSL (ms)			Digital DSL (ms)			DML (ms)			D4 DSL (ms)		
		Median	Ulnar	Difference	Median	Ulnar	Difference	Median	Ulnar	Difference	Median	Ulnar	Difference
004	R	1.7	1.8	0.1	2.7	2.8	0.1	3.9	2.6	1.3 <sup>†</sup>	2.8	2.8	0.0
	L	1.8	1.8	0.0	2.7	2.7	0.0	3.6	2.9	0.7	2.8	2.7	0.1
007	R	1.8	1.6	0.2	2.8	2.4	0.4	3.9	2.3	1.3 <sup>†</sup>	2.9	2.5	0.4
	L	2.0	1.5	0.5	2.6	2.4	0.2	3.4	2.3	1.1 <sup>†</sup>	3.1	2.6	0.5
009	R	1.8	1.5	0.3	2.8	2.6	0.2	3.4	2.3	1.1 <sup>†</sup>	2.8	2.5	0.3
	L	1.8	1.7	0.1	2.6	2.8	0.2	3.8	2.2	1.6 <sup>†</sup>	2.7	2.7	0.0
011	R	1.7	1.6	0.1	2.5	2.8	0.3	4.2	2.2	2.0 <sup>†</sup>	2.5	2.4	0.1
	L	1.7	1.7	0.0	2.5	2.7	0.2	3.8	2.3	1.5 <sup>†</sup>	2.6	2.5	0.1
012	R	2.0	1.6	0.4	3.1	2.8	0.3	3.7	2.4	1.3 <sup>†</sup>	3.2	2.8	0.4
	L	1.9	1.6	0.3	2.8	2.7	0.1	3.2	2.3	0.9	2.9	2.6	0.3
025	R	2.2	1.7	0.5	3.2	3.1	0.1	4.0	2.4	1.6 <sup>†</sup>	3.3	2.8	0.5
	L	1.9	1.6	0.3	3.0	2.9	0.1	3.7	2.6	1.1 <sup>†</sup>	3.2	3.0	0.2
032	R	2.1	1.8	0.3	3.1	3.2	0.1	4.1	3.0	1.1 <sup>†</sup>	3.4	3.0	0.4
	L	1.9	1.8	0.1	2.8	2.9	0.1	3.7	3.1	0.6	3.2	2.8	0.4
038	R	1.9	1.8	0.1	3.0	2.9	0.1	4.0	2.7	1.3 <sup>†</sup>	3.2	3.1	0.1
	L	2.0	1.8	0.2	3.3	3.3	0.0	3.6	3.1	0.5	3.6	3.4	0.2
039	R	2.0	1.6	0.4	3.0	2.7	0.3	3.8	2.4	1.4 <sup>†</sup>	3.1	2.4	0.7 <sup>†</sup>
	L	2.0	1.5	0.5	3.0	2.6	0.4	3.9	2.6	1.3	3.3	2.9	0.4

\*Data from Greathouse et al.<sup>14</sup> Reproduced with permission.

<sup>†</sup>Indicates electrodiagnostic abnormalities of the median nerve.

DSL indicates distal sensory latency; DML, distal motor latency.

NOTE: Prolonged DML difference > 1.0 millisecond (normal < 1.0 millisecond).

Prolonged D4 median/ulnar difference > 0.6 millisecond (normal < 0.6 millisecond).

and symptoms of peripheral neuropathy.<sup>14,21-24,33</sup> Nerve conduction measurement is often performed on the median and ulnar nerves to determine whether certain entrapment neuropathies are present.<sup>14,21-24,33-40</sup> Nerve conduction measurement is considered the gold standard when assessing the electrophysiologic status of the peripheral nerve.<sup>14,21-24,33-43</sup>

As a result of the 12-week course, 5 subjects had new complaints suggestive of median or ulnar nerve abnormalities: subject 7 (right median); subject 8 (left ulnar); subject 9 (bilateral median), subject 11 (left>right median), and subject 30 (right median). Two subjects had continuing subjective complaints of a right median nerve dysfunction (subject 5) and a left ulnar and median nerve function (subject 12).

Subject 7 had N/T in the palm of the right hand on the posttraining assessment but had a positive Tinel's sign over both median nerves at the wrist and electrodiagnostic findings of bilateral median abnormalities at or distal to the wrist in both the pretraining and posttraining assessment. Subject 8 had N/T in the left digit 5 on the posttraining physical examination as well as decreased sensation in the left digit 5. Subject 8 continued to have a positive Tinel's sign at the left ulnar nerve at the wrist and elbow suggestive of a left ulnar abnormality, however, nerve conduction testing of the left ulnar nerve was normal. Subject 9 had N/T in the palms of both hands (posttraining) suggestive of bilateral median nerve dysfunction; but there were no physical examination findings to suggest a bilateral

median nerve compromise. However, subject 9 had pretraining and posttraining electrodiagnostic evidence suggestive of a bilateral median nerve abnormality at or distal to the wrist.

Subject 11 had a new finding of bilateral (right>left) hand pain and a positive Tinel's sign over the right median nerve at the wrist (pretraining) but a normal physical assessment on the posttraining examination. Subject 11 also had electrodiagnostic evidence on both the pretraining and posttraining NCS testing suggestive of bilateral median nerve abnormality. Subject 30 had a new finding of N/T of the right digit (thumb) suggestive of a right median nerve abnormality but a normal physical examination and nerve conduction studies.

Two subjects had consistent complaints during both testing sessions. Subject 5 had right wrist pain but normal physical examination and nerve conduction studies on both pretraining and posttraining assessments. Subject 12 had complaints of bilateral median and ulnar nerve dysfunction on both exams and a new loss of sensation of the left digit 5. The nerve conduction studies for subject 12 were consistent for electrodiagnostic abnormalities of the right median nerve at or distal to the wrist but the bilateral ulnar nerve studies were normal.

Of the 35 dental assistants that participated in the pretraining assessment, 14 hands (20%) in 9 subjects (26%) had electrodiagnostic abnormalities of the

Table 4: Subjects with positive findings on neural conduction comparison studies (posttraining).

Subject	Hand	Palmar DSL (ms)			Digital DSL (ms)			DML (ms)			D4 DSL (ms)		
		Median	Ulnar	Difference	Median	Ulnar	Difference	Median	Ulnar	Difference	Median	Ulnar	Difference
007	R	1.8	1.5	0.3	2.8	2.6	0.2	3.7	2.5	1.2	2.9	2.6	0.3
	L	1.9	1.7	0.2	2.8	2.7	0.1	3.8	2.7	1.1	3.2	2.6	0.6
009	R	1.8	1.6	0.2	2.8	2.8	0.0	3.6	2.5	1.1	3.0	2.6	0.4
	L	1.7	1.7	0.0	2.6	2.8	0.2	3.6	2.1	1.5	2.8	2.7	0.1
011	R	1.7	1.7	0.0	2.7	3.0	0.3	4.2	2.9	1.3	3.0	2.9	0.1
	L	1.6	1.8	0.2	2.6	2.8	0.2	4.1	2.7	1.4	2.8	2.7	0.1
012	R	2.2	1.7	0.5	3.2	2.9	0.3	4.0	2.9	1.1	3.5	2.8	0.7
	L	2.1	1.8	0.3	3.1	3.1	0.0	3.6	3.1	0.5	3.3	3.0	0.3
032	R	2.0	1.8	0.2	2.8	2.8	0.0	3.7	2.6	1.4	2.9	2.8	0.1
	L	1.8	1.7	0.1	2.6	2.6	0.0	3.4	2.7	0.7	2.8	2.8	0.0
039	R	2.0	1.8	0.2	3.0	2.8	0.2	4.2	2.8	1.4	3.1	2.7	0.4
	L	2.0	1.7	0.3	3.0	2.7	0.3	3.9	2.5	1.4	3.2	2.6	0.6

DSL indicates distal sensory latency; DML, distal motor latency.

Prolonged DML difference > 1.0 millisecond (normal < 1.0 millisecond).

Prolonged D4 median/ulnar difference > 0.6 millisecond (normal < 0.6 millisecond).

Subjects 004 and 025 did not complete the preventive dental specialist training, and therefore did not participate in the posttraining assessment.



## Clinical and Electrodiagnostic Abnormalities of the Median Nerve in Army Dental Assistants Before and After Training as Preventive Dental Specialists

median nerve at or distal to the wrist.<sup>14</sup> Six of these 9 subjects continued with electrodiagnostic abnormalities of the median nerve at or distal to the wrist (6 subjects (21%), 10 hands (18%)). Two subjects (4 and 25) did not complete the course, and subject 38 improved his nerve conduction findings from the pretraining to posttraining assessments.

There was no statistically significant shift of the nerve conduction values in the prevalence of median neuropathies following the 12-week training program ( $\chi^2=0.280$ ,  $P=.60$ ). It appears that the 12-week training program did not affect the median and ulnar nerve function as assessed by physical examination and nerve conduction testing. There was no electrodiagnostic evidence on either the pretraining or posttraining nerve conduction studies to suggest ulnar nerve abnormalities at or distal to the wrist, in the forearm, or at the elbow (cubital tunnel).

Of the 35 dental assistants that participated in the pretraining assessment, 14 hands (20%) in 9 subjects (26%) had electrodiagnostic abnormalities of the median nerve at or distal to the wrist.<sup>14</sup> Review of the number of months the 9 dental assistants with pretraining electrodiagnostic abnormalities of the median nerve at or distal to the wrist had been practicing in the dental clinic indicated that 5 subjects had been practicing in a dental clinic greater than 12 months, and 4 subjects reported practicing less than 12 months. When considering warm-up exercises, breaks during clinical practice, and amount of time per week on the computer, playing video games, or playing a musical instrument, there were no consistent factors that separated the 9 dental assistants from the group studied. All of the 9 dental assistants that had electrodiagnostic abnormalities of the median nerve at or distal to the wrist described their general health to be good or excellent, and none of these subjects had a history of neuropathic disease, renal disease, peripheral vascular disease, thyroid disease, diabetes, or arthritis.

Dental hygienists reportedly have a high prevalence of upper-extremity musculoskeletal disorders, including CTS.<sup>4-13</sup> In their survey of Army dental personnel, Lalumandier and McPhee<sup>11,12</sup> stated that 75% of dental hygienists reported having hand problems, and 56% exhibited probable or classic symptoms of CTS. Rice et al<sup>13</sup> reported symptoms associated with CTS were

noted by 75.6% of the dental workers, 11% reported diagnosed CTS, and 53% reported back and shoulder pain. With the documented incidence of carpal tunnel syndrome in dentists and dental hygienists, there are no studies, to our knowledge, that have documented the incidence of carpal tunnel syndrome in dental assistants enrolled in a preventive dental specialist course. The present study demonstrated that electrodiagnostic abnormalities of the median nerve at or distal to the wrist or carpal tunnel syndrome is present in 9 Army subjects (26%) pretraining and 6 subjects (21%) posttraining. However, only 2 of the 9 subjects had objective findings on the clinical examination suggestive of median nerve dysfunction.

In a population such as the dental assistants studied here, it is reasonable to expect that subclinical upper extremity mononeuropathies secondary to repetitive overuse may be present. In the early stages of a mononeuropathy of this type, many individuals with a clinically detectable problem are not aware that their neural function has been impaired.<sup>44</sup> Atroshi et al<sup>44</sup> examined 125 asymptomatic controls with NCS of the median nerves and reported that 18% (n=23) had electrophysiological evidence of carpal tunnel syndrome.

Atroshi et al<sup>44</sup> have stated that the estimation of the prevalence of carpal tunnel syndrome in a general population may contribute to the early diagnosis and effective treatment of subjects and provide useful data for the interpretation of results that estimate the prevalence of carpal tunnel syndrome in specific occupational groups. Franzblau and Werner<sup>45-47</sup> further suggest that performing NCS of individuals without symptoms of carpal tunnel syndrome is important because it permits the assessment of the overall relationship between the electrophysiological properties of the nerve and other clinical features of carpal tunnel syndrome. Although no strong evidence exists regarding the prevention or progression of CTS, it makes sense, theoretically, to identify a problem early, where a minor intervention, such as a resting night splint or ergonomic changes in the work environment, might rectify the dysfunction.<sup>45-47</sup>

A valuable extension of this study would be evaluations of these preventive dental specialists as they progress through their dental health careers, and to reevaluate them in 5 to 10 years to determine whether the

individuals who presented with early electrodiagnostic abnormalities of median nerve at or distal to the wrist later develop symptomatic carpal tunnel syndrome.

## CONCLUSION

This study examined a sample of 35 Army dental assistants during their training to become preventive dental specialists for the presence of clinical and electrodiagnostic abnormalities of the median and ulnar nerves. All electrophysiological variables were normal for motor, sensory, and F-wave (central) values when compared to a chart of normal values in both the pretraining and posttraining assessments. Based on comparison studies of median and ulnar motor latencies in the same hand, 14 hands (20%) among 9 subjects (26%) were found to have electrodiagnostic abnormalities of the median nerve at or distal to the wrist at the pretraining assessment.<sup>14</sup> During post-training assessment, there were no new cases of electrodiagnostic median nerve abnormalities and no statistically significant shift of the nerve conduction values in the prevalence of median neuropathies following the 12-week training program. Ulnar nerve electrophysiological function was within normal limits for all subjects examined. Nerve conduction comparison studies may provide sensitive measures and early indicators for the detection of early median nerve compromise at or distal to the wrist. Additional long-term prospective studies examining the prevalence and prevention of upper extremity disorders, to include carpal tunnel, appear to warrant further investigation.

## ACKNOWLEDGEMENT

The authors thank COL Robert Lutka, SFC Charles A. Aponte, SFC Heide C. Mayberry, SFC Michael C. Mason, and SSG Gerald M. Bradford (AMEDD Center and School, Fort Sam Houston, Texas) for their support of this study and their assistance in recruiting the dental assistants who participated.

## REFERENCES

- Franklin GM, Haug J, Heyer N, Checkoway H, Peck N. Occupational carpal tunnel syndrome in Washington State, 1984-1988. *Am J Public Health.* 1991;81(6):741-746.
- Hanrahan LP, Higgins D, Anderson H, Haskins L, Tai S. Project SENSOR: Wisconsin surveillance of occupational carpal tunnel syndrome. *Wis Med J.* 1991;90(2):80-83.
- Stockstill JW, Harn SD, Strickland D, Hruska R. Prevalence of upper extremity neuropathy in a clinical dentist population. *J Am Dent Assoc.* 1993;124(8):67-72.
- Anton D, Rosecrance J, Melino L, Cook T. Prevalence of musculoskeletal symptoms and carpal tunnel syndrome among dental hygienists. *Am J Ind Med.* 2002;42(3):248-257.
- Conrad JC, Conrad KJ, Osborn JB. A short-term, three-year epidemiological study of median nerve sensitivity in practicing dental hygienists. *J Dent Hyg.* 1993;67(5):268-272.
- Corks I. Occupational health hazards in dentistry: musculoskeletal disorders. *Ont Dent.* 1997;74(6):27-30.
- Guay AH. Commentary: ergonomically related disorders in dental practice. *J Am Dent Assoc.* 1998;129(2):184-186.
- Osborn JB, Newell KJ, Rudney JD, Stoltenberg JL. Carpal tunnel syndrome among Minnesota dental hygienists. *J Dent Hyg.* 1990;64(2):79-85.
- Werner RA, Hamann C, Franzblau A, Rodgers PA. Prevalence of carpal tunnel syndrome and upper extremity tendinitis among dental hygienists. *J Dent Hyg.* 2002;76(2):126-132.
- Cherniack M, Brammar AJ, Nilsson T, et al. Nerve conduction and sensorineural function in dental hygienists using high frequency ultrasound handpieces. *Am J Ind Med.* 2006;49(5):313-326.
- Lalumandier JA, McPhee SD. Prevalence and risk factors of hand problems and carpal tunnel syndrome among dental hygienists. *J Dent Hyg.* 2001;75(2):130-134.
- Lalumandier JA, McPhee SD, Riddle S, Shulman JD, Daigle WW. Carpal tunnel syndrome: effect on Army dental personnel. *Mil Med.* 2000;165(5):372-378.
- Rice VJ, Nindl B, Tentikis JS. Dental workers, musculoskeletal cumulative trauma, and carpal tunnel syndrome. Who is at risk? A pilot study. *Int J Occup Saf Ergon.* 1996;2(3):218-233.
- Greathouse DG, Root RM, Carrillo CR, Jordan CL, Pickens BB, Sutlive TG, Shaffer SW, Moore JS. Clinical and electrodiagnostic abnormalities of the median nerve in dental assistants. *J Orthop Sports Phys Ther.* 2009;39(9):693-701.
- Macdonald G, Robertson MM, Erickson JA. Carpal tunnel syndrome among California dental hygienists. *Dent Hyg.* 1988;62:322-327.

# **Clinical and Electrodiagnostic Abnormalities of the Median Nerve in Army Dental Assistants Before and After Training as Preventive Dental Specialists**

16. Werner RA, Armstrong TJ. Carpal tunnel syndrome: ergonomic risk factors and intracarpal canal pressure. *Phys Med Rehabil Clin N Am.* 1997;8(3):555-569.
17. Bramson JB, Smith S, Romagnoli G. Evaluating dental office ergonomics: risk factors and hazards. *J Am Dent Assoc.* 1998;129(2):174-183.
18. Dutton M. *Orthopaedic Examination, Evaluation, & Intervention.* New York, NY: McGraw-Hill Medical Publishing Division; 2005.
19. Magee DJ. *Orthopaedic Physical Assessment.* Philadelphia: W.B. Saunders; 1992.
20. Harkins G, Jayne D, Masullo L, et al. Effects of gender and handedness on neural conduction in humans. *J Clin Electrophysiol.* 1989;1:10-13.
21. Jablecki CK. Practice parameter for electrodiagnostic studies in carpal tunnel syndrome: summary statement: American Association of Electrodiagnostic Medicine, American Academy of Neurology, American Academy of Physical Medicine and Rehabilitation. *Muscle Nerve.* 1993;16(12):1390-1391.
22. Dumitru D, Amato A, Zwarts M. *Electrodiagnostic Medicine.* 2nd ed. St. Louis, MO: Hanley & Belfus; 2002.
23. Kimura J. *Electrodiagnosis in Diseases of Nerve and Muscle: Principles and Practice.* 3rd ed. New York: Oxford University Press; 2001.
24. Oh SJ. *Clinical Electromyography in Nerve Conduction Studies.* Baltimore, MD: Williams & Wilkins; 1993.
25. Daube JR. Percutaneous palmar median nerve stimulation for carpal tunnel syndrome. *Electroencephalogr Clin Neurophysiol.* 1977;43:139-140.
26. Felsenthal G. Carpal tunnel syndrome diagnosis. *Arch Phys Med Rehabil.* 1979;60-90.
27. Felsenthal G. Median and ulnar distal motor latencies in the same normal subject. *Arch Phys Med Rehabil.* 1977;58:297-302.
28. Felsenthal G, Spindler H. Palmar conduction time of median and ulnar nerves of normal subjects and patients with carpal tunnel syndrome. *Am J Phys Med Rehabil.* 1979;58:131-138.
29. Johnson EW, Kukla RD, Wongsam PE, et al. Sensory latencies to the ring finger. Normal values and relation to carpal tunnel syndrome. *Arch Phys Med Rehabil.* 1981;62:206-208.
30. Uncini A, Lange DJ, Solomon M, et al. Ring finger testing in carpal tunnel syndrome: a comparative study of diagnostic utility. *Muscle Nerve.* 1989;12:735-741.
31. Uncini A, DiMuzio A, Cutarella R, et al. Orthodromic median and ulnar fourth digit sensory conduction in mild carpal tunnel syndrome. *Neurophysiol Clin.* 1990;20:53-61.
32. van Dijk JG. Multiple tests and diagnostic validity. *Muscle Nerve.* 1995;18:353-355.
33. MacDermid JC, Doherty T. Clinical and electrodiagnostic testing of carpal tunnel syndrome: a narrative review. *J Orthop Sports Phys Ther.* 2004;34:565-588.
34. Jablecki CK, Andary MT, So YT, et al. Literature review of the usefulness of nerve conduction studies and electromyography for the evaluation of patients with carpal tunnel syndrome. *Muscle Nerve.* 1993;16:1392-1414.
35. Jablecki CK, Andary MT, Floeter MK, et al. Practice parameter: electrodiagnostic studies in carpal tunnel syndrome. Report of the American Association of Electrodiagnostic Medicine, American Academy of Neurology, and the American Academy of Physical Medicine and Rehabilitation. *Neurology.* 2002;58:1589-1592.
36. Jackson DA, Clifford JC. Electrodiagnosis of mild carpal tunnel syndrome. *Arch Phys Med Rehabil.* 1989;70(3):199-204.
37. MacDermid JC, Wessel J. Clinical diagnosis of carpal tunnel syndrome. A systematic review. *J Hand Ther.* 2004;17:309-319.
38. Melvin JL, Schuchmann JA, Lanese RR. Diagnostic specificity of motor and sensory nerve conduction variables in the carpal tunnel syndrome. *Arch Phys Med Rehabil.* 1973;54:69-74.
39. Moore J. Carpal tunnel syndrome. *Occup Med.* 1992;7(4):741-763.
40. National Institute of Occupational Safety and Health. Carpal tunnel syndrome. In: Bernard BP, ed. *Musculoskeletal Disorders and Workplace Factors.* Washington, DC: US Department of Health and Human Services; 1997:1-29. DHHS publication 97-144.
41. Redmond MD, Rivner MH. False positive electrodiagnostic tests in carpal tunnel syndrome. *Muscle Nerve.* 1988;11(5):511-518.
42. Salerno DF, Franzblau A, Werner RA, Bromberg MB, Armstrong TJ, Albers JW. Median and ulnar nerve conduction studies among workers: normative values. *Muscle Nerve.* 1998;21:999-1005.
43. Scelsa SN, Herskovitz S, Bieri P, Berger AR. Median mixed and sensory nerve conduction studies in carpal tunnel syndrome. *Electroenceph Clin Neurophysiol.* 1998;109:268-273.



44. Atroshi I, Gummesson C, Johnsson R, Ornstein E, Ranstam J, Rosen I. Prevalence of carpal tunnel syndrome in a general population. *JAMA*. 1999;292(2):153-158.
45. Franzblau A, Werner RA, Valle J, Johnston E. Workplace surveillance for carpal tunnel syndrome. *J Occup Rehabil*. 1993;3(1):1-14.
46. Franzblau A, Werner RA, Albers JW, Olinski D, Johnston E. Workplace surveillance for carpal tunnel syndrome using hand diagrams. *J Occup Rehabil*. 1994;4(4):185-198.
47. Franzblau A, Werner R. What is carpal tunnel syndrome?. *JAMA*. 1999;282:186-187.

---

## AUTHORS

Dr Greathouse is Director, Clinical Electrophysiology Services, Texas Physical Therapy Specialists, New Braunfels, Texas, and Adjunct Professor, US Army-Baylor University Doctoral Program in Physical Therapy, Fort Sam Houston, Texas.

1LT Root is a staff physical therapist at Ireland Army Community Hospital, Fort Knox, Kentucky. At the time of this study, she was a student in the US Army-Baylor University Doctoral Program in Physical Therapy, Fort Sam Houston, Texas.

CPT Carrillo is a staff physical therapist at Evans Army Community Hospital, Fort Carson, Colorado. At the time of this study, she was a student in the US Army-Baylor University Doctoral Program in Physical Therapy, Fort Sam Houston, Texas.


1LT Jordan is a staff physical therapist at Madigan Army Medical Center, Fort Lewis, Washington. At the time of this study, she was a student in the US Army-Baylor University Doctoral Program in Physical Therapy, Fort Sam Houston, Texas.

1LT Pickens is a staff physical therapist at Reynolds Army Community Hospital, Fort Sill, Oklahoma. At the time of this study, he was a student in the US Army-Baylor University Doctoral Program in Physical Therapy, Fort Sam Houston, Texas.

Dr Sutlive is an Associate Professor, US Army-Baylor University Doctoral Program in Physical Therapy, Fort Sam Houston, Texas.

LTC Shaffer is an Associate Professor, US Army-Baylor University Doctoral Program in Physical Therapy, Fort Sam Houston, Texas.

COL Moore is Professor and Program Director, US Army-Baylor University Doctoral Program in Physical Therapy, Fort Sam Houston, Texas.



# Palatal Fracture in a Child

COL Karen M. Keith, DC, USA  
CPT Tyler L. Clark, DC, USA

Oral and maxillofacial surgeons are often consulted to evaluate intraoral trauma in children. The pediatric population is exceptionally susceptible to penetrating trauma of the palate due to developing coordination issues and the tendency to put objects into mouths.<sup>1</sup> While the vast majority of such cases are easily managed on an outpatient basis, clinicians should have a high index of suspicion for the potential devastating effects of these types of injuries. They can appear rather innocuous at initial presentation, but can actually lead to potentially fatal or highly morbid complications. We present a case of penetrating palatal trauma with a unique etiology and approach to treatment, and discuss some of the consequences that have been presented in the literature, with a treatment protocol to remind providers of the need for vigilance in this trauma scenario.

## CASE REPORT

A 6-year-old female reported to the Emergency Department at Madigan Army Medical Center with a complaint of pain and bleeding from the roof of her mouth. She had been running on the playground at school. She tripped and fell toward a friend, who was holding a tree branch. One of the smaller branches penetrated her palatal mucosa and bone. Upon examination in the Emergency Department, her vitals were noted to be within normal limits for her age. Her medical history was significant only for a history of jaundice as an infant and an allergy to penicillin. Immunizations were up-to-date. The patient was hemodynamically and neurologically intact. Examination of the oral cavity revealed a hemostatic, stellate puncture wound just to the left of the patient's midline at the junction of the hard and soft palate (Figure 1). Closer intraoral examination of the wound revealed a palatal fracture just lateral to the midline suture, with the fractured bone vertically displaced into the nasal vestibule toward the caudal septal cartilage. The computed tomography scan image (Figure 2) demonstrates the degree of displacement of the fractured piece. Due to concern for scarring and future septal deviation as well as potential infection, the patient was taken to the operating room for general

anesthesia to manually reduce the fractured bone and to better explore the wound. Intraoperatively, a combination of digital manipulation intraorally and the use of a #15 scaler intranasally successfully repositioned the maxillary bone (Figure 3). Inspection of the septum revealed no deviation, laceration, or hematoma. Fast absorbing gut suture was used to close the palatal mucosa and the patient was placed on postoperative antibiotics for 5 days (Figure 4). A palatal stent was fabricated from a preoperative model and secured to the dentition with suture for 5 days. Instructions were provided to the patient and parents. The patient had an uneventful postoperative course and healed without incident or sequela (Figure 5).

## DISCUSSION

Penetrating injury to the palate can range from relatively innocuous to rather significant and dangerous, depending on the location of the entry wound intraorally. Most bleeding is self-limited unless the palatine artery is injured. Management of most such injuries can be on an outpatient basis, but clinicians must remain vigilant should the patient's status deteriorate. Potentially devastating effects of penetrating palatal trauma include overt carotid vessel disruption with significant hemorrhage and intimal tearing with thrombus formation and propagation that can result in ischemic infarcts. Oral bacterial contamination can cause severe infections into major fascial planes or the mediastinum.<sup>2</sup> If the injury is located off the palatal midline, the proximity of the carotid vasculature cannot be discounted. Occlusion of the middle cerebral artery and ischemic infarctions have been reported.<sup>3,4</sup> The subsequent neurologic deficits can manifest as partial or complete hemiparesis, homonymous hemianopsia, Horner's syndrome, facial nerve paralysis, gait issues, or death.<sup>5,6</sup> The concern is that initially the patient will have a "lucid interval" with neurologic deterioration not evident for up to 2 days after the injury when the thrombus has had time to form and propagate toward the cerebral circulation.<sup>7</sup> Clinicians should watch for development of irritability, vomiting, drowsiness, visual changes, seizures, and motor deficits. Transtentorial herniation

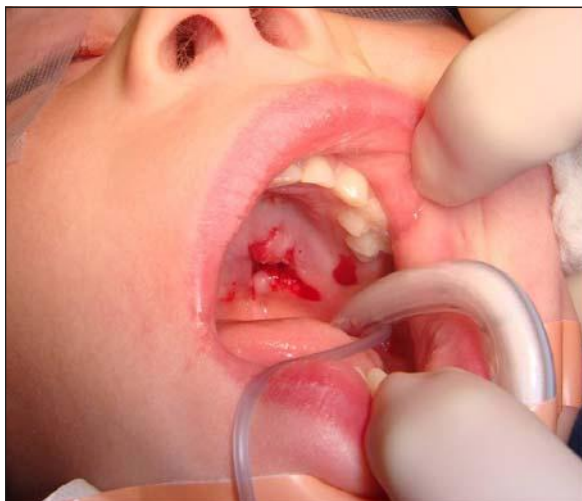

Figure 1. The palatal wound.

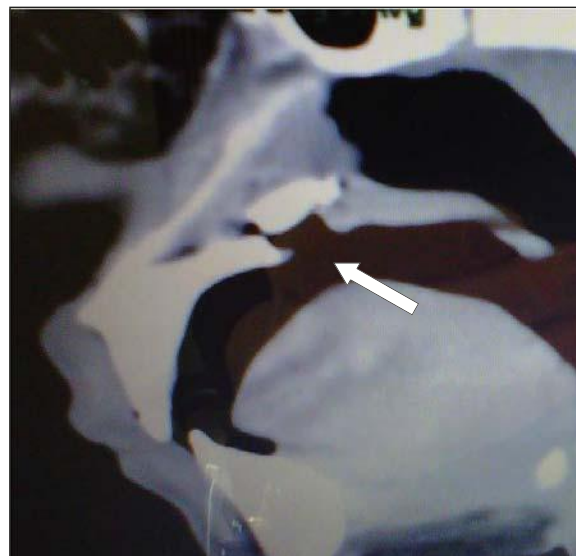

Figure 2. Computed tomography scan image showing displacement of the fractured piece of maxillary bone.

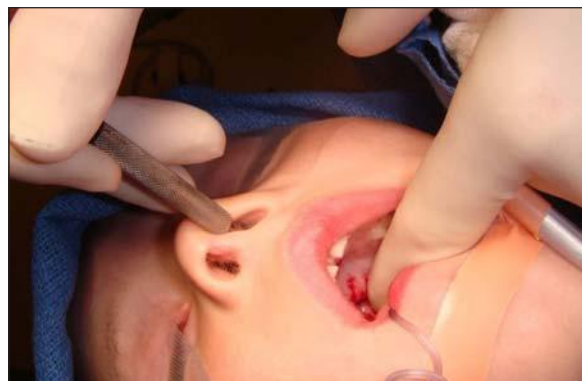

Figure 3. The combination of intraoral digital manipulation and the use of a #15 scaler intranasally successfully repositioned the maxillary bone.

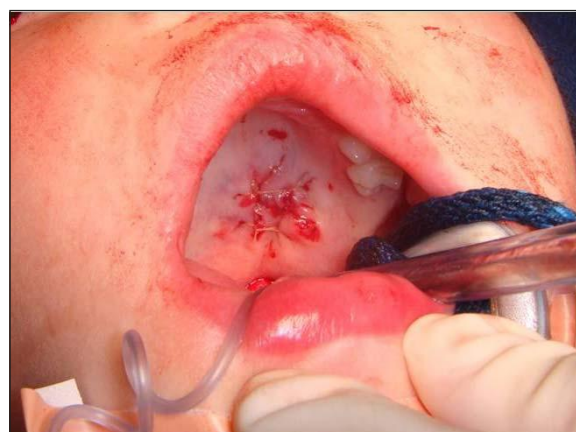

Figure 4. Fast absorbing gut suture was used to close the palatal mucosa.

and death can ensue with progression of a thrombus to the anterior and middle cerebral arteries that produces infarction, edema and mass effect.<sup>8</sup> While only 32 cases of internal carotid artery thrombus have been reported in the English literature prior to 2006,<sup>9</sup> clinicians should be cognizant of its significance.

Raska et al<sup>5</sup> did a review of the literature to provide a recommended treatment protocol for penetrating trauma in children. Some authors suggest that noninvasive angiography studies are as accurate as traditional angiography without the potential complications of catheterization.<sup>10,11</sup> Raska et al recommended angiography to rule out vascular injury once the patient was appropriately resuscitated, and also proposed a more aggressive protocol than some. They felt that traditional angiography remained the gold standard as computed tomography angiography and magnetic resonance

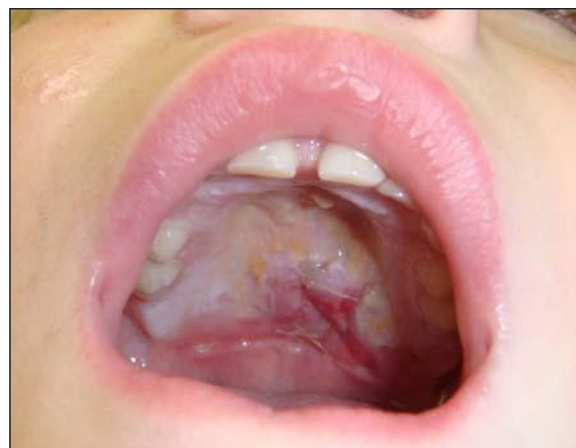

Figure 5. The healing palatal wound.



angiography have proved inferior in detecting vascular injuries in adults. Studies are not available in children because of the infrequency of significant vascular pathology in this population. Biffel et al<sup>12</sup> and Miller et al<sup>13</sup> did prospective studies that support Raska's claim that traditional catheter angiography appears more sensitive at detecting vascular injuries. Hellman's group,<sup>14</sup> however, reviewed 131 cases of impalement injuries over a 17-year period where diagnostic imaging was not performed until development of neurologic deficits and concluded that management and outcomes of oral-pharyngeal palate injuries were not enhanced by prior diagnostic maneuvers.

Some providers will recommend hospitalization and anticoagulation, but this is not a universal approach. Because significant damage to the carotid vasculature is very rare and development of symptoms has been reported to take 96 hours, routine hospitalization for 48 to 72 hours is not universally recommended.<sup>8</sup> Routine hospitalization for observation incurs impractical costs in the current healthcare environment. Hengerer et al<sup>7</sup> reported improvement in neurologic symptoms after initiating anticoagulation, but Frantzen et al<sup>15</sup> did a case series of 8 patients where no difference was noted in outcome. Before considering anticoagulation, dissection must be ruled out. Cothren et al<sup>16</sup> reviewed more than 13,000 blunt trauma cases at a level one trauma center over a 7-year period. Most patients sustained multiple trauma. One hundred fourteen patients had a diagnosed carotid artery injury. Seventy-three were anticoagulated and none developed a stroke. Forty-six percent of the remaining 41 patients not receiving anticoagulation for one reason or another sustained cerebral ischemia. Fabian et al<sup>17</sup> concluded similar benefits of anticoagulation with their 11-year study of blunt carotid injuries. Angiography demonstrated dissections, pseudoaneurysms, thromboses and carotid-cavernous sinus fistulae. The fistulae were surgically repaired. Anticoagulation with heparin resulted in 20% mortality, whereas lack of anticoagulation resulted in 100% mortality. Miller et al<sup>18</sup> noted a stroke reduction from 64% to 6.8% in their study using anticoagulation. Raska et al<sup>5</sup> recommend using enoxaparin sodium, since antiplatelet therapy can be as effective as anticoagulation, while acknowledging that randomized studies do not exist to establish a definitive regimen in the pediatric population.

Recent literature remains inconclusive as to the most appropriate and beneficial regimen for penetrating

palatal trauma in children, given the infrequency of damage to the internal carotid artery (0.6%) and the preferences of various providers, weighing costs and risks.<sup>19</sup> Conservative management is prudent in the majority of cases with judicious use of antibiotics, debridement and repair, and initial consideration of noninvasive imaging. Invasive studies might be indicated if the injury location is more lateral and, thus, more likely to involve the internal carotid artery. Aggressive therapy is warranted in the face of neurologic deficits.

### CONCLUSION

Our case represents an unusual etiology for this type of injury, as the child was not holding the source of impalement, and enough force was generated to actually fracture the bone and not merely rupture the soft tissue. This injury was also located more midline than the majority of cases reported in the literature. She was managed surgically due to the extent of the open wound and consideration for infection, as well as the degree of displacement of bone. Only mild consideration for vascular involvement was entertained. Too often, children are running, playing, or even riding in a moving vehicle with lollipops, popsicles, wands, and other similar "stick items" in their hands or in their mouths. While most patients will never present to medical personnel, impalement injuries should be examined and the possibility of serious consequences considered. It is incumbent upon parents and caregivers to monitor the actions of children. Not all accidents can be prevented, but in doing a risk assessment of certain activities, many traumatic injuries can be prevented. Should a child sustain a penetrating injury to the palate, providers must have a high index of suspicion and use appropriate monitoring and diagnostic modalities to avoid serious morbidity.

---

### REFERENCES

1. Zeltser R, Kalter A, Casap N, Regev E. Oro-pharyngeal impalement injuries in children: report of 2 cases. *J Oral Maxillofac Surg*. 2003;61(4):510-514.
2. Wu K, Ahmed A. Penetrating injury to the soft palate causing retropharyngeal air collection. *Emerg Med J*. 2005;22(2):148-149.
3. Woodhurst WB, Robertson WD, Thompson GB. Carotid Injury due to intraoral trauma: Case report and review of the literature. *Neurosurgery*. 1980;6(5):559-563.

4. Mains B, Nagle M. Thrombosis of the internal carotid artery due to soft palate injury. *J Laryngol Otol.* 1989;103(8):796-797.
5. Raska GM, Cordova SW, Lema R, Goldwasser MS. Management of penetrating trauma to the soft palate: a case report. *J Oral Maxillofac Surg.* 2007;65(7):1279-1285.
6. Higgins GL III, Meredith JT. Internal carotid artery thrombosis following penetrating trauma of the soft palate: an injury of youth. *J Fam Pract.* 1991;32(3):316,319-322.
7. Hengerer AS, DeGroot TR, Rivers RJ, Pettee DS. Internal carotid artery thrombosis following soft palate injuries: a case report and review of 16 cases. *Laryngoscope.* 1984;94:1571-1575.
8. Joseph MJ, Lewis S. Stroke after penetrating trauma of the oropharynx. *Pediatr Emerg Care.* 2002;18(3):179-181.
9. Randall DA, Kang DR. Current management of penetrating injuries of the soft palate. *Otolaryngol Head Neck Surg.* 2006;153(3):356-360.
10. Brietzke SE, Jones DT. Pediatric oropharyngeal trauma: what is the role of CT scan?. *Int J Pediatr Otorhinolaryngol.* 2005;69(5):669-679.
11. Auerbach EG, Martin ET. Magnetic resonance imaging of the peripheral vasculature. *Am Heart J.* 2004;148(5):755-763.
12. Biffi WL, Ray CE Jr, Moore EE, Mestek M, Johnson JL, Burch JM. Noninvasive diagnosis of blunt cerebrovascular injuries: a preliminary report. *J Trauma.* 2002;53:850-856.
13. Miller PR, Fabian TC, Croce MA, Cagiannos C, Williams JS, Vang M, et al. Prospective screening for blunt cerebrovascular injuries: analysis of diagnostic modalities and outcomes. *Ann Surg.* 2002;236(3):386-395.
14. Hellman JR, Schott SR, Gootee MJ. Impalement injuries of the palate in children: review of 131 cases. *Int J Pediatr Otorhinolaryngol.* 1993;26:157-163.
15. Frantzen E, Jacobsen HH, Therkelsen J. Cerebral artery occlusion in children due to trauma to the head and neck. *J Neurol.* 1961;11:695-700.
16. Cothren CC, Moore EE, Biffi WL, Ciesla DJ, Ray CE Jr, Johnson JL, et al. Anticoagulation is the gold standard therapy for blunt carotid injuries to reduce stroke rate. *Arch Surg.* 2004;139(5): 540-546.
17. Fabian TC, Patton JH Jr, Croce MA, Minard G, Kudsk KA, Pritchard FE. Blunt carotid injury: importance of early diagnosis and anticoagulant therapy. *Ann Surg.* 1996;223(5):513-522.
18. Miller PR, Fabian TC, Bee TK, Timmons S, Chamsuddin A, Fikle R, Croce MA. Blunt cerebrovascular injuries: diagnosis and treatment. *J Trauma.* 2001;51(2):279-286.
19. Pereira KD, Wang BS, Webb BD. Impalement injuries of the pediatric craniofacial skeleton with retained foreign bodies. *Arch Otolaryngol Head Neck Surg.* 2005;131(2):158-162.

---

#### AUTHORS

COL Keith is Chief and Program Director, Oral and Maxillofacial Surgery, Madigan Army Medical Health Care System, Joint Base Lewis McChord, Washington.

CPT Clark is Chief Resident, Oral and Maxillofacial Surgery, Madigan Army Medical Health Care System, Joint Base Lewis McChord, Washington.



Insignia of the Madigan Army Medical Center,  
Joint Base Lewis McChord, Washington.

# Pyogenic Granuloma Occurring in a Postmenopausal Woman on Hormone Replacement Therapy

MAJ Thomas M. Johnson, DC, USA  
LTC William J. Demsar, DC, USA  
COL Robert W. Herold, DC, USA  
COL Frederick C. Bisch, DC, USA  
COL Robert C. Gerlach, DC, USA  
COL Gary D. Swiec, DC, USA

## ABSTRACT

Pyogenic granuloma is a benign nodular lesion occurring most commonly on the gingiva of females during periods of elevated sex hormones such as puberty and pregnancy. Possible molecular mechanisms responsible for the appearance of pyogenic granuloma in this demographic have been suggested. Increased incidence of pyogenic granuloma in post menopausal women on hormone replacement therapy has not been reported.

A 49-year-old woman with preexisting titanium implant placement in the left posterior mandible presented with complaint of food impaction and slight discomfort associated with the implant. Clinical examination revealed slight soft tissue erythema and edema, but no foreign body could be identified. Subsequently, a nodular gingival lesion associated with the implant developed and was treated by conservative surgical excision. Histologic characteristics of the lesion were consistent with pyogenic granuloma. The patient was informed of the diagnosis. No evidence of recurrence could be identified after 6 months.

Like peripubertal and pregnant women, postmenopausal women treated with hormone replacement therapy may be at increased risk for pyogenic granuloma. Observational studies designed to establish an association between hormone replacement therapy and pyogenic granuloma have not been conducted. Dentists should be aware of putative pathophysiologic mechanisms for pyogenic granuloma formation and the possibility that hormone replacement may trigger these mechanisms.

The pyogenic granuloma is a pedunculated or sessile nodular lesion commonly encountered intraorally and in extraoral sites. Intraorally, the lesion exhibits a marked predilection for the gingiva, where 75% of all oral pyogenic granulomas occur.<sup>1</sup> The lesion, which has limited growth potential, is considered a reactive process in response to a local irritant rather than a neoplasm. The name of this lesion has persisted despite recognition that the soft tissue growth is unrelated to pyogenic bacterial infection.<sup>1</sup> Furthermore, the lesion is unrelated to granulomatous inflammation, which is characterized by predominance of activated macrophages with epithelioid appearance.<sup>2</sup> The terms *pregnancy tumor* and *granuloma gravidarum* have been used for this lesion due to its association with pregnancy. Another term, *lobular capillary hemangioma*, provides the most accurate clinicopathologic description of the lesion and is perhaps most useful.<sup>1</sup>

Clinically, the surface of a pyogenic granuloma may appear smooth or lobulated, and a progression in color from pink to

red to purple occurs over time.<sup>1</sup> The surface of the pyogenic granuloma may be ulcerated or fibrous depending upon the age of the lesion and the persistence of irritation or trauma. Histologic examination reveals highly vascular tissue resembling normal granulation tissue, with an inflammatory infiltrate consisting of neutrophils, lymphocytes, and plasma cells.<sup>1</sup>

The etiology of pyogenic granuloma is thought to involve an imbalance between inhibitors and enhancers of angiogenesis. Yuan et al reported increased expression of vascular endothelial growth factor (VEGF) and basic fibroblast growth factor (bFGF) and decreased expression of angiostatin and thrombospondin-1 in pyogenic granuloma tissue compared to healthy gingiva and gingiva affected by periodontitis.<sup>3</sup> However, there was no significant difference among the 3 groups in expression of estrogen receptor.<sup>3</sup>

Interestingly, VEGF and bFGF expression has been shown to be higher in pyogenic granulomas during pregnancy,



when steroid hormone levels are high, compared to expression in regressing pyogenic granulomas post partum.<sup>4</sup> Furthermore, the precipitous drop in VEGF after parturition is associated with endothelial apoptosis and regression of pyogenic granuloma.<sup>5</sup> Another mechanism of pyogenic granuloma regression after pregnancy may involve tumor necrosis factor- $\alpha$  (TNF- $\alpha$ ). This macrophage-derived cytokine has been shown to increase upon withdrawal of female steroid hormones.<sup>4,6,7</sup> Downstream molecules in TNF- $\alpha$  signaling have been demonstrated to participate in modulation of angiogenesis and endothelial regression, however, conflicting reports regarding the role of TNF- $\alpha$  signaling in angiogenesis appear in the literature.<sup>8-10</sup> In addition to enhancing expression of proangiogenesis mediators and suppressing expression of angiogenesis inhibitors, female sex hormones may directly inhibit apoptosis of granuloma cells.<sup>4</sup>

## CASE REPORT

A 49-year-old African American woman was referred to the US Army Advanced Education Program in Periodontics, Fort Gordon, Georgia, for crown lengthening of teeth #2-5, #8, and #13-15 prior to definitive prosthetic treatment. Approximately one year prior to the evaluation for crown lengthening, the patient had endosseous implants placed in the posterior mandible bilaterally at another facility. She was asymptomatic at the time of presentation. The patient's past medical history was significant for hyperlipidemia. Her medications included simvastatin, conjugated estrogen, a multivitamin, and an herbal supplement (Tunguska Blast). The patient had a history of 3 caesarean sections, a hysterectomy, and bimaxillary advancement with genioplasty with no complications. She had a history of very light smoking but had not smoked in over 25 years. She reported occasional alcohol use, and her family history was noncontributory.

Five weeks following nonsurgical endodontic therapy of tooth #3, the patient presented for crown lengthening of teeth #2-5 under moderate sedation. The procedure was performed without complication, and the patient exhibited a normal postoperative course. The morning of the appointment for the same procedure on the contralateral side, the patient complained of pain and swelling associated with implant #19 area. She reported eating popcorn and felt that she had an impacted popcorn fragment between the healing abutment and the gingiva.

Clinical examination revealed slight erythema and edema of the keratinized tissue overlying the implant. The healing abutment was removed in attempt to identify a foreign body. No foreign body was found. The site was irrigated thoroughly with chlorhexidine and the healing abutment was replaced. At 2 weeks, a firm ovoid nodule measuring 1 cm  $\times$  1 cm  $\times$  0.7 cm was present (Figure 1). The nodule was

connected to the buccal aspect of the peri-implant tissue by a short, narrow stalk. The pedunculated nodule had a lobular appearance, generally the same color as surrounding tissue, with some areas exhibiting a bluish red hue. The nodule was excised and submitted for histologic analysis with the differential diagnosis of pyogenic granuloma, peripheral ossifying fibroma, peripheral giant cell granuloma, or traumatic fibroma. Histologic evaluation revealed a lobular mass of acute and chronically inflamed granulation-like tissue, with numerous anastomosing vascular channels (Figure 2). A diagnosis of pyogenic granuloma was made. The malpositioned implant was removed (Figure 3), and a new fixture was placed in the correct position (Figure 4).

## DISCUSSION

Pyogenic granulomas have limited growth potential and usually regress after elimination of the precipitating stimulus. For lesions that do not regress, adequate treatment usually consists of conservative surgical excision. Although malignant transformation is not reported, pyogenic granulomas can reach considerable size and be distressing to the patient. Moreover, appearance of the lesion can delay treatment and result in the need for additional procedures.

The effects on periodontal tissues of elevated endogenous steroid hormones during pregnancy and oral contraceptive drugs have long been recognized. The present case is an example of pyogenic granuloma occurring in a postmenopausal woman on hormone replacement therapy (HRT). Postmenopausal osteoporosis is a common problem that accounts for significant morbidity and diminished quality of life among middle-aged women. Patients are diagnosed with osteoporosis when a bone scan reveals a T score less than -2.5 and osteopenia when the T score falls between -1 and -2.5.<sup>11</sup> A wide range of antiresorptive and anabolic agents are available for treatment and prevention of osteoporosis. Estrogens are antiresorptive agents approved by the Food and Drug Administration for prevention only.<sup>11</sup> Estrogens inhibit bone resorption by binding to receptors on osteoblasts, directly increasing production of osteoprotegerin and decreasing production of colony stimulating factor-1.<sup>12</sup> Additionally, estrogens decrease production of TNF- $\alpha$  and interleukin-1 by monocytes within the marrow and may exert an anabolic influence on osteoblasts.<sup>12</sup> Strong evidence suggests that HRT has a large, favorable effect on bone mineral density in postmenopausal women.<sup>13</sup> Furthermore, decreased bone mineral density is associated with increased fracture risk.<sup>14</sup> Data from the Womens Health Initiative suggests a reduction in hip fracture risk of 36% to 39% for patients taking HRT.<sup>15,16</sup> In addition to slowing the decline in bone mineral density after menopause, estrogens may have other beneficial effects including possible protection against endometrial and colorectal cancer.<sup>15</sup> However, risks associated with HRT are concerning. Specific risks may be dependent upon whether the patient has a history of

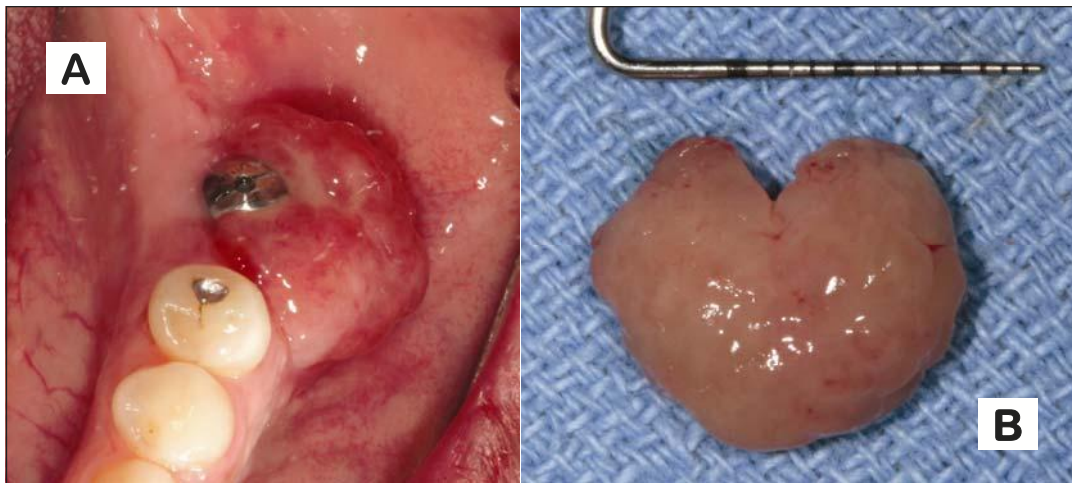


Figure 1. Preoperative clinical appearance (A) and post excision (B).

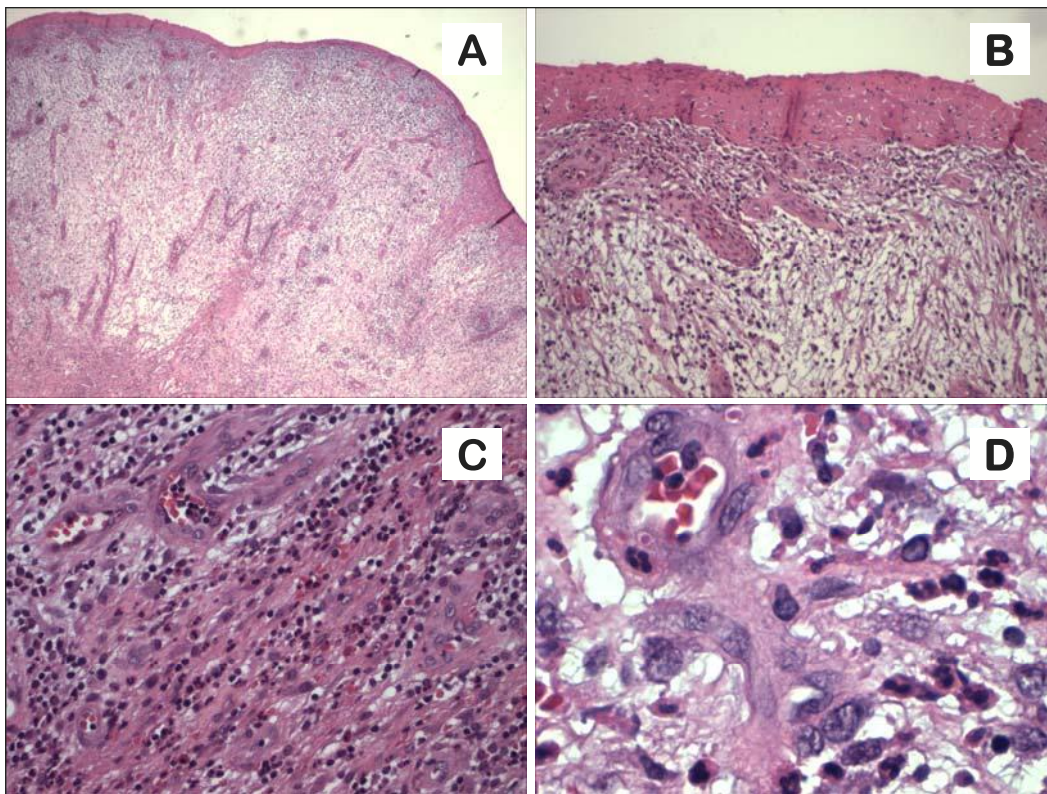


Figure 2. Histomicrographs of lesion. Frame A: Low power (2x) hematoxylin and eosin staining revealed a lobular mass of granulation-like tissue, with numerous anastomosing vascular channels. The ulcerated surface was replaced with a fibrinous exudate. Frame B: 10x view of fibrinous exudate of ulcerated surface. Note the chronically inflamed edematous fibrovascular connective tissue. Frame C: 20x view demonstrating acute and chronically inflamed fibrous connective tissue with numerous thin-walled blood vessels of varying sizes. Frame D: High power 60x view demonstrating vascular channels lined by plump endothelial cells within an edematous delicate fibrovascular stroma with acute and chronic inflammatory cell infiltrate.



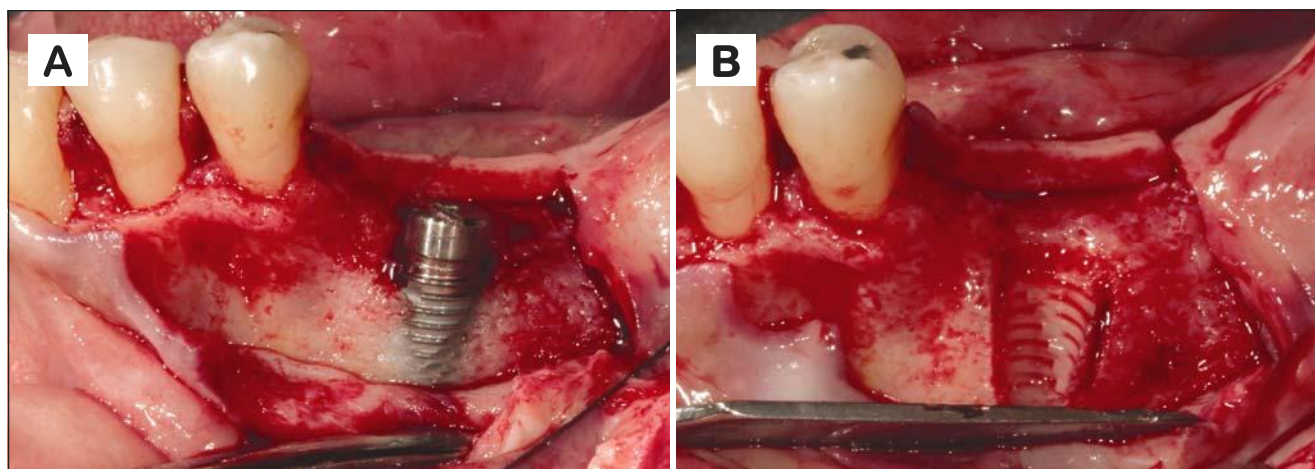


Figure 3. The implant present on initial presentation (A) was malpositioned distobuccally and had excessive distal inclination relative to the occlusal plane. The implant was removed via conservative osteotomy (B) using a fine-tipped piezoelectric instrument.

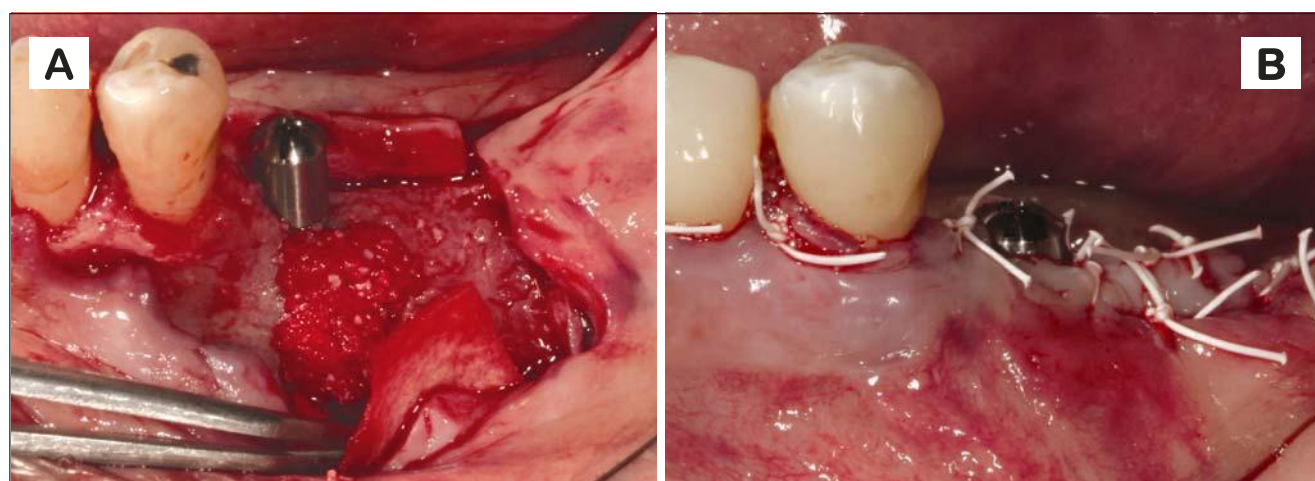


Figure 4. A new 4.0 x 10mm titanium implant was placed mesiolingual to the original implant and with a more upright inclination. The defect resulting from removal of the malposed fixture was addressed using a mixture of anorganic bovine matrix and collagen as well as a resorbable collagen membrane (A). The surgical wound was closed with 5-0 Gortex sutures (B).

hysterectomy and the particular HRT regimen. Healthy postmenopausal women with no history of hysterectomy taking estrogen plus progestin appear to be at increased risk of coronary heart disease, stroke, pulmonary embolism, and breast cancer.<sup>15</sup> Postmenopausal women with history of hysterectomy taking conjugated equine estrogen alone appear to be at increase risk of stroke but not coronary heart disease, and these patients may have no increase or even a reduced risk of breast cancer.<sup>16,17</sup>

Studies of the relationship between female sex hormones and pyogenic granuloma formation suggest that elevated steroid hormone levels may create an imbalance between angiogenesis enhancers and inhibitors. This mechanism may represent the basis for increased incidence of pyogenic granuloma in peripubertal and pregnant women. It seems

biologically plausible that post menopausal women taking hormone replacement therapy would experience a similar increased incidence of pyogenic granuloma. However, no investigations of such a relationship appear in the literature. Clinicians should be aware of putative pathophysiologic mechanisms for pyogenic granuloma formation and the possibility that hormone replacement may trigger these mechanisms.

## REFERENCES

1. Neville BW, Damm DD, Allen CM, Bouquot JE. *Oral and Maxillofacial Pathology*. 2nd ed. Philadelphia: WB Saunders and Company; 2002:447-449.



2. Cotran RS, Kumar V, Collins T. *Robbins Pathologic Basis of Disease*. 6th ed. Philadelphia: WB Saunders and Company; 1999:532-533.
3. Yuan K, Jin YT, Lin MT. The detection and comparison of angiogenesis-associated factors in pyogenic granuloma by immunohistochemistry. *J Periodontol*. 2000;71(5):701-709.
4. Yuan K, Wing LYC, Lin MT. Pathogenic roles of angiogenic factors in pyogenic granulomas in pregnancy are modulated by female sex hormones. *J Periodontol*. 2002;73(7):701-708.
5. Yuan K, Lin MT. The roles of vascular endothelial growth factor and angiopoietin-2 in the regression of pyogenic granuloma. *Oral Dis*. 2004;10(3):179-185.
6. Tabibzadeh S, Sataswaroop PG, von Wolff M, Strowitzki T. Regulation of TNF-alpha mRNA expression in endometrial cells by TNF-alpha and by estrogen withdrawal. *Mol Hum Reprod*. 1999;5(12):1141-1149.
7. Pacifici R, Brown C, Puscheck E, Friedrich E, Slatopolsky E, Maggio D, et al. Effect of surgical menopause and estrogen replacement on cytokine release from human blood mononuclear cells. *Proc Natl Acad Sci U S A*. 1991;88(12):5134-5138.
8. Asahara T, Chen D, Takahashi T, Fujikawa K, Kearney M, Manger M, et al. Tie2 receptor ligands, angiopoietin-1 and angiopoietin-2, modulate VEGF-induced postnatal neovascularization. *Circ Res*. 1998;83(3):233-240.
9. Hanahan D. Signaling vascular morphogenesis and maintenance. *Science*. 1997;277(5322):48-50.
10. Kim I, Kim JH, Ryu YS, Liu M, Koh GY. Tumor necrosis factor-alpha upregulates angiopoietin-2 in human umbilical vein endothelial cells. *Biochem Biophys Res Commun*. 2000;269(2):361-365.
11. Rosen CJ. Clinical practice. Postmenopausal Osteoporosis. *N Engl J Med*. 2005;353(6):595-603.
12. Eastell R. Role of oestrogen in the regulation of bone turnover at the menarche. *J Endocrinol*. 2005;185(2):223-234.
13. Wells G, Tugwell P, Shea B, Guyatt G, Peterson J, Zytaruk N, et al. Meta-analyses of therapies for postmenopausal osteoporosis. V. Meta-analysis of the efficacy of hormone replacement therapy in treating and preventing osteoporosis in postmenopausal women. *Endocr Rev*. 2002;23(4):529-539.
14. Marshall D, Johnell O, Wedel H. Meta-analysis of how well measures of bone mineral density predict occurrence of osteoporotic fractures. *Br Med J*. 1996;312(7041):1254-1259.
15. Rossouw JE, Anderson GL, Prentice RL, LaCroix AZ, Kooperberg C, Stefanick ML, et al. Risks and benefits of estrogen plus progestin in healthy postmenopausal women: principal results from the Women's Health Initiative randomized controlled trial. *JAMA*. 2002;288(3):321-333.
16. Anderson GL, Limacher M, Assaf AR, Bassford T, Beresford SA, Black H, et al. Effects of conjugated equine estrogen in postmenopausal women with hysterectomy: the Women's Health Initiative randomized controlled trial. *JAMA*. 2004;291(14):1701-1712.
17. Stefanick ML, Anderson GL, Margolis KL, Hendrix SL, Rodabough RJ, Paskett ED, et al. Effects of conjugated equine estrogens on breast cancer and mammography screening in postmenopausal women with hysterectomy. *JAMA*. 2006;295(14):1647-1657.

---

#### AUTHORS

MAJ Johnson is Chief of Periodontics, US Army Dental Activity, US Military Academy, West Point, New York.

LTC Demsar is Chief, Oral and Maxillofacial Pathology, William Beaumont Army Medical Center, Fort Bliss, Texas.

COL Herold is an Assistant Director of the US Army Advanced Education Program in Periodontics, Tingay Army Dental Clinic, Fort Gordon, Georgia.

COL Bisch is Director, US Army Advanced Education Program in Periodontics, Tingay Army Dental Clinic, Fort Gordon, Georgia.

COL Gerlach is an Assistant Director of the US Army Advanced Education Program in Periodontics, Tingay Army Dental Clinic, Fort Gordon, Georgia.

COL Swiec is Chief of Periodontics, Fort Meade Dental Activity and is the Consultant to The Army Surgeon General for Periodontics.

# An Aggressive Benign Cementoblastoma

COL (Ret) Richard E. Collins, DC, USAR  
Rafael Flores Asturias, DDS

## ABSTRACT

The case of a 19-year-old woman with benign cementoblastoma is described along with a brief review of the literature and clinopathology of the lesion. This lesion developed a more aggressive nature. A discussion of treatment and rationale is included.

## INTRODUCTION

Benign cementoblastoma is one of 4 World Health Organization recognized cemental neoplasms. The others include periapical cementosseous dysplasia, cementifying fibroma and gigantiform familial cementoma. Benign cementoblastoma is a slow-growing benign tumor arising from cementoblasts. The tumor is fused to the partly resorbed root(s) of the associated tooth. Radiographically, it appears as a dense radiopacity with a peripheral radiolucent border. The benign cementoblastoma is associated with mild pain and can produce jaw expansion as the tumor enlarges. Pynn describes the tumor histologically in his case report, "the lesion consists of broad trabeculae and sparsely cellular cementum. These merge with areas of cemental islands in a vascular stroma with prominent characteristic radiating columns of cementum running perpendicular to the surface of the lesion."<sup>1</sup>

## REVIEW OF THE LITERATURE

Although Norgberg states that this lesion was first recognized in 1930,<sup>2</sup> Bouquot reports that the lesion was described in 1839.<sup>3</sup> This tumor is unusual, with fewer than 100 cases reported and represents less than 1% of odontogenic tumors. Ulmanky et al cite pain, expansion, and a radiopaque lesion with a radiopaque "halo" as the most characteristic features of the lesion.<sup>4</sup> Eversole proposed that this tumor may reach maximum proportions before mineralization, and the classical radiographic appearance is secondary.<sup>5</sup> There is a predilection for females under the age of 25, with the mandible being by far the most common location. The tumor has been associated with multiple teeth,

impacted molars, and deciduous teeth. Noteworthy is the observation that 90% of the cases involve the first molar/premolar area.<sup>1</sup> There have been reports of aggressive behavior,<sup>6,7</sup> however, this is considered a benign lesion and does not require radical surgical treatment. The treatment of choice is complete removal by enucleation with extraction of the associated teeth.<sup>1</sup> Biggs and Benenati describe a more conservative approach performing an endodontic procedure on the involved tooth and surgically removing the tumor.<sup>8</sup>

## CASE REPORT

A 19-year-old Guatemalan woman presented at a Chimaltenango volunteer dental clinic on February 1, 2006, with a chief complaint of moderate pain in her left mandible of approximately 20 months duration. There had been no history of previous infection associated with the lesion. The patient stated that she had some type of growth in her left mandible and had undergone a "scraping" procedure in Guatemala City in 2005. Clinical examination revealed no facial swelling, and all vital signs within normal limits. Intraorally there was buccal and lingual expansion of the area of the left first mandibular molar and the left second mandibular bicuspid (Figure 1). The gingivae

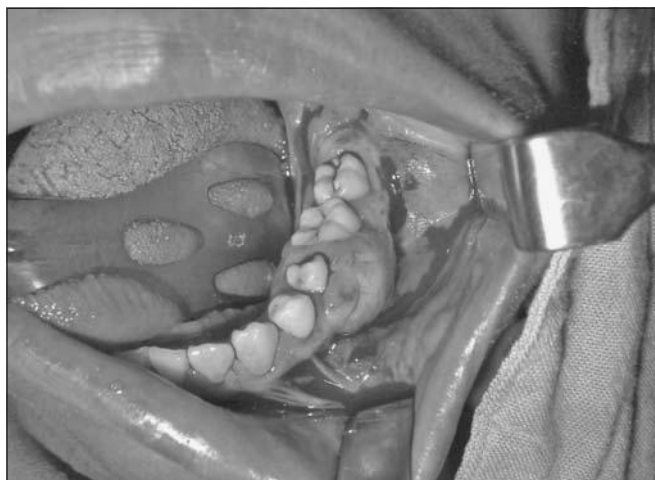

Figure 1. Buccal and lingual expansion of the area of the left first mandibular molar and second mandibular bicuspid.

had a red velvety appearance. There was no cellulitis or suppuration. There was no mandibular nerve dysthesia, and all teeth in the quadrant tested vital. Pain was noted when biting on teeth numbers 19 and 20 or by applying moderate finger pressure to the expanded areas. The patient also stated that the discomfort had almost disappeared after the initial procedure, but that it was now returning and increasing in intensity at a noticeable pace. A panorex radiograph dated May 18, 2004, demonstrated a well-demarcated lesion, surrounded by a radiolucent halo at the apices of teeth numbers 19 and 20 (Figure 2). A panorex taken on February 1, 2006 (Figure 3), revealed a much larger and irregular radiopaque lesion with a more disorganized center and displacement of the inferior alveolar canal inferiorly, as well as bowing of the inferior border of the mandibular left side. Given the relatively rapid increase in size of the lesion in 18 months, the patient was referred to an oral and maxillofacial surgeon in Guatemala City for evaluation and treatment.

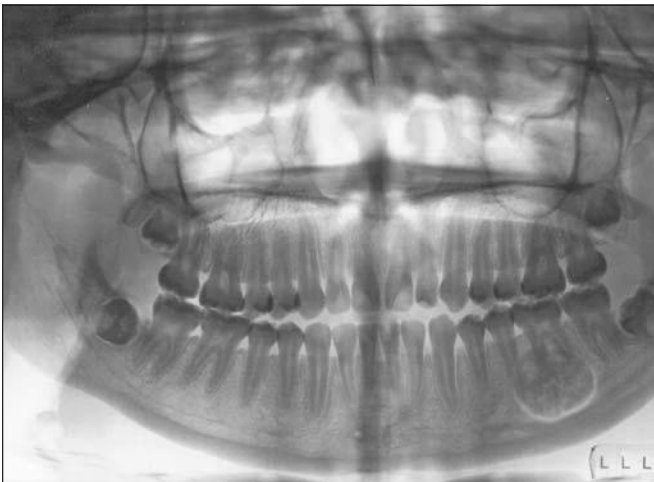

Figure 2. The panorex radiograph image of the lesion (note surrounding halo, lower right side) dated May 18, 2004.

After evaluation by this specialist, a differential diagnosis was developed:

- Benign cementoblastoma
- Focal cementossseous dysplasia
- Cementofying fibroma

The surgical plan was to remove teeth numbers 1, 16, 17, 19, 20, and 32, and to enucleate the lesion transorally. The procedure was performed on September 20, 2006, at an outpatient oral surgery center in Guatemala City under general anaesthesia. A

crevicular incision from the midline with a buccal release was extended to the left proximally to No. 17 area (Figure 4). As the mucoperiosteal flap was elevated, the mental nerve was noted, as well as buccal expansion of the cortical plate adjacent to teeth numbers 19 and 20 (Figures 5, 6). Teeth numbers 17, 19, and 20 were then removed. The buccal plate adjacent to the lesion was removed. At this point, because of concern for possible fracture of the inferior border of the mandible below #19 when the tumor was removed, a 2.4 titanium reconstruction plate was placed at the inferior border transorally with 4 screws (Figure 7). The tumor was then enucleated. The lingual plate was noted to be partially absorbed. A 2.0 titanium tension band plate was then placed with 7 screws (Figure 8).

The mandibular neurovascular bundle was within the lesion and was removed along with the tumor in the area of numbers 19 and 20. After removal of teeth numbers 1, 16, and 32, the defect was irrigated with

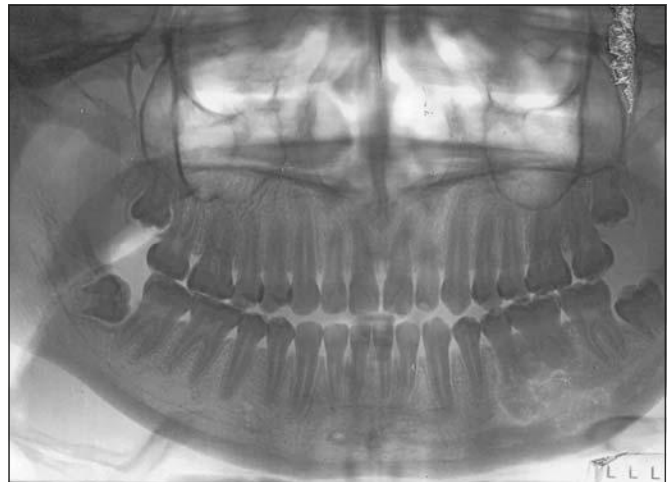


Figure 3. Panorex radiograph image dated February 1, 2006. Note the increased size of the lesion (image lower right side) in comparison with that shown in Figure 2.

saline and closed with 3-0 polyglactic suture. The patient tolerated the procedure well, and the specimens were submitted to pathology, which returned a report with a final diagnosis as benign cementoblastoma. After 3 weeks, she returned for a follow-up examination and panorex (Figure 9) without pain or swelling. She did, however, have anaesthesia in the distribution of the left mental nerve. On her follow-up exam on May 9, 2007, there was bony regeneration of the surgical defect and the oral tissues were within normal limits; paresthesia remained, but had diminished slightly over the intervening months.



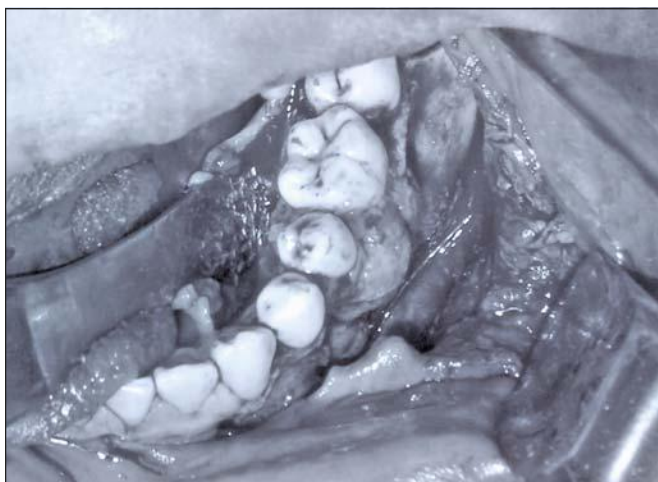

Figure 4. The crevicular incision to the left proximal to the area of tooth #17.

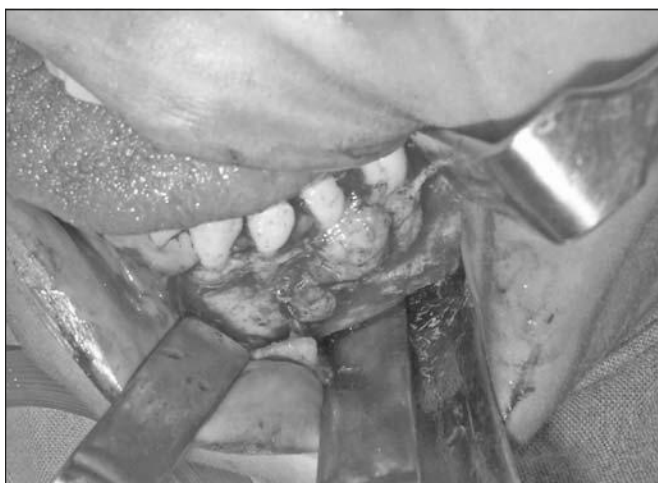

Figure 5. The elevated mucoperiosteal flap reveals the mental nerve and the buccal expansion of the cortical plate next to teeth numbers 19 and 20.

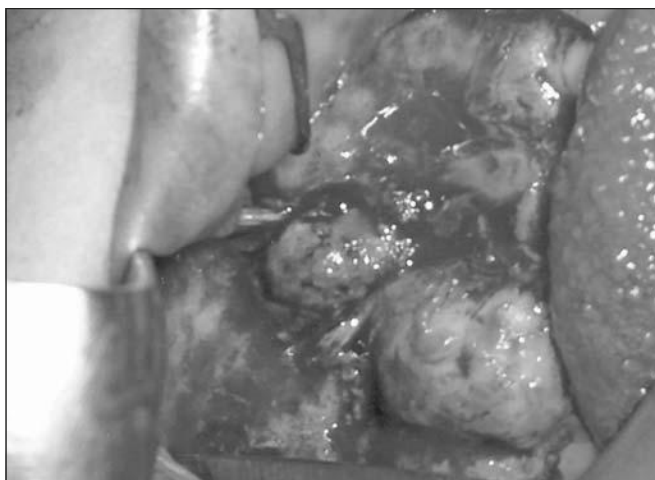


Figure 6. A closer view of the exposed mental nerve and buccal expansion of the cortical plate next to teeth numbers 19 and 20.

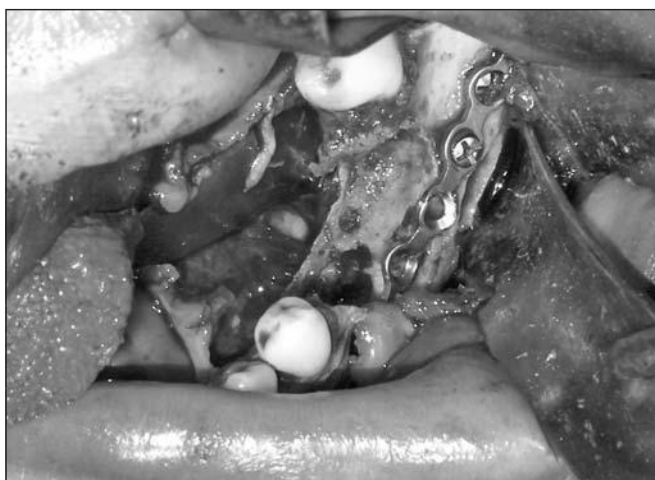

Figure 7. A 2.4 titanium reconstruction plate was placed transorally with 4 screws to protect the inferior border of the mandible before the tumor was removed.

## DISCUSSION

A case of benign cementoblastoma is presented. This lesion had a number of characteristics seen in this group of tumors. The patient's age, sex, location, and initial radiographic presentation all were consistent with benign cementoblastoma. However, the behavior of the lesion, with rapid growth over 18 months after the "scraping" procedure, was a concern. Langdon<sup>7</sup> reported a similar case and made the following observations:

- The lesion secondarily did not present with a classical radiographic appearance and did not grow slowly.
- Stimulus of the lesion produced rapid growth.
- His pathology report stated that the lesion "was not an inflammatory process". (No such wording was found in the pathology of this case). Given the facts that the patient was otherwise healthy and had never been pregnant, the question arises; what accounted for the rapid extension of the tumor? It is significant that she had some type of incomplete surgical "scraping" procedure the previous year. One can only speculate that it stimulated an acceleration of tumor growth. This activity would parallel tumor overgrowth in children with cherubism who are injudiciously subjected to premature reshaping procedures in the mandible.

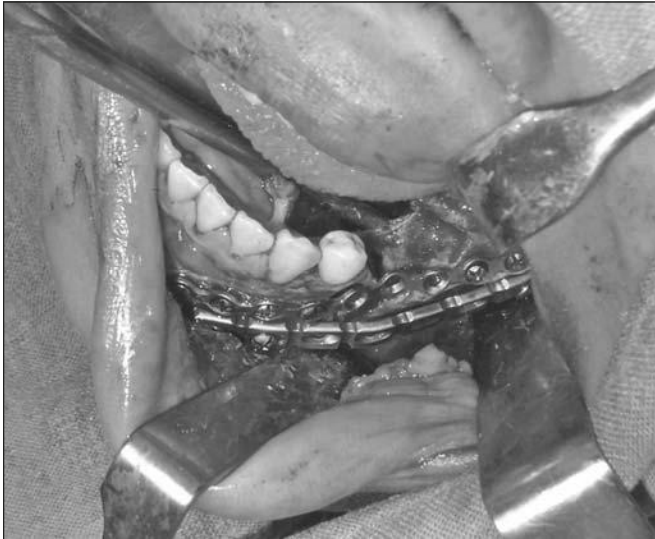

Figure 8. A 2.0 titanium tension band plate was placed with 7 screws after the tumor was enucleated.

In planning this case, the problem list included:

- Postoperative morbidity to the mandibular neurovascular bundle due to the proximity of the tumor and/or plating screws.
- Intra or postoperative mandible fracture from the tumor removal.
- Necessity for autogenous bone graft reconstruction intra or postoperatively.
- Transoral vs. percutaneous surgical approach.
- Loss of vitality to the teeth adjacent to the lesion (numbers 18 and 21).
- Reoccurrence of the lesion.

Judicious presurgical planning paid dividends in the outcome of this case.

- The procedure was performed transorally.
- The involved teeth as well as 4 impacted third molars were removed.
- A reconstruction plate was placed at the inferior border transorally to obviate an intraoperative fracture.
- The mandibular neurovascular bundle was removed along with the tumor.
- Due to the patient's age and mandibular vascularity, no reconstruction was necessary as the defect filled by osteoneogenesis.

The patient will be followed at yearly intervals. Teeth numbers 19 and 20 will be replaced with a prosthesis.

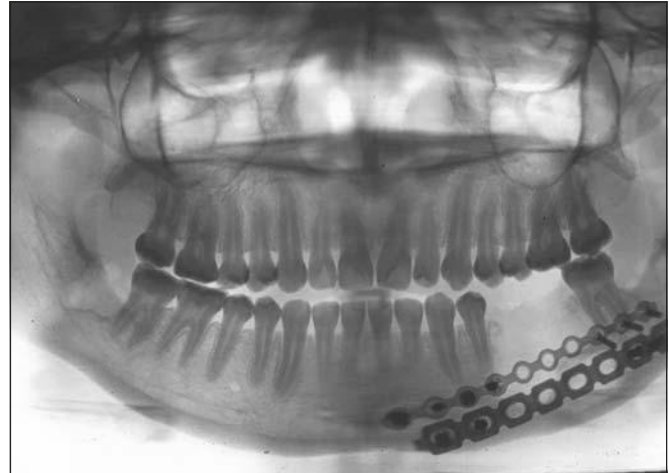

Figure 9. The panorex radiograph image 3 weeks postsurgery.

#### ACKNOWLEDGEMENT

The authors thank COL (Ret) James V. Johnson (DC, USAR), who was instrumental in helping to raise funds and obtain oral surgery hardware, and for his review of this manuscript. We also thank MAJ Chris Collins, MC, USA, for his assistance in assembly, organization, and review of the pictures, slides, pathology reports, etc.

#### REFERENCES

1. Pynn BR, Sands TD, Bradley G. Benign cementoblastoma: a case report. *J Can Dent Assoc.* 2001;67(5):260-262.
2. Norberg O. Zur Kenntnis der dysontogenetischen Geschwulste der Kieferknochen. *Wschr Zahnheilkd.* 1930;46:321-355.
3. Bouquot JE, Lense EC. The beginning of oral pathology: part 1: first dental journal reports of odontogenic tumors and cysts, 1839-1860. *Oral Surg Oral Med Oral Pathol.* 1994;78:343-350.
4. Umansky M, Hjorting-Hansen E, Praetorius F, Hacque MF. Benign cementoma: a review and five new cases. *Oral Surg Oral Med Oral Pathol.* 1994;77:48-55.
5. Eversole LR, Sabes WR, Dauchess VG. Benign cementoblastoma. *Oral Surg Oral Med Oral Pathol.* 1973;36:824-829.

#### AUTHORS

COL (Ret) Collins is the former (retired) Endodontic Coordinator in the Managed Health Care Division of the University of Texas Medical Branch at Galveston.

Dr Flores is an oral and maxillofacial surgeon practicing in Guatemala City, Guatemala.

# Dental Rehabilitation of a Patient with Dentinogenesis Imperfecta: A Clinical Report

COL David A. Mott, DC, USA  
LTC (P) Minaxi I. Patel, DC, USA  
LTC Dong Soo Park, DC, USA

## ABSTRACT

This clinical report describes the multidiscipline treatment for a 19-year-old service member who entered the military diagnosed with dentinogenesis imperfecta. The patient presented with multiple teeth with extensive dental caries, considerable sensitivity, and an inability to function due to the extent of the dental disease. The goal of the treatment was to restore function and aesthetics. A combined treatment approach was initiated which involved prosthodontics, periodontics, and dental implant therapies. Functional and aesthetic results were achieved.

## OVERVIEW: DENTINOGENESIS IMPERFECTA

Dentinogenesis imperfecta (DGI) is defined as an autosomal dominant disorder in dentin mineralization in both the primary and permanent dentitions.<sup>1</sup> DGI is the most common of all dental genetic diseases affecting some 1:8000 births.<sup>2</sup> Dentinogenesis Imperfecta can be grouped into 3 clinical entities, Shields Type I, II, and III. There are several known subtypes and all share a common clinical appearance.<sup>3</sup>

Common characteristics include uniform yellow to blue crowns with enamel that easily fractures due to the poor dentin support. The crowns are usually bulbous or bell shaped with short roots and pulp chambers, which presents narrowed by an excessive production of the defective mineralized dentin matrix.<sup>4</sup> The defective dentin, shown in Figure 1, has a yellow translucent hue and takes on a characteristic gray to brownish-blue discoloration that has prompted the term hereditary opalescent dentin.<sup>5</sup>

In Dentinogenesis Imperfecta Type I, the dentin mineralization defects are coupled with Osteogenic Imperfecta related bone diseases characterized by a systemic condition involving bone fragility, blue sclera of the eyes, joint laxity, and hearing impairment. It is caused by a defect in collagen formation. DGI-II (hereditary opalescent dentin) has the same dentin defects as DGI-I but has not been found to be related to any collagen defect and has no osteogenic component. DGI-III, also known as Brandywine type, is a complex heterogeneous

disorder, which occurs in an isolated racial group. Both collagen and mineralization are affected and the teeth appear opalescent as in DGI types I and II but have a shell-like appearance. It was initially described in a triracial, isolated population in Brandywine, Maryland.<sup>6,7</sup> Diagnosis is based on a thorough family history, pedigree construction, and detailed clinical examination. Differential diagnosis may include hypocalcified form of amelogenesis imperfecta, congenital erythropoietic porphyria, Kostmann's condition (conditions leading to early tooth loss), cyclic neutropenia, Chediak-Hegashi syndrome, histiocytosis X, Papillon-Lefevre syndrome, tetracycline discoloration and staining of the teeth, vitamin D-dependent and vitamin D-rickets.<sup>8</sup>

## CLINICAL REPORT

A 19-year-old service member presented for routine dental treatment with a chief complaint/concern of pain, sensitivity, difficulty chewing, and overall displeasure with the appearance of her teeth. A review of the patient's health questionnaire revealed a medical history that was significant for a smoking habit and multiple family members with the same dental presentation. Extraoral examination revealed slight tenderness when palpating the masseter and temporalis muscles. Tenderness was thought to be related to poor occlusion. Intraoral examination revealed yellowish to blue-gray appearance of the anterior dentition and extensive dental caries associated with most maxillary and mandibular

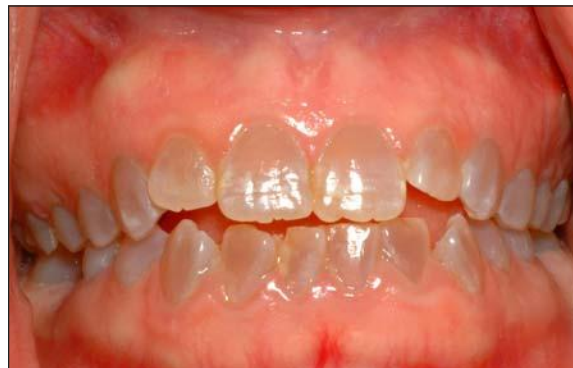

Figure 1. Pretreatment anterior view of 19 year-old service member with yellowish gray crowns, defective enamel and dentin, midline discrepancy and aesthetic disharmonies.



## Dental Rehabilitation of a Patient with Dentinogenesis Imperfecta: A Clinical Report

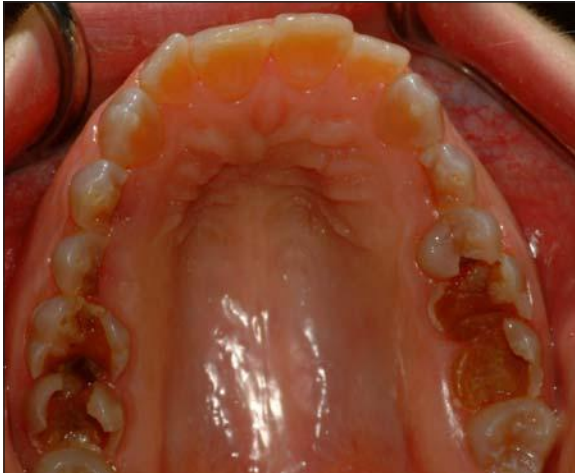

Figure 2. Pretreatment maxillary occlusal view revealing extensive dental caries and destruction of enamel and dentin.

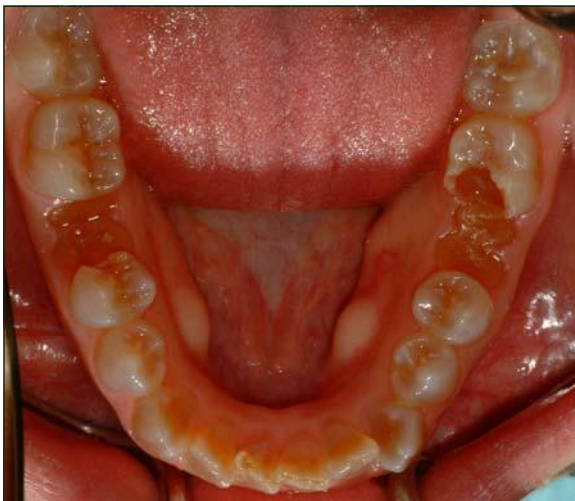

Figure 3. Pretreatment mandibular occlusal view revealing extensive dental caries.

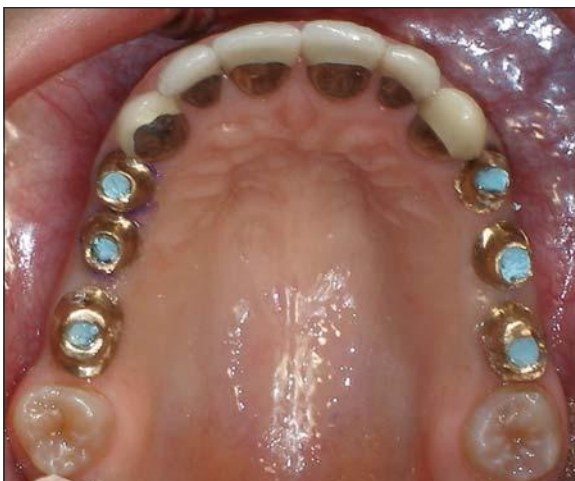

Figure 4. Maxillary occlusal view showing full coverage with porcelain fused to metal crowns on remaining maxillary teeth and implant abutments to replace premolars and molars.

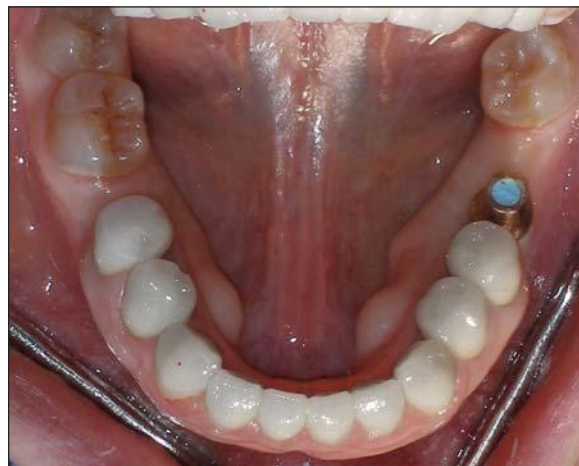

Figure 5. Mandibular occlusal view showing full coverage crowns on anterior teeth and implant abutments to replace molar.

posterior teeth. The patient stated that many teeth would break easily with normal function (Figure 2). The prosthodontic evaluation revealed a dental midline discrepancy, short clinical crowns complicated with extensive dental caries, malalignment of the anterior teeth, and occlusal and aesthetic disharmonies. Photographs, radiographs, and dental casts were completed. A comprehensive periodontal review confirmed gingival tissues as firm and fibrotic, generalized 2 mm to 3 mm periodontal probe depths, moderate to heavy plaque with slight calculus accumulation, extensive caries, and bilateral mandibular lingual tori (Figure 3). The patient was referred to the oral pathologist and the diagnosis of dentinogenesis imperfecta was confirmed.

Complete rehabilitation of the dentition was based on the patient's desires, clinical findings, radiographic evaluation, and periodontal health. The treatment plan involved extraction of all hopeless teeth with extensive dental caries (numbers 3, 4, 5, 12, 13, 14, 18, and 19) and fabricating an interim removable partial denture. The fabrication and placement of the interim removable partial denture and provisional crowns appeared to resolve the facial muscle tenderness and reestablished occlusal support. Following the healing process and the reevaluation phase, the patient was treatment planned to have dental implants placed for teeth numbers 3, 4, 5, 12, 13, 14, and 19 (4.0×11.5 and 5.0×11.5; 3i-Implant Innovations Inc, Palm Beach Garden, FL). After adequate healing and implant integration, implants supported metal ceramic crowns were fabricated. Metal ceramic crowns were also fabricated for the remaining maxillary and mandibular teeth (numbers 6, 7, 8, 9, 10, 11, 20, 21, 22, 23, 24, 25, 26, 27, 28, 29) (Figures 4 and 5).

The combined treatment plan with the prosthodontist and periodontist provided for the complete rehabilitation with full function and aesthetics. All aspects of the patient's concerns

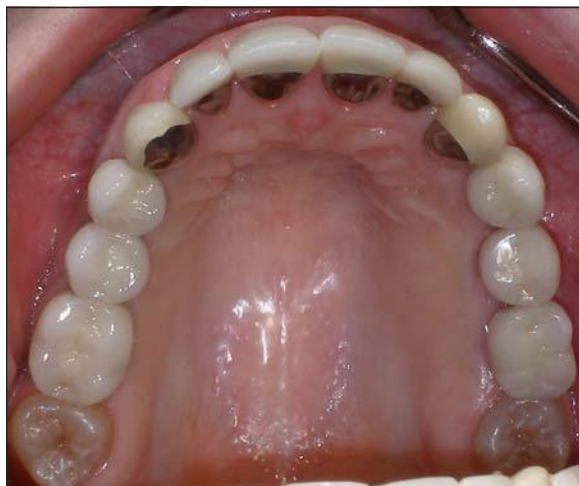

Figure 6. Post treatment maxillary occlusal view showing porcelain fused to metal completed restorations of the dental implants, teeth numbers 3, 4, 5, 12, 13, 14.

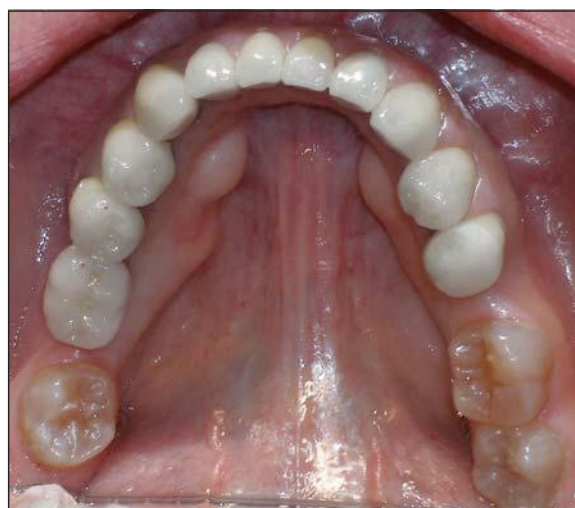

Figure 7. Post treatment mandibular occlusal view showing porcelain fused to metal completed restoration of the tooth #19 dental implant.

were addressed with complete resolution of the patient's chief concern. The prosthodontic phases of treatment included preparation and provisionalization of all remaining teeth. All restorations were characterized, glazed, polished, and then luted with permanent cement (Figures 6, 7, 8). Home care instructions were provided and the patient was scheduled for periodic maintenance care.

## REFERENCES

1. Witkop C. Hereditary defects of dentin. *Dent Clin North Am.* 1975;19:25-45.
2. Neville BW, Damm DD, Allen CM, Bouquot JE. *Oral and Maxillofacial Pathology*. Philadelphia, Pennsylvania: W.B. Saunders Company; 1995:84-87.
3. Shields ED, Bixler D, El-Kafrawy AM. A proposed classification for heritable human dentine defects with a description of a new entity. *Arch Oral Biol.* 1973;18:543-553.
4. Regezi JA, Sciubba J. *Oral Pathology, Clinical Pathologic Correlations*. 2nd ed. Philadelphia, Pennsylvania: W.B. Saunders Company; 1993:509-510.
5. Regezi JA, Sciubba JJ, Pogrel MA. *Atlas of Oral and Maxillofacial Pathology*. Philadelphia, Pennsylvania: W.B. Saunders Company; 2000:152.
6. Langlais, RP, Miller CS. *Color Atlas of Common Oral Diseases*. 2nd ed. Baltimore, Maryland: Williams & Wilkins; 1998:32.
7. Hursey RJ Jr, Witkop CJ, Miklashek D, Sackett LM. Dentinogenesis imperfecta in a racial isolate with multiple hereditary defects. *Oral Surg Oral Med Oral Pathol.* 1956;9:641-658.
9. Barron MJ, McDonnell ST, Mackie I, Dixon MJ. Hereditary dentine disorders: dentinogenesis imperfect and dentine dysplasia. *Orphanet Journal of Rare Diseases* [serial online]. November 20, 2008;doc 3:31.

## AUTHORS

COL Mott is Commander, US Army Dental Activity – Japan, Camp Zama.

LTC (P) Patel is Chief, Prosthodontics Services, US Army Dental Activity, Fort Stewart, Georgia.

LTC Park is Officer-in-Charge and Chief, Periodontics Services, US Army Carius Dental Clinic, Seoul, South Korea.

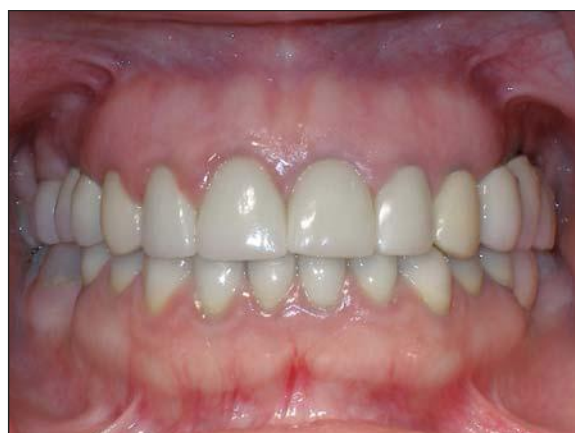

Figure 8. Post treatment anterior occluded view.



# Solid Ameloblastoma, Resection to Reconstruction: A Case Report

MAJ Michael J. Ryhn, DC, USA  
COL Jeffrey S. Almony, DC, USA  
COL Albert M. Manganaro, DC, USA

## INTRODUCTION

The ameloblastoma is the most commonly found odontogenic neoplasm.<sup>1-3</sup> It is considered a benign neoplasm with aggressive tendencies. While it rarely metastasizes, it can recur with treatment other than resection and sometimes even with resection.<sup>3,4</sup> Presented is a case of a US Soldier from initial diagnosis, to resection, bone grafting, and reconstruction with dental implants and a fixed dental prosthesis.

## REPORT OF THE CASE

A 28-year-old female Soldier presented to the Landstuhl Oral and Maxillofacial clinic after redeployment from Iraq for left mandibular swelling in July 2005. The patient presented with a chief complaint of "pressure when biting." Physical exam was significant for slight mobility of the left second premolar and buccal expansion of the mandible in the same region. A panoramic radiograph showed a well defined, corticated, multilocular radiolucent lesion in the region of the left premolar-molar region. The patient's medical history was significant for exercise induced asthma and a penicillin allergy. Under local anesthesia, a biopsy of the cortical bone and soft tissue was taken and submitted to the oral pathologist.

Microscopically, the specimen consisted of variably dense fibrocollagenous tissue with numerous islands of odontogenic epithelium that exhibited central cystic changes. The basal epithelium was composed of columnar cells with hyperchromatic nuclei. The nuclei of the columnar cells were polarized away from the surrounding connective tissue. The lesion was diagnosed as a solid ameloblastoma, follicular variant (Figure 1).

The patient was redeployed from Iraq to her home station of Fort Bragg, North Carolina. The patient was then treatment-planned for en bloc resection. On August 30, 2005, she underwent a 5 cm left mandibular resection as well as removal of the left lateral incisor,

canine, premolars and molars (Figure 2). A Walter-Lorenz 2.4 mm reconstruction plate, which was pre-bent using a stereolithic model, was placed to prevent a continuity defect (Figure 3).

In January 2006, the patient returned to the operating room for a left anterior superior iliac crest graft to the left mandible as well as placement of a cadavaric mandibular crib.

Postoperative healing was unremarkable until March 2006 when the patient noted increased pain and drainage in the left submandibular region. A 2 mm fistula was noted in that area. An incision and drainage was completed with some improvement of patient's symptoms per the patient. Due to continuation of symptoms postoperatively, the patient was taken back to the main operating room where the cadavaric crib was removed. The patient's symptoms again improved. The patient returned to the operating room in October 2006 for implant placement. She was treatment planned for placement of 4 implants (3i Full Osseotite Certain, Biomet Inc, Warsaw, IN) in the

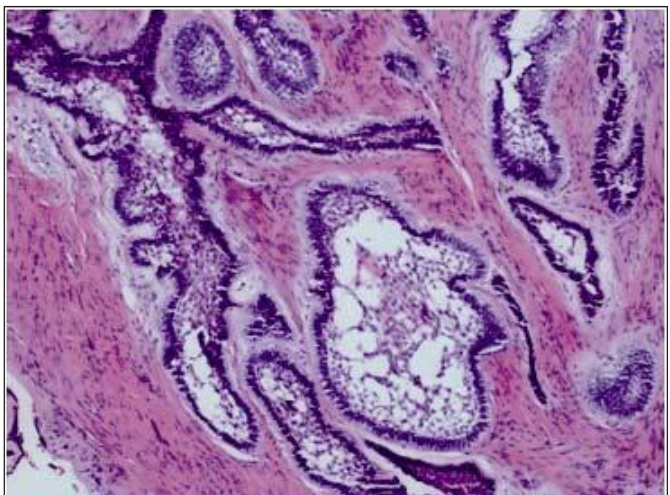


Figure 1 Photomicrograph of the tumor showing islands of odontogenic epithelium (Hemotoxylin and Eosin staining, original magnification  $\times 100$ ).



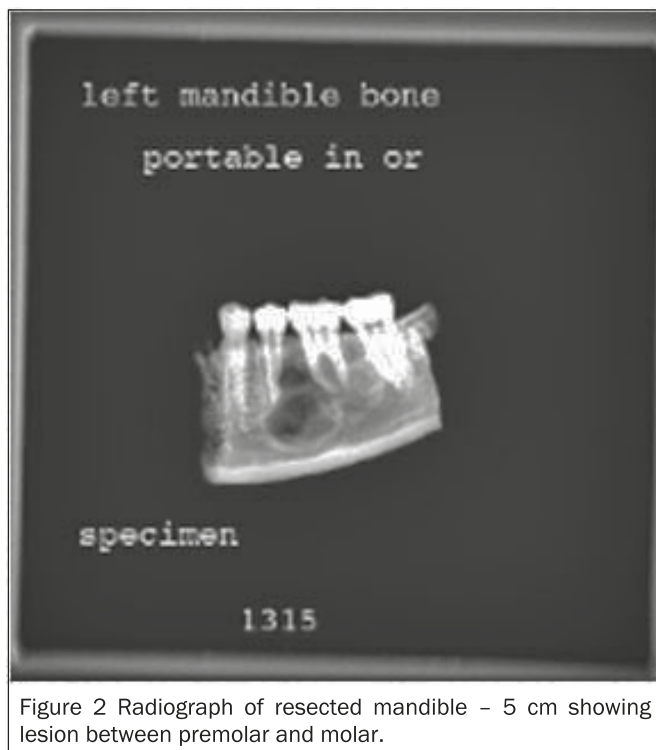

Figure 2 Radiograph of resected mandible – 5 cm showing lesion between premolar and molar.

reconstructed mandible. A surgical guide was fabricated with the prosthodontist and used to ensure proper implant placement and angulation. Intraoperatively, the implant planned for the left first premolar engaged the reconstruction plate and was not placed. The other implants were placed without incident in the molar, premolar, and canine positions. The implant sites were augmented with a cadaveric bone graft (Puros, Zimmer Dental Inc, Carlsbad, CA). The implants osseointegrated for 5 months and were uncovered in June 2007. In July 2007, the prosthodontist restored the patient's dentition with a 5 unit fixed dental prosthesis. In October 2007, the patient returned to the oral and maxillofacial clinic for follow-up and was found to have a draining fistula in the left subman-

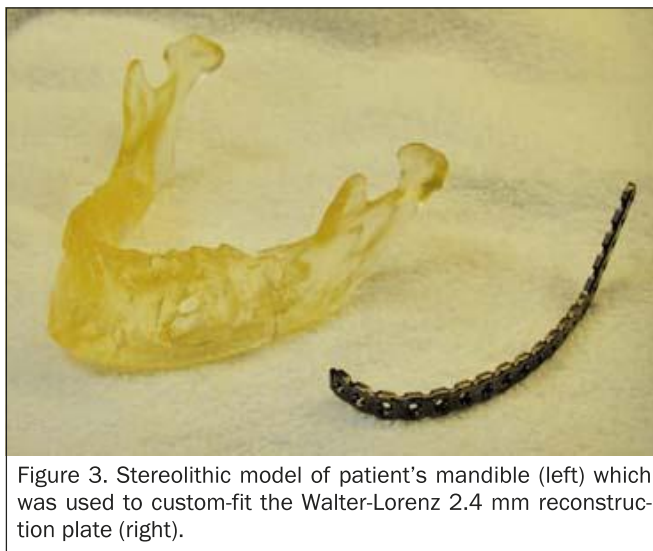

Figure 3. Stereolithic model of patient's mandible (left) which was used to custom-fit the Walter-Lorenz 2.4 mm reconstruction plate (right).

dibular region. Under intravenous sedation, a fistulectomy was performed. The patient noted tremendous relief from the previous symptoms. Follow-up in January 2008 showed the patient with no complaints, functioning well with the dental prosthesis and radiographs showed no recurrence of tumor (Figure 4). The patient was counseled on the need for annual radiographs to ensure no recurrence of the tumor.

## DISCUSSION

The ameloblastoma is an epithelial odontogenic tumor that has an unknown origin.<sup>1-4</sup> It may possibly arise from the enamel organ, the lining of an odontogenic cyst or possibly from the oral mucosal basal cells. The 3 broad subtypes of ameloblastoma are the solid or multicystic, unicystic, and the peripheral. The multicystic or solid group is the most commonly encountered ameloblastoma and is subdivided into 6 histological subtypes: follicular, plexiform, acanthomatous, granular cell, desmoplastic and basal cell types.<sup>1,2</sup> The histopathologic subclassification does not affect treatment. The less common unicystic group is subdivided into the luminal, intraluminal, and mural ameloblastoma.<sup>1</sup> In the mural unicystic ameloblastoma there is microinvasion of the underlying connective tissue with the majority of the lesion being confined to the cystic lumen. The peripheral ameloblastoma is also encountered less frequently than the multicystic or solid variant.<sup>2,5</sup> The peripheral ameloblastoma is typically found in the posterior gingival or the

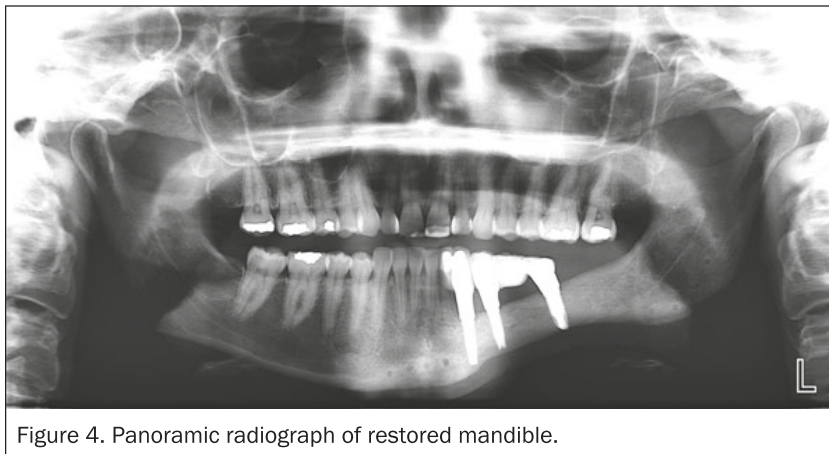

Figure 4. Panoramic radiograph of restored mandible.

## Solid Ameloblastoma, Resection to Reconstruction: A Case Report

alveolar mucosa. The peripheral ameloblastoma is confined to the soft tissue and is the easiest to manage surgically.

The current recommendation for the treatment of the multicystic or solid variant is resection with 1 to 1.5 cm boney margins, and one anatomical boundary.<sup>1</sup> Frozen section are indicated when cortical perforation is present. Research has shown that recurrence is possible, either by incomplete removal of tumor cells, seeding of the cells by rotary instrumentation, or poor treatment planning. One complicating factor with recurrence is it has been found to occur between one and 23 years after surgery.<sup>3,6</sup> Bearing this in mind, long-term, close follow-up is critical for patients that have been treated for ameloblastoma, owing to its slow growth and aggressive nature. The differential diagnosis for a multilocular, radiolucent lesion in the body of the mandible is ameloblastoma, keratocystic odontogenic tumor (parakeratinizing odontogenic keratocyst), odontogenic myxoma or central giant cell lesion.<sup>1,2,7</sup>

### REFERENCES

1. Marx RE, Stern D, eds. *Oral and Maxillofacial Pathology: A Rationale for Diagnosis and Treatment*. Carol Stream, IL: Quintessence Publishing; 2003.
2. Neville BW, Damm DD, Allen CM, Bouquot J. *Oral and Maxillofacial Pathology*. 3rd ed. St Louis, MO: Saunders Elsevier; 2009.
3. Carlson ER, Marx RE. The ameloblastoma: Primary, curative surgical management. *J Oral Maxillofac Surg*. 2006;64:484-494.
4. Ferretti C, Polakow R, Coleman H. Recurrent ameloblastoma: report of 2 cases. *J Oral Maxillofac Surg*. 2000;58:800-804.
5. El-Hakim IE, El-Khashab MM. Peripheral and mural ameloblastoma in the mandibular canine region of a 13-year-old boy. *J Oral Maxillofac Surg*. 2000;58:1150-1154.
6. Arotiba GT, Ladeinde AL, Arotiba JT, Ajike SO, Ugboko VI, Ajayi OF. Ameloblastoma in Nigerian children and adolescents: a review of 79 cases. *J Oral Maxillofac Surg*. 2005;63:747-751.
7. Lilly GE. Differential diagnosis of lesions of the jawbones. *J Oral Sur*. 1970;28:65-69.

### AUTHORS

MAJ Ryhn is the Assistant Program Director, Oral and Maxillofacial Surgery Residency, Womack Army Medical Center, Fort Bragg, North Carolina.

COL Almony is the Program Director and Chairman, Oral and Maxillofacial Surgery Residency, Womack Army Medical Center, Fort Bragg, North Carolina.

COL Manganaro is the Chief Oral Pathologist, Womack Army Medical Center, Fort Bragg, North Carolina.



Insignia of the Womack Army Medical Center, Fort Bragg, North Carolina.

## SUBMISSION OF MANUSCRIPTS TO THE ARMY MEDICAL DEPARTMENT JOURNAL

The *United States Army Medical Department Journal* is published quarterly to expand knowledge of domestic and international military medical issues and technological advances; promote collaborative partnerships among the Services, components, Corps, and specialties; convey clinical and health service support information; and provide a professional, high quality, peer reviewed print medium to encourage dialogue concerning health care issues and initiatives.

### REVIEW POLICY

All manuscripts will be reviewed by members of the *AMEDD Journal's* Editorial Review Board or forwarded to appropriate subject matter experts for further review and assessment.

### IDENTIFICATION OF POTENTIAL CONFLICTS OF INTEREST

1. **Related to individual authors' commitments:** Each author is responsible for the full disclosure of all financial and personal relationships that might bias the work or information presented in the manuscript. To prevent ambiguity, authors must state explicitly whether potential conflicts do or do not exist. Authors should do so in the manuscript on a conflict-of-interest notification section on the title page, providing additional detail, if necessary, in a cover letter that accompanies the manuscript.
2. **Assistance:** Authors should identify Individuals who provide writing or other assistance and disclose the funding source for this assistance, if any.
3. **Investigators:** Potential conflicts must be disclosed to study participants. Authors must clearly state whether they have done so in the manuscript.
4. **Related to project support:** Authors should describe the role of the study sponsor, if any, in study design; collection, analysis, and interpretation of data; writing the report; and the decision to submit the report for publication. If the supporting source had no such involvement, the authors should so state.

### PROTECTION OF HUMAN SUBJECTS AND ANIMALS IN RESEARCH

When reporting experiments on human subjects, authors must indicate whether the procedures followed were in accordance with the ethical standards of the responsible committee on human experimentation (institutional and national) and with the Helsinki Declaration of 1975, as revised in 2000. If doubt exists whether the research was conducted in accordance with the Helsinki Declaration, the authors must explain the rationale for their approach and demonstrate that the institutional review body explicitly approved the doubtful aspects of the study. When reporting experiments on animals, authors should indicate whether the institutional and national guide for the care and use of laboratory animals was followed.

### GUIDELINES FOR MANUSCRIPT SUBMISSIONS

1. Manuscripts should be submitted in digital format, preferably an MS Word document, either as an email attachment (with illustrations, etc), or by mail on CD or floppy disk accompanied by one printed copy of the manuscript. Ideally, a manuscript should be no longer than 24 double-spaced pages. However, exceptions will always be considered on a case-by-case basis. In general, 4 double-spaced MS Word pages produce a single page of 2 column text in the *AMEDD Journal* production format.
2. The *American Medical Association Manual of Style* governs formatting in the preparation of text and references. All articles should conform to those guidelines as closely as possible. Abbreviations/acronyms should be limited as much as possible. Inclusion of a list of article acronyms and abbreviations can be very helpful in the review process and is strongly encouraged.
3. A complete list of references cited in the article must be provided with the manuscript. The following is a synopsis of the American Medical Association reference format:
  - Reference citations of published articles must include the authors' surnames and initials, article title, publication title, year of publication, volume, and page numbers.
  - Reference citations of books must include the authors' surnames and initials, book title, volume and/or edition if appropriate, place of publication, publisher, year of copyright, and specific page numbers if cited.
  - Reference citations for presentations, unpublished papers, conferences, symposia, etc, must include as much identifying information as possible (location, dates, presenters, sponsors, titles).
4. Either color or black and white photographs may be submitted with the manuscript. Color produces the best print reproduction quality, but please avoid excessive use of multiple colors and shading. Digital graphic formats (JPG, GIF, BMP) and MS Word photo files are preferred. Prints of photographs are acceptable. Please do not send photos embedded in PowerPoint. Images submitted on slides, negatives, or copies of X-ray film will not be published. For clarity, please mark the top of each photographic print on the back. Tape captions to the back of photos or submit them on a separate sheet. Ensure captions and photos are indexed to each other. Clearly indicate the desired position of each photo within the manuscript.
5. The authors' names, ranks or academic/certification credentials, titles or positions, current unit of assignment, and contact information must be included on the title page of the manuscript.
6. Submit manuscripts to:

EDITOR, AMEDD JOURNAL  
ATTN MCCS HT  
2419 HOOD ST STE C  
FORT SAM HOUSTON, TX 78234-7584

DSN 471-6301  
Comm 210-221-6301  
Email: [amedd.journal@amedd.army.mil](mailto:amedd.journal@amedd.army.mil)